

Successful allogeneic hematopoietic stem cell transplantation in patients with VEXAS syndrome: a 2-center experience

Ava Diarra,¹ Nicolas Duployez,² Elise Fournier,² Claude Preudhomme,² Valérie Coiteux,³ Leonardo Magro,⁴ Bruno Quesnel,² Maël Heiblig,³ Pierre Sujobert,³ Fiorenza Barraco,³ Marie Balsat,³ Quentin Scanvion,¹ Eric Hachulla,¹ David Launay,¹ Ibrahim Yakoub-Agha,⁴ and Louis Terriou,¹ on behalf of the French VEXAS study group

¹Département de médecine interne et d'immunologie clinique, Université de Lille, Inserm, Centre Hospitalier Universitaire (CHU) Lille, Service de Médecine Interne et Immunologie Clinique, Centre de référence des maladies autoimmunes systémiques rares du Nord et Nord-Ouest de France (CeRAINO), U1286, Institute for Translational Research in Inflammation (INFINITE), Lille, France; ²Département d'Hématologie, Université de Lille, Centre national de la recherche scientifique, Inserm, CHU Lille, Unité Mixte de Recherche (UMR) 9020 – UMR-S 1277, Cancer Heterogeneity, Plasticity and Resistance to Therapies (Canther), Lille, France; ³Department of Hematology, Lyon-Sud Hospital, Hospices Civils de Lyon, Pierre Bénite, France; and ⁴Département d'Hématologie, Université de Lille, Inserm, CHU Lille, U1286, Infinite, Lille, France

Key Points

- Allogeneic hematopoietic stem cell transplantation is a curative option in patients with VEXAS syndrome and severe manifestations.

The recently described vacuoles, E1 enzyme, X-linked, autoinflammatory, somatic (VEXAS) syndrome is caused by somatic mutations in *UBA1*. Patients with VEXAS syndrome display late-onset autoinflammatory symptoms, usually refractory to treatment, and hematologic abnormalities. The identification of an easily-accessible specific marker (*UBA1* mutations) is of particular interest as it allows the convergence of various inflammatory and hematological symptoms in a unique clinico-biological entity and gives the opportunity to design specific treatment strategies. Here we retrospectively identified 6 patients with VEXAS syndrome who underwent allogeneic hematopoietic stem cell transplantation (ASCT). To date, no treatment guidelines have been validated. In 4 patients, ASCT was guided by life-threatening autoinflammatory symptoms that were refractory to multiple therapies. Three patients are in durable complete remission 32, 38, and 37 months after ASCT. Two others are in complete remission response after 3 and 5 months. One unfortunately died post-ASCT. This report suggests that ASCT could be a curative option in patients with VEXAS syndrome and severe manifestations. Considering the complications and side effects of the procedure as well as the existence of other potential treatment, clinical trials are needed to define the subgroup of patients who will benefit from this strategy and its place in the therapeutic arsenal against VEXAS syndrome.

Introduction

Beck et al recently identified a specific somatic molecular alteration targeting the *UBA1* gene, located on the X chromosome, defining the vacuoles, E1 enzyme, X-linked, autoinflammatory, somatic (VEXAS) syndrome.¹ Patients with VEXAS syndrome are men (rarely women with acquired monosomy X)² with a late-onset, treatment-refractory autoinflammatory syndrome and hematologic abnormalities, especially macrocytic anemia and characteristic vacuoles in myeloid precursors from bone marrow (BM). The *UBA1* gene encodes the E1 ubiquitin-activating protein, which is critical for the first step of ubiquitylation.³ The vast majority of *UBA1* mutations involve the methionine 41 in exon 3 (which initiates the translation of the canonical cytoplasmic isoform UBA1b) and lead to the production of a shorter cytoplasmic catalytically-deficient isoform (UBA1c, initiated from methionine 67). This results in decreased

Submitted 15 March 2021; accepted 19 October 2021; prepublished online on *Blood Advances* First Edition 29 October 2021; final version published online 4 February 2022. DOI 10.1182/bloodadvances.2021004749.

Requests for data sharing may be submitted to Louis Terriou (louis.terriou@chru-lille.fr).

The full-text version of this article contains a data supplement.

© 2022 by The American Society of Hematology. Licensed under Creative Commons Attribution-NonCommercial-NoDerivatives 4.0 International (CC BY-NC-ND 4.0), permitting only noncommercial, nonderivative use with attribution. All other rights reserved.

ubiquitylation and activation of innate immune pathways, elevated serum cytokine levels, and severe inflammatory effects.¹ Other mutations affecting the acceptor-splice site of exon 3 or the serine 56 have also been rarely described.^{4,5} The identification of VEXAS syndrome is of particular interest for clinical practice as it provides a strong diagnostic marker, giving the opportunity to design specific treatment strategies in patients whose inflammatory symptoms are usually refractory to most therapies.⁴ Here, we retrospectively diagnosed VEXAS syndrome in 6 patients who underwent allogeneic hematopoietic stem cell transplantation (ASCT) for the treatment of severe inflammatory symptoms ($n = 4$) or myelodysplastic syndromes (MDS, $n = 2$). Patients' characteristics, BM examination, and *UBA1* screening are summarized in Table 1, Figure 1, and supplemental Appendix.

Case description

The first patient (#UPN1, briefly depicted in ref⁶) was a 43-year-old man diagnosed with polyarteritis nodosa and Sweet's syndrome. Clinical manifestations included fever, orchitis, myalgia, erythema nodosum, and chemosis. Blood cell count revealed persistent macrocytic anemia, and BM examination revealed a MDS with multilineage dysplasia and multiple vacuoles in myeloid precursor cells. The patient received multiple therapies without remission of the vasculitis symptoms. ASCT was considered 2.7 years after initial diagnosis due to uncontrolled autoinflammatory manifestations. Following reduced-intensity conditioning, he underwent ASCT from an HLA-matched unrelated donor. Despite chronic GVHD, the patient remains in complete remission of both hematological and inflammatory diseases 32 months after ASCT. Retrospective sequencing (supplemental Methods) demonstrated the p.Met41Val mutation in *UBA1*, leading to the diagnosis of VEXAS syndrome.

The second patient (#UPN2) was a 56-year-old man who presented with inflammatory symptoms including fever, arthritis, and Sweet's syndrome with neutrophilic dermatosis. After 1 year, he experienced diffuse purpura related to immune thrombocytopenia, bilateral episcleritis, and splenomegaly. Splenectomy was performed for refractory immune thrombocytopenia. Analysis of spleen histopathology revealed signs of extramedullary hematopoiesis. BM trephine biopsy showed hyperplasia of all lineages, megakaryocytic dysplasia, vacuoles in myeloid precursor cells, and grade II fibrosis, leading to the diagnosis of myelofibrosis. The patient received multiple therapies without remission of the vasculitis symptoms. ASCT was then performed, more than 3 years after initial diagnosis, from a related donor after reduced-intensity conditioning. He developed extensive chronic cutaneous GVHD treated by cyclosporine, corticosteroids, and ruxolitinib. He is still in remission from hematological and autoinflammatory diseases 67 months after ASCT. Retrospective sequencing showed the *UBA1* p.Met41Val mutation.

The third patient (#UPN3) was a 63-year-old man with a chronic inflammatory syndrome with fever, arthralgia, and myalgia who was referred to our department for chondritis, anterior uveitis, Sweet's syndrome, and mild cytopenia. BM examination led to the diagnosis of MDS with major dysgranulopoiesis and vacuolization of erythroid and granulocyte precursor cells. Multiple therapies, including 5-azacytidine, did not result in clinical improvement of the Sweet's syndrome. ASCT was then performed with peripheral blood stem cells from an HLA-matched unrelated donor after reduced-intensity conditioning. He subsequently developed BK virus-related hemorrhagic

cystitis, cytomegalovirus replication, and acute cutaneous GVHD treated with corticosteroids. The patient is still in complete remission of the hematologic disease and Sweet's syndrome 38 months after ASCT. Retrospective Sanger sequencing revealed the *UBA1* p.Met41Leu mutation.

The fourth patient (#UPN4) was a 48-year-old man diagnosed with deep venous thrombosis, asthenia, fever, chondritis, Sweet's syndrome, macrocytic anemia, polyadenopathy, and pulmonary infiltrate. BM examination showed dysmyelopoiesis and vacuolization of erythroid and granulocytic precursor cells. Several therapies were ineffective. The diagnosis of VEXAS syndrome with the *UBA1* p.Met41Thr mutation was made (prior to ASCT). ASCT was performed 2 years after the first symptoms with peripheral blood stem cells from an HLA-matched unrelated donor after myeloablative conditioning.

In addition to the 4 previously described patients who underwent ASCT because of severe refractory inflammatory symptoms, we identified 2 other patients with a retrospective diagnosis of VEXAS syndrome for whom ASCT was performed because of hematological diseases. The fifth patient (#UPN5) was a 56-year-old man concomitantly diagnosed with multilineage dysplasia, mouth and genital ulcers-inflamed cartilage syndrome, and large vessel vasculitis. The patient received multiple therapies including 5-azacytidine and ruxolitinib with insufficient response. ASCT was finally performed with a related donor after reduced intensity conditioning allowing complete response (5 months of follow-up). The sixth patient (#UPN6) was a 50-year-old man who had atypical vasculitis associated with sinusitis, orchitis, arthritis, and concomitant pancytopenia that led to the diagnosis of MDS with excess blasts type 1. Treatment with 5-azacytidine was initially successful, but relapse of the autoinflammatory symptoms occurred after 30 months, and the patient was treated with glucocorticoids. He finally underwent ASCT due to reoccurrence and worsening of cytopenia with peripheral blood stem cells from an HLA-matched unrelated donor 5 years after the first symptoms but died of infectious severe hypoxic pneumonia 4 months after ASCT.

Methods

After the Beck et al.¹ paper describing VEXAS, French centres of the Medecine INterne, HEMato et ONco (MINHEMON) group analysed *UBA1* mutation in samples from their patients with similar unexplained symptoms, while several Groupe Francophone des Myélodysplasies (GFM) centres analysed systematically this mutation in MDS with concomitant autoimmune/autoinflammatory disease, yielding a total of 116 patients (between December 2020 and May 2021). In all, 6 of them underwent ASCT. One of them has previously been reported.⁶ The present study was conducted in compliance with the Good Clinical Practices protocol and Declaration of Helsinki principles. Data collection Collected data at baseline and during the follow-up included patient demographics, MDS characteristics (WHO classification, karyotype), clinical and laboratory features of VEXAS, and additional somatic mutations by next-generation sequencing analysis. Statistical analysis Data were expressed as median (range) for quantitative variables and number (percentage) for categorical variables.

Results and discussion

Because of its recent description, there are no guidelines for the treatment of VEXAS syndrome. We present here 6 patients

Table 1. Characteristics of UBA1-mutated patients

Patient ID	#UPN1	#UPN2	#UPN3	#UPN4	#UPN5	#UPN6
Sex	M	M	M	M	M	M
Age at onset (years)	43	56	63	48	56	50
UBA1 mutation	c.121A>G, p.Met41Val (VAF 73%)	c.121A>G, p.Met41Val (VAF 88%)	c.121A>C, p.Met41Leu (VAF 43%)	c.122T>C, p.Met41Thr (VAF 67%)	c.121A>G, p.Met41Val (VAF: NA) [‡]	c.121A>G, p.Met41Val (VAF: NA) [‡]
Key clinical features						
Neutrophilic dermatosis	+	+	+	+	-	-
Polyarthritis nodosa	+	-	+	-	-	-
Chondritis	-	-	+	+	+	+
Pulmonary involvement	-	-	-	+	+	-
Deep vein thrombosis	-	-	-	+	-	-
Laboratory findings*						
Hemoglobin concentration (g/l)	96	92	102	78	110	131
Mean corpuscular volume (fl)	102	98	104	105	91.2	113.7
Platelet count ($\times 10^9/l$)	225	67	157	341	268	153
Neutrophil count ($10^9/l$)	2.1	11.8	4.0	4.6	5.5	1.2
Bone marrow vacuoles	+	+	+	+	NA	NA
Additional genetic aberrations (HTS and cytogenetics)	Normal karyotype No additional mutation	Normal karyotype DNMT3A p.Trp795Ser (VAF 43%) [†] RUNX1 p.Gly165fs (VAF 2%)	Normal karyotype CBL c.1228-2A>G (VAF 9%) KRAS p.Gly12A>G (VAF 2%) NRAS p.Tyr64Asp (VAF 1%) TET2 p.Leu1622Ter (VAF 49%) TET2 p.Lys1317Ter (VAF 2%) ZRSR2 p.Arg27fs (VAF 4%)	Normal karyotype No additional mutation	Normal karyotype TET2 p.Thr1554fs (VAF 3%)	Trisomy 8 No additional mutation
Hematologic diseases						
Myelodysplastic syndrome	+	-	+	+	+	+
Myelofibrosis	-	+	-	-	-	+
Number of prior lines of therapy	6	8	7	6	5	4
Reaction at anakinra injection	GC, anakinra, dapsone, canakinumab, AZA, HCQ	GC, CP, IVIG, rituximab, danazol, anakinra, dapsone, canakinumab	GC, MTX, anakinra, canakinumab, tocilizumab, IVIG, 5-AZA	GC, dapsone, colchicine, anakinra, canakinumab, siltuximab	GC, tocilizumab, adalimumab, 5-AZA, ruxolitinib	GC, MMF, colchicine, 5-AZA
Allogeneic HSCT						
Age at time of HSCT	46	59	65	50	58	55
Conditioning	fludarabine, busulfan, ATG	fludarabine, busulfan	fludarabine, busulfan	fludarabine, busulfan, ATG	fludarabine, busulfan, thotepa	busulfan, CPA, ATG

5-AZA, 5-azacytidine; ATG, antithymocyte globulin; AZA, azathioprine; CP, cyclophosphamide; CR, complete remission; CSA, cyclosporine; GC, glucocorticoid; GVHD, graft-versus-host disease; HCQ, hydroxychloroquine; HSCT, hematopoietic stem cell transplantation; IVIG, intravenous immunoglobulin; M, male; MMF, mycophenolate mofetil; MTX, methotrexate; NA, not applicable; VAF, variant allele frequency.

*At time of first bone marrow examination.

[†]The somatic state of the DNMT3A mutation was confirmed by sequencing on a skin biopsy.

[‡]Sanger sequencing only.

Table 1. (continued)

Patient ID	#UPN1	#UPN2	#UPN3	#UPN4	#UPN5	#UPN6
Donor	Unrelated donor Pheno-identical 10/10	Related donor	Unrelated donor Pheno-identical 10/10	Unrelated donor Pheno-identical 10/10	Related donor	Unrelated donor Pheno-identical 10/10
Graft origin	Peripheral blood	Bone marrow	Peripheral blood	Peripheral blood	Peripheral blood	Peripheral blood
GVH prophylaxis	CSA, MMF	CSA, MTX	CSA, MMF, CP	CSA, MTX	CSA, MMF, CP	CSA, MTX
Infectious complications	None	None	E. coli bacteremia, BK virus-related hemorrhagic cystitis, CMV replication	Bacterial catheter related infection	Bacterial catheter related infection	Bacterial catheter related infection, fusariosis
Immune complications	Chronic cutaneous GVHD, hepatic GHVD	Chronic cutaneous GVHD	Acute cutaneous GVHD grade I	None	Acute gastrointestinal GVHD grade II Cutaneous GVHD grade I	Acute gastrointestinal GVHD grade III
Clinical response	CR	CR	CR	CR	CR	Death prior evaluation
Follow-up (months)	32	67	38	3	5	4
Alive at end of follow-up	+	+	+	+	+	-

5-AZA, 5-azacytidine; ATG, antithymocyte globulin; AZA, azathioprine; CP, cyclophosphamide; CR, complete remission; CSA, cyclosporine; GC, glucocorticoid; GVHD, graft-versus-host disease; HCC, hydroxychloroquine; HSCT, hematopoietic stem cell transplantation; IVIG, intravenous immunoglobulin; M, male; MMF, mycophenolate mofetil; MTX, methotrexate; NA, not applicable; VAF, variant allele frequency.

*At time of first bone marrow examination.

†The somatic state of the DNMT3A mutation was confirmed by sequencing on a skin biopsy.

#Sanger sequencing only.

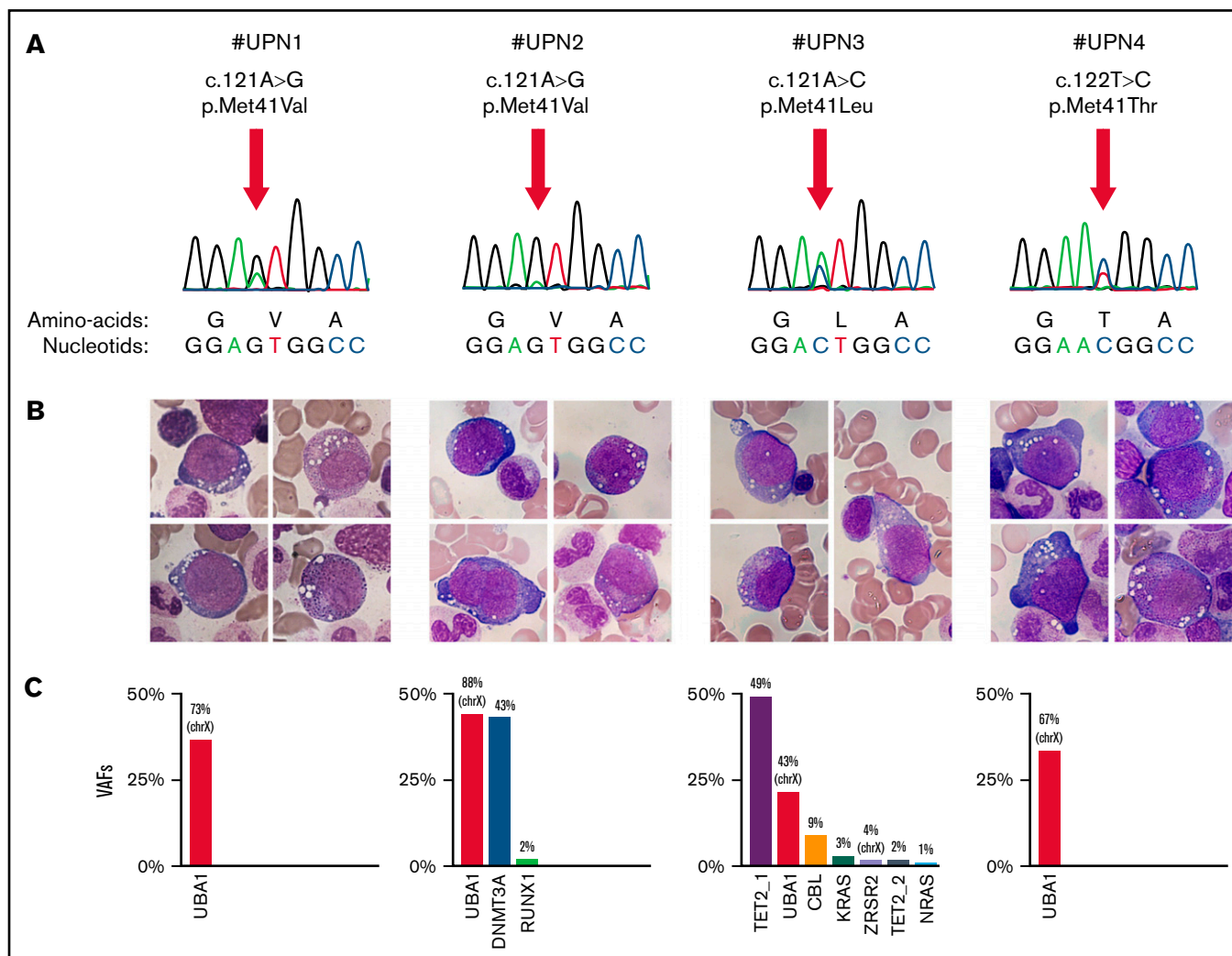


Figure 1. Molecular and cytomorphic diagnosis in patients with VEXAS syndrome. (A) The Sanger sequencing chromatograms for the *UBA1* (NM_0033334) mutations: c.121 A>G, p.Met41Val (n = 2); c.121 A>C, p.Met41Leu (n = 1); c.122 T>C, p.Met41Thr (n = 1). (B) Characteristic vacuoles in erythroid and granulocytic precursor cells in BM from all *UBA1*-mutated patients (May-Grünwald-Giemsa stain). (C) Variant allele frequencies (VAFs) for putative somatic variants identified by high-throughput sequencing. Because of their location on the X chromosome, VAFs for *UBA1* (black boxes) and *ZRSR2* are divided by 2 to allow their representation on the same graph. UPN, unit patient number.

with VEXAS syndrome who underwent ASCT after multiple therapies. Three patients with sufficient follow-up were still in complete remission 32, 38, and 67 months after ASCT, and 1 died of infectious complications. The 2 remaining patients were still alive with a shorter follow-up (3 and 5 months, respectively). In 4 patients, ASCT was guided by life-threatening autoinflammatory symptoms that were refractory to multiple biologics/anti-rheumatic drugs and immunosuppressants. This condition represents a rare indication for ASCT in our practice (no other case identified in our institution). However, because the selection of our patients was retrospectively made according to the severity of the disease and indication for ASCT, it cannot be excluded that some patients with VEXAS syndrome with moderate symptoms may have a favorable outcome with other therapies. Notably, Bourbon et al recently reported the retrospective study of patients with VEXAS syndrome in which they identified

1 patient with an indolent course without specific treatment. Interestingly, the authors observed a potential effectiveness of JAK inhibitors and hypomethylating agents in some patients.⁴ Overall, further studies are needed to identify predictive factors of response. Some variability may be related to additional somatic aberrations. For example, the study of variant allele frequencies in #UPN2 and #UPN3 strongly suggests that the *UBA1* mutation was concomitant to mutations in *DNMT3A* or *TET2*. Another patient reported by Hage-Sleiman et al demonstrated under therapy the selection of an *UBA1*-mutated clone, outcompeting a *CALR*-mutated clone, both developing after a preexisting *DNMT3A* founding clone.⁷

In conclusion, the present report suggests that ASCT could be a curative option in patients with VEXAS syndrome and severe manifestations. Considering the complications and side effects of the procedure (as demonstrated by our last case) as well as the

existence of other therapeutic options,⁴ clinical trials are required to define the subgroup of patients who will benefit from this strategy and its place in the therapeutic arsenal against VEXAS syndrome.

Acknowledgment

The authors would like to thank Christophe Roumier for handling, conditioning, and storing patient samples (Lille Hospital Tumor Bank, certification NF 96900-2014/65453-1).

Authorship

Contribution: A.D. and L.T. conceived the study; N.D., E.F., C.P., and P.S. performed cytomorphological examinations and molecular analyses; A.D., E.H., I.Y.-A., V.C., L.M., B.Q., Q.S., D.L., M.H., F.B., M.B., and L.T. managed the patients and provided samples and clinical data; A.D., N.D., and L.T. wrote the manuscript, which was approved by all the authors.

Conflict-of-interest disclosure: The authors declare no competing financial interests.

References

1. Beck DB, Ferrada MA, Sikora KA, et al. Somatic Mutations in *UBA1* and Severe Adult-Onset Autoinflammatory Disease. *N Engl J Med*. 2020; 383(27):2628-2638.
2. Barba T, Jamilloux Y, Durel C-A, et al. VEXAS syndrome in a woman. *Rheumatology (Oxford)*. 2021; 60(11):e402-e403.
3. Lee TV, Ding T, Chen Z, et al. The E1 ubiquitin-activating enzyme Uba1 in *Drosophila* controls apoptosis autonomously and tissue growth non-autonomously. *Development*. 2008;135(1):43-52.
4. Bourbon E, Heiblig M, Gerfaud Valentin M, et al. Therapeutic options in VEXAS syndrome: insights from a retrospective series. *Blood*. 2021; 137(26):3682-3684.
5. Poulter JA, Collins JC, Cargo C, et al. Novel somatic mutations in *UBA1* as a cause of VEXAS syndrome. *Blood*. 2021;137(26):3676-3681.
6. Diarra A, Duployez N, Terriou L. Mutant *UBA1* and Severe Adult-Onset Autoinflammatory Disease. *N Engl J Med*. 2021;384(22):2163-2164.
7. Hage-Sleiman M, Lalevée S, Guermouche H, et al. Dominance of an *UBA1* mutant clone over a *CALR* mutant clone: from essential thrombocytemia to VEXAS [published online ahead of print 29 July 2021]. *Haematologica*.

A complete list of the members of the French VEXAS study group appears in "Appendix."

ORCID profiles: A.D., 0000-0001-5468-0695; N.D., 0000-0002-3927-1022; C.P., 0000-0002-1267-9546; Q.S., 0000-0001-5865-1525; D.L., 0000-0003-1840-1817; I.Y.-A., 0000-0003-4524-8782.

Correspondence: Louis Terriou, CHU Lille, Service de Médecine Interne, Hôpital Claude Huriez, Rue Michel Polonovski, 59037 LILLE CEDEX, France; e-mail: louis.terriou@chru-lille.fr.

Appendix

The members of the French VEXAS study group are Sophie Georgin Lavielle, Isabelle Melki, Thibault Comont, Pierre Fenaux, Lionel Ades, Olivier Fain, Alexandra Audemard, Mikael Ebbo, Achille Aouba, Philippe Guilpain, Estibaliz Lazaro, Olivier Kosmider, Rim Bourguiba, Benjamin T. Errier, Raphael Borie, Alexis Mat Hian, Laurent Arnaud, Francois Chasset, Jean-David Bouaziz, and Jeremie Dion.