

# CPX-351 induces remission in newly diagnosed pediatric secondary myeloid malignancies

Yixin Hu,<sup>1,\*</sup> Kenneth J. Caldwell,<sup>2,\*</sup> Mihaela Onciu,<sup>3</sup> Sara M. Federico,<sup>2</sup> Marta Salek,<sup>2</sup> Sara Lewis,<sup>1</sup> Shaohua Lei,<sup>4</sup> Jinghui Zhang,<sup>4</sup> Kim E. Nichols,<sup>2</sup> Clifford M. Takemoto,<sup>1</sup> Brandon M. Triplett,<sup>5</sup> Jason E. Farrar,<sup>6</sup> Jeffrey E. Rubnitz,<sup>2</sup> Raul C. Ribeiro,<sup>2</sup> and Marcin W. Wlodarski<sup>1</sup>

<sup>1</sup>Department of Hematology, <sup>2</sup>Department of Oncology, <sup>3</sup>Department of Pathology, <sup>4</sup>Department of Computational Biology, and <sup>5</sup>Department of Bone Marrow Transplantation and Cellular Therapy, St. Jude Children's Research Hospital, Memphis, TN; and <sup>6</sup>Arkansas Children's Research Institute and Department of Pediatrics, University of Arkansas for Medical Sciences, Little Rock, AR

## Key Points

- CPX-351 treatment is well tolerated and results in morphologic remission in newly diagnosed pediatric secondary myeloid malignancies.
- Favorable outcomes are achieved despite the presence of high-risk genetic lesions and previous therapies.

Secondary myelodysplastic syndromes and acute myeloid leukemia (sMDS/AML) are rare in children and adolescents and have a dismal prognosis. The mainstay therapy is hematopoietic cell transplantation (HCT), but there has been no innovation in cytoreductive regimens. CP X-351, a fixed 5:1 molar ratio of liposomal cytarabine to daunorubicin, has shown favorable safety and efficacy in elderly individuals with secondary AML and children with relapsed de novo AML. We report the outcomes of 7 young patients (6 with newly diagnosed sMDS/AML and 1 with primary MDS/AML) uniformly treated with CP X-351. Five patients had previously received chemotherapy for osteosarcoma, Ewing sarcoma, neuroblastoma, or T-cell acute lymphoblastic leukemia; 1 had predisposing genomic instability disorder (Cornelia de Lange syndrome) and 1 had MDS-related AML and multiorgan failure. The median age at diagnosis of myeloid malignancy was 17 years (range, 13-23 years). Patients received 1 to 3 cycles of CP X-351 (cytarabine 100 mg/m<sup>2</sup> plus daunorubicin 44 mg/m<sup>2</sup>) on days 1, 3, and 5, resulting in complete morphologic remission without overt toxicity or treatment-related mortality. This approach allowed for adding an FLT3 inhibitor as individualized therapy in 1 patient. Six patients were alive and leukemia-free at 0.5 to 3.3 years after HCT. One patient died as a result of disease progression before HCT. To summarize, CP X-351 is an effective and well-tolerated regimen for cytoreduction in pediatric sMDS/AML that warrants prospective studies.

## Introduction

Secondary myeloid malignancies in children and adolescents are clinically and biologically related disorders associated with previous oncologic therapies or with antecedent hematologic disorders, including inherited bone marrow (BM) failure syndromes.<sup>1-3</sup> The disease continuum runs from secondary myelodysplastic syndromes (sMDS) to secondary acute myeloid leukemia (sAML) as defined by diagnostic blast count. Patients with sMDS/AML have inferior outcomes when compared with primary MDS/AML, and hematopoietic cell

Submitted September 13, 2021; accepted October 14, 2021; prepublished online on *Blood Advances* First Edition 28 October 2021; final version published online 18 January 2022. DOI 10.1182/bloodadvances.2021006139.

\*Y.H. and K.J.C. contributed equally to this work.

Requests for data sharing may be submitted to Marcin W. Wlodarski (marcin.wlodarski@stjude.org).

The current affiliation for Y.H. is Department of Hematology and Oncology, Children's Hospital of Soochow University, China.

The full-text version of this article contains a data supplement.

© 2022 by The American Society of Hematology. Licensed under Creative Commons Attribution-NonCommercial-NoDerivatives 4.0 International (CC BY-NC-ND 4.0), permitting only noncommercial, nonderivative use with attribution. All other rights reserved.

**Table 1. Clinical characteristics, therapy, and outcome**

Characteristic	Patient 1 Male	Patient 2 Male	Patient 3 Male	Patient 4 Male	Patient 5 Female	Patient 6 Male	Patient 7 Female
Previous diagnosis at age	Localized osteosarcoma, 10 y 9 mo	Localized osteosarcoma, 13 y 11 mo	Localized stage V Ewing sarcoma, 18 y 8 mo	Stage IV, high-risk neuroblastoma, 1 y 9 mo	T-ALL, 14 y 1 mo	MDS-EB with underlying CDL syndrome, 17 y 2 mo	None
Myeloid malignancy	AML	AML	AML	AML	AML	MDS/AML	AML with MDS-related changes
Blast count in BM, %	60	47	56	71	57	24	32
Age at diagnosis	13 y 6 mo	19 y 1 mo	23 y 10 mo	16 y 9 mo	18 y 8 mo	17 y 4 mo	13 y 3 mo
Cytogenetics	Del5q, del7q, add3q, t(2;3)(p21;q26.2)	Del11p, t(5;5)(p12;p15.33), inv3(p24.3;q26.2)	Multiple gains and losses	Complex	Monosomy 7	Normal	Complex with monosomy 7
Somatic mutations	KRAS, IKZF1, NFI, CSNK1A1 deletion	WT1	TP53, NFI, PDGFRA; deletions: ETV6, CSNK1A1; amplifications: KMT2A, ATM		RUNX1, NFI	NPM1, CEBPA, NRAS, FLT3-ITD	Deletions: TP53, RUNX1, ZBTB7A
<b>Treatment</b>							
CPX-351	2 cycles	3 cycles	2 cycles	1 cycle	2 cycles	1 cycle	1 cycle
Venetoclax	–	–	–	–	–	–	1 cycle
Venetoclax and cytarabine	1 cycle	–	–	–	–	–	–
Venetoclax and decitabine	–	–	–	–	–	–	1 cycle
Decitabine	1 cycle	1 cycle (pre-CPX351)	1 cycle	–	–	–	–
Azacytidine	–	–	–	–	Once per month after HCT	–	–
FLAG	–	–	1 cycle	–	–	–	–
Gilteritinib	–	–	–	–	–	Before and after HCT	–
Allogeneic HCT	Haplo-father (first), haplo-mother (second)	Haplo-brother	–	Haplo-sister	Haplo-uncle	MUD	Haplo-grandmother
No. of surgeries	–	2	–	–	–	–	–
Status at last follow-up	Alive, 18.5 mo after HCT	Alive, 39.1 mo after HCT	Deceased 4 mo after diagnosis (disease progress and infection)	Alive, 6.2 mo after HCT	Alive, 34.1 mo after HCT	Alive, 6.3 mo after HCT	Alive, 7.5 mo after HCT

Details on cytogenetics and molecular findings are provided in supplemental Table 2. Details on marrow response are depicted in Figure 2.

FLAG, fludarabine, cytarabine, and granulocyte colony-stimulating factor regimen; haplo, haploidentical; MDS-EB, MDS with excess blasts; MUD, matched unrelated donor; T-ALL, T-cell acute lymphoblastic leukemia.

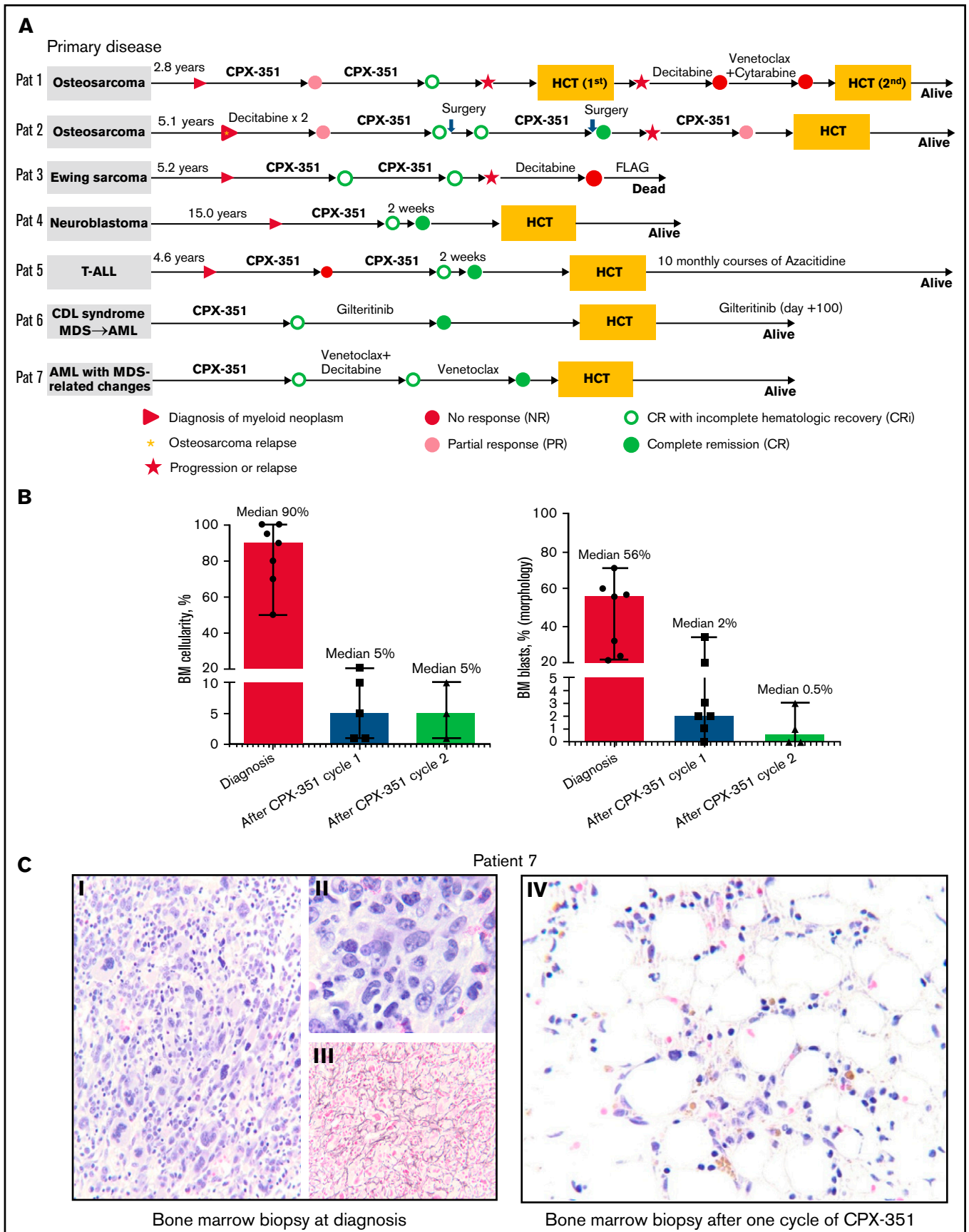


Figure 1.

transplantation (HCT) remains the only curative option.<sup>4-6</sup> However, treatment-related mortality is a major concern in this vulnerable patient population.<sup>3</sup> Pediatric therapy-related sMDS has poor outcomes, and chemotherapy alone does not cure the disease; in a historical study, the estimated overall survival (OS) of 41 children with treatment-related sMDS was about 40%.<sup>7</sup> Despite advances in HCT, outcomes remain poor, as exemplified by a recent analysis showing 5-year OS of ~44%.<sup>8</sup> Intensive AML chemotherapy before HCT in children with MDS-related AML is associated with reduced relapse rates but an event-free survival (EFS) of only 47%.<sup>9</sup> Recently, CPX-351 (Vyxeos), a liposomal combination of cytarabine and daunomycin at a fixed 5:1 ratio, has shown promise for treating adult sAML.<sup>10-12</sup> The accumulation and cytotoxic effects of CPX-351 are greater in leukemic blasts than in normal BM cells, thus preferentially suppressing leukemic expansion while permitting rapid repopulation by normal hematopoiesis.<sup>13,14</sup> In newly diagnosed sAML in older adults, CPX-351 induces higher rates of complete response (CR) or CR with incomplete hematologic recovery (CRi), significantly improves OS and EFS, increases HCT enrollment, and reduces mortality compared with standard 7 + 3 regimens.<sup>15,16</sup> The safety and efficacy of CPX-351 were recently demonstrated in relapsed pediatric de novo AML,<sup>17</sup> but there are no data in pediatric sMDS/AML. Here, we report for the first time the application of CPX-351 for remission induction in newly diagnosed pediatric sMDS/AML.

## Methods

Details regarding the patients, diagnostics, and treatment are outlined in the data Supplement. Response criteria in our study were adopted from the 2017 European LeukemiaNet recommendations.<sup>18</sup> CR was defined as complete morphologic response (<5% BM blasts, no blasts with Auer rods, no extramedullary leukemia) with hematologic recovery (transfusion-free status with absolute neutrophil count  $>1.0 \times 10^9/L$  and platelet count  $>100.0 \times 10^9/L$ ). CRi was defined as a complete morphologic response not reaching full hematologic recovery. Partial response was defined as a minimum 50% decrease (to 5% to 25%) in the BM blast percentage, whereas no response was considered to have occurred when the BM blast counts remained above 25%.

## Results and discussion

The study cohort comprised 5 male patients and 2 female patients in whom myeloid malignancy was diagnosed at a median age of 17 years (range, 13-23 years) after therapy for primary solid or hematologic tumors (patient 1 to patient 5 [P1-P5]), arising from MDS related to Cornelia de Lange syndrome (CDL; P6), or presenting with AML with MDS-related changes, multiple organ failure, and multisystemic hyperinflammation (P7) (Table 1). The time from diagnosis of primary malignancy to development of sAML in P1 to P5 ranged from 2.8 years to 15 years (Figure 1A). The median BM blast count in all patients at diagnosis was 56% (range, 24%-72%)

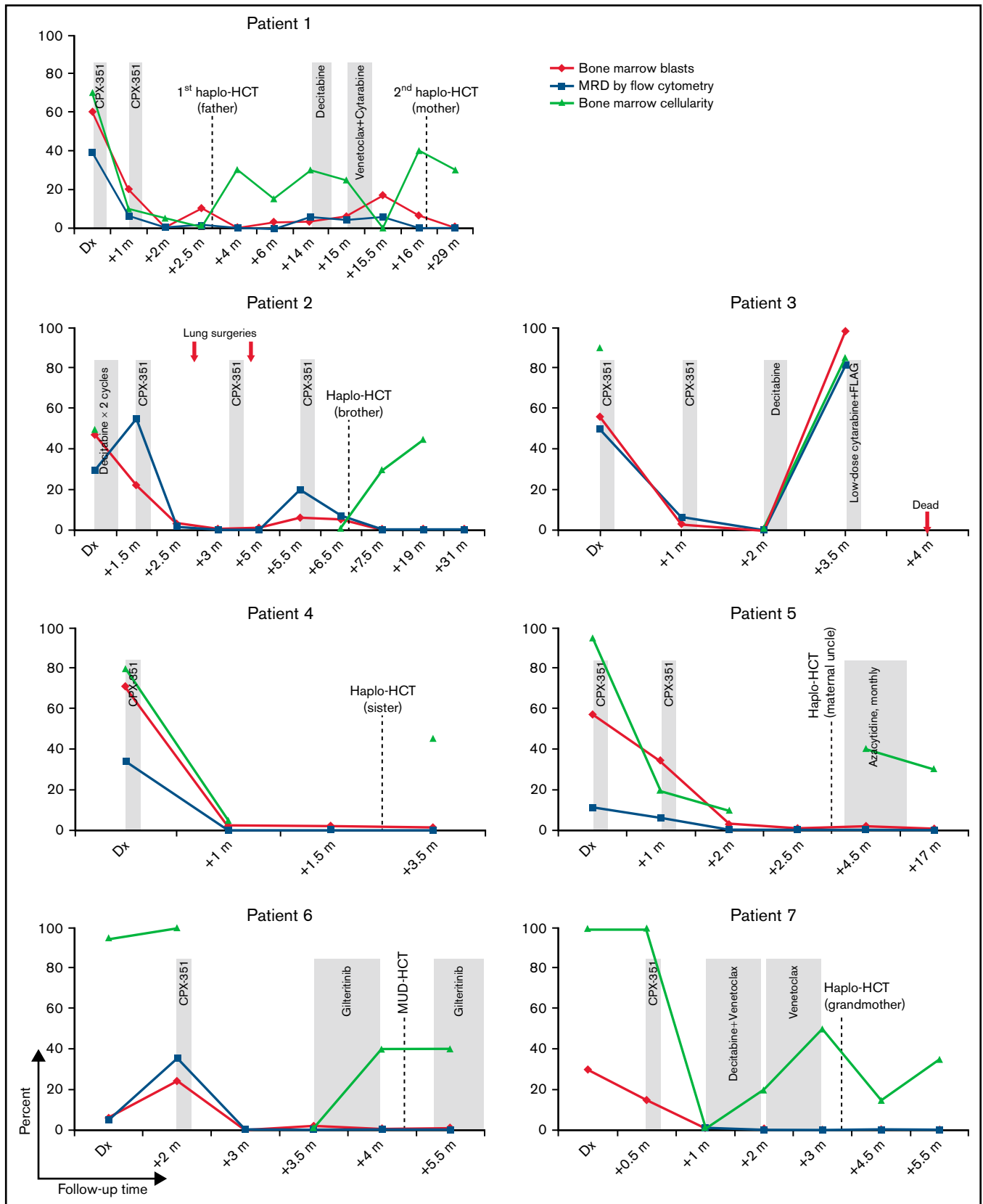
(Figure 1B), and the absolute neutrophil count ranged from  $0.4 \times 10^9/L$  to  $23.7 \times 10^9/L$  (supplemental Table 1).

Genomic studies identified pathogenic germline mutations in *CHEK2* (P4) and *SMC3* (P6) and additional heterozygous variants of uncertain significance in *HLTF* (P3) and *FANCD2* (P1) (supplemental Table 2). A germline-truncating *SMC3* mutation in P6 was compatible with the clinical phenotype of CDL syndrome, a genome instability disorder called cohesinopathy (*SMC3* mutations account for 1% to 2% of patients with CDL syndrome).<sup>19</sup> Two patients with CDL-associated acute lymphoblastic leukemia (ALL) and AML have been previously reported,<sup>20,21</sup> but the CDL-MDS association presented here is new. *CHEK2* mutations are implicated in familial breast cancer,<sup>22</sup> and MDS.<sup>23</sup> Using 3-platform genomics<sup>24</sup> and cytogenetics (data Supplement), we identified somatic mutations and copy-number changes across 16 leukemia driver genes in 6 patients (including *TP53* in 2 patients), abnormal karyotypes in 6 patients, and rearrangements involving *MECOM* or *NIM1K-TERT* in 2 patients (supplemental Table 2).

CPX-351 (cytarabine 100 mg/m<sup>2</sup> plus daunorubicin 44 mg/m<sup>2</sup>) on days 1, 3, and 5 of each cycle was administered to 6 patients as first-line therapy and to 1 patient after 2 unsuccessful 10-day courses of decitabine (Figure 1A). Three patients received either 1 or 2 cycles of CPX-351, and 1 patient received 3 cycles. After the first cycle, all patients experienced a reduction in BM cellularity from a median of 90% at diagnosis to 5% at 4 to 6 weeks after therapy; BM blasts decreased from a median of 56% to 2% (Figure 1B-C). The second cycle of treatment resulted in a reduction of BM blasts to a median of 0.5%. Marrow response was attained in 5 patients after only 1 cycle and in 2 patients after 2 treatment cycles (Figure 2). In summary, all patients attained either CR (after 1 cycle in P4 and 2 cycles in P2 and P5) or CRi (after 1 cycle in P6 and P7 and 2 cycles in P1 and P3). Two patients with initial CRi attained CR while receiving therapy with the FLT3 inhibitor gilteritinib (P6) or with venetoclax and decitabine (P7) (Figure 1A). Four patients (P4-P7) underwent HCT in CR, with a mean minimal residual disease (MRD) of 0.11% (range, 0%-0.29%). Two patients (P1 and P2) underwent HCT with hypoplastic marrows and MRD levels greater than 1.0% (supplemental Table 1). The remaining patient (P3) experienced AML progression while awaiting HCT and died of infection after treatment with intensive regimen with fludarabine, cytarabine, and granulocyte colony-stimulating factor (FLAG) chemotherapy. P1 had increasing marrow blasts 12 months after the first HCT and received a successful second haploidentical HCT from his mother (Figure 2). At last follow-up, 6 patients were alive at a median of 12.5 months (range, 6-39 months) after HCT. Overall, the patients tolerated CPX-351 treatment well; there was no treatment-related mortality, and common complications included febrile neutropenia, oral mucositis, and skin rash (supplemental Table 3).

We encountered unique management challenges in our cohort. P2 presented with bilateral lung osteosarcoma relapse at the time of sAML diagnosis. After he recovered from the first course of CPX-351,

**Figure 1. Treatment procedures and response in patients treated with CPX-351.** (A) Timeline of treatment procedures. (B) Range and median reduction in BM cellularity and blasts after treatment with CPX-351. (C) BM biopsy findings for Patient 7 at diagnosis of AML with MDS-related changes and hyperinflammation (panels i-iii) and 1 month after a single cycle of CPX-351 (panel iv). (i) Hypercellular marrow with sheets of dysplastic megakaryocytes (hematoxylin and eosin [H&E] stain; original magnification  $\times 200$ ). (ii) Increased immature mononuclear cells, normal hematopoiesis absent (H&E stain; original magnification  $\times 600$ ). (iii) Reticulin fibrosis (reticulin stain; original magnification  $\times 400$ ). (iv) Hypocellular marrow with no dysplastic cells or fibrosis (H&E stain; original magnification  $\times 600$ ). FLAG, fludarabine, cytarabine, granulocyte colony-stimulating factor regimen; T-ALL, T-cell acute lymphoblastic leukemia.



**Figure 2. BM findings in individual patients during therapy.** Dx, diagnosis; Haplo, haploidentical donor; m, months; MUD, matched unrelated donor; MRD, minimal residual disease.

the left lung lesions were resected. After hematologic recovery from a second course of CPX-351, he underwent resection of the right lung metastases. This latter surgical procedure was complicated by a wound infection that delayed HCT and by the resurgence of AML. Accordingly, another course of CPX-351 was administered before the patient underwent HCT. P7 presented with severe multisystem inflammation associated with severe cardiac, pulmonary, and renal failure. To our surprise, she tolerated CPX-351 very well and received decitabine and venetoclax for consolidation to bridge to HCT. P6, with CDL syndrome and *FLT3*-internal tandem duplication (*FLT3*-ITD)-positive sAML, had excellent response to CPX-351 and afterward received gilteritinib for bridging to HCT and after HCT (day + 100).

Limitations of our study are its retrospective nature and lack of a comparison cohort, limited cohort size, and a short follow-up after HCT. Nonetheless, this case series is representative of pediatric sMDS/AML and includes patients with somatic *TP53* mutations, complex karyotypes, hyperinflammation, and inherited genomic instability, all of which are known factors for poor prognosis. The combination of cytarabine with daunomycin is the mainstay of treatment in AML, and CPX-351 represents an optimized strategy to deliver this combination, which results in excellent cytoreductive efficacy and in bringing all patients to CR/CRi after only 1 or 2 cycles. Most importantly, we observed low toxicity despite extensive pretreatments or poor clinical condition. This opens a window of opportunity for targeted bridge-to-transplant approaches (such as the *FLT3* inhibitor gilteritinib in our cohort), particularly useful in patients for whom HCT is not readily available.

Secondary myeloid malignancies in young individuals are orphan diseases that lack therapeutic innovation and unified treatment. The promising data from our study supports the need for prospective

multicenter trials to define the long-term benefit of CPX-351 in pediatric secondary myeloid malignancies.

## Acknowledgments

The authors thank the clinical and diagnostic staff at St. Jude Children's Hospital, in particular, Ashok Srinivasan (MD), Renee Madden (MD), Amr Oudeimat (MD), Hiroto Inaba (MD), Jeffery Klco, Jessica Uhrich, Andrea Kennedy, Michelle Brignac, Jason Hodges, Melvanique Hale, Nathan Gray, and Michelle Boals.

## Authorship

Contribution: R.C.R. designed the study; K.J.C., S.M.F., M.S., K.E.N., C.M.T., J.E.F., J.E.R., B.M.T., and R.C.R. were involved in patient care; Y.H., M.O., S. Lewis, J.Z., S. Lei., and M.W.W. were involved in diagnostics and research; and Y.H., K.J.C., R.C.R., and M.W.W. wrote the manuscript.

Conflict-of-interest disclosure: The authors declare no competing financial interests.

ORCID profiles: K.E.N., 0000-0002-5581-6555; C.M.T., 0000-0002-2832-6884; B.M.T., 0000-0001-8220-9980; J.E.F., 0000-0003-2148-5839; J.E.R., 0000-0001-9885-3527; R.C.R., 0000-0002-9956-5647; M.W.W., 0000-0001-6638-9643.

Correspondence: Marcin W. Wlodarski, St. Jude Children's Research Hospital, 262 Danny Thomas Pl, Memphis, TN 38105; e-mail: marcin.wlodarski@stjude.org; and Raul C. Ribeiro, St. Jude Children's Research Hospital, 262 Danny Thomas Pl, Memphis, TN 38105; e-mail: raul.ribeiro@stjude.org.

## References

1. Arber DA, Orazi A, Hasserjian R, et al. The 2016 revision to the World Health Organization classification of myeloid neoplasms and acute leukemia. *Blood*. 2016;127(20):2391-2405.
2. Granfeldt Østgård LS, Medeiros BC, Sengeløv H, et al. Epidemiology and clinical significance of secondary and therapy-related acute myeloid leukemia: A national population-based cohort study. *J Clin Oncol*. 2015;33(31):3641-3649.
3. Myers KC, Furutani E, Weller E, et al. Clinical features and outcomes of patients with Shwachman-Diamond syndrome and myelodysplastic syndrome or acute myeloid leukaemia: a multicentre, retrospective, cohort study. *Lancet Haematol*. 2020;7(3):e238-e246.
4. Andolina JR, Kletzel M, Tse WT, et al. Allogeneic hematopoietic stem cell transplantation in pediatric myelodysplastic syndromes: improved outcomes for de novo disease. *Pediatr Transplant*. 2011;15(3):334-343.
5. Moriwaki K, Manabe A, Taketani T, Kikuchi A, Nakahata T, Hayashi Y. Erratum to: Cytogenetics and clinical features of pediatric myelodysplastic syndrome in Japan. *Int J Hematol*. 2015;102(2):249.
6. Locatelli F, Zecca M, Niemeyer C, et al; The European Working Group on Childhood Myelodysplastic Syndrome (EWOG-MDS) and the Austria-Germany-Italy (AGI) Bone Marrow Transplantation Registry. Role of allogeneic bone marrow transplantation for the treatment of myelodysplastic syndromes in childhood. *Bone Marrow Transplant*. 1996;18(suppl 2):63-68.
7. Sasaki H, Manabe A, Kojima S, et al; MDS Committee of the Japanese Society of Pediatric Hematology, Japan. Myelodysplastic syndrome in childhood: a retrospective study of 189 patients in Japan. *Leukemia*. 2001;15(11):1713-1720.
8. Strahm B, Wlodarski MW, Pastor VB, et al. Impact of somatic mutations on the outcome of children and adolescents with therapy-related myelodysplastic syndrome [abstract]. *Blood*. 2016;128(22). Abstract 3162.
9. Strahm B, Nölke P, Zecca M, et al; EWOG-MDS study group. Hematopoietic stem cell transplantation for advanced myelodysplastic syndrome in children: results of the EWOG-MDS 98 study. *Leukemia*. 2011;25(3):455-462.
10. Oliari C, Schiller G. How to address second and therapy-related acute myelogenous leukaemia. *Br J Haematol*. 2020;188(1):116-128.
11. Lancet JE, Cortes JE, Hogge DE, et al. Phase 2 trial of CPX-351, a fixed 5:1 molar ratio of cytarabine/daunorubicin, vs cytarabine/daunorubicin in older adults with untreated AML. *Blood*. 2014;123(21):3239-3246.
12. Cortes JE, Goldberg SL, Feldman EJ, et al. Phase II, multicenter, randomized trial of CPX-351 (cytarabine:daunorubicin) liposome injection versus intensive salvage therapy in adults with first relapse AML. *Cancer*. 2015;121(2):234-242.

13. Mayer LD, Tardi P, Louie AC. CPX-351: a nanoscale liposomal co-formulation of daunorubicin and cytarabine with unique biodistribution and tumor cell uptake properties. *Int J Nanomedicine*. 2019;14:3819-3830.
14. Lim WS, Tardi PG, Dos Santos N, et al. Leukemia-selective uptake and cytotoxicity of CPX-351, a synergistic fixed-ratio cytarabine:daunorubicin formulation, in bone marrow xenografts. *Leuk Res*. 2010;34(9):1214-1223.
15. Lancet JE, Uy GL, Cortes JE, et al. CPX-351 (cytarabine and daunorubicin) liposome for injection versus conventional cytarabine plus daunorubicin in older patients with newly diagnosed secondary acute myeloid leukemia. *J Clin Oncol*. 2018;36(26):2684-2692.
16. Ryan DH, Uy GL, Cortes JE, et al. Efficacy and safety of CPX-351 versus 7 + 3 in a subgroup of older patients with newly diagnosed acute myeloid leukemia with myelodysplasia-related changes (AML-MRC) enrolled in a phase 3 study [abstract]. *Blood*. 2018;132(suppl 1). Abstract 1425.
17. Cooper TM, Absalon MJ, Alonzo TA, et al. Phase I/II study of CPX-351 followed by fludarabine, cytarabine, and granulocyte-colony stimulating factor for children with relapsed acute myeloid leukemia: A report from the Children's Oncology Group. *J Clin Oncol*. 2020;38(19):2170-2177.
18. Döhner H, Estey E, Grimwade D, et al. Diagnosis and management of AML in adults: 2017 ELN recommendations from an international expert panel. *Blood*. 2017;129(4):424-447.
19. Gil-Rodríguez MC, Deardorff MA, Ansari M, et al. De novo heterozygous mutations in SMC3 cause a range of Cornelia de Lange syndrome-overlapping phenotypes. *Hum Mutat*. 2015;36(4):454-462.
20. Vial Y, Lachenaud J, Verloes A, et al. Down syndrome-like acute megakaryoblastic leukemia in a patient with Cornelia de Lange syndrome. *Haematologica*. 2018;103(6):e274-e276.
21. Fazio G, Massa V, Grioni A, et al. First evidence of a paediatric patient with Cornelia de Lange syndrome with acute lymphoblastic leukaemia. *J Clin Pathol*. 2019;72(8):558-561.
22. Kleiblova P, Stolarova L, Krizova K, et al. Identification of deleterious germline CHEK2 mutations and their association with breast and ovarian cancer. *Int J Cancer*. 2019;145(7):1782-1797.
23. Janiszewska H, Bąk A, Skonieczka K, et al. Constitutional mutations of the CHEK2 gene are a risk factor for MDS, but not for de novo AML. *Leuk Res*. 2018;70:74-78.
24. Rusch M, Nakitandwe J, Shurtleff S, et al. Clinical cancer genomic profiling by three-platform sequencing of whole genome, whole exome and transcriptome. *Nat Commun*. 2018;9(1):3962.