

TO THE EDITOR:

Immunoglobulin isotype switch after anti-BCMA CAR T-cell therapy for relapsed or refractory multiple myeloma

Zhiyu Liang,^{1,*} Ping Li,^{1,*} Liqing Kang,^{2,3,*} Lili Zhou,¹ Yang Xu,⁴ Shiguang Ye,¹ Juan Du,⁵ Bing Li,¹ Yiwen Wang,⁶ Lei Yu,^{2,3} Wenbin Qian,⁴ and Aibin Liang¹

¹Department of Hematology, Tongji Hospital of Tongji University, Shanghai, China; ²Institute of Biomedical Engineering and Technology, Shanghai Engineering Research Center of Molecular Therapeutics and New Drug Development, School of Chemistry and Molecular Engineering, East China Normal University, Shanghai, China; ³Shanghai Unicar-Therapy Bio-medicine Technology Co., Ltd, Shanghai, China; ⁴Department of Hematology, The Second Affiliated Hospital, College of Medicine, Zhejiang University, Hangzhou, China; ⁵Department of Hematology, Myeloma & Lymphoma Center, Shanghai Changzheng Hospital, The Second Military Medical University, Shanghai, China; and ⁶Shanghai World Foreign Language Academy, Shanghai, China

The malignant plasma cell clone in patients with multiple myeloma (MM) is represented by the production of paraprotein, usually a single abnormal unique monoclonal heavy and/or light chain with constant isotype.¹ Switching of the paraprotein or transient presence of oligoclonal bands on serum immunofixation electrophoresis occurs in up to 73% of patients after autologous stem cell transplantation (ASCT) and high-dose chemotherapy.²⁻⁴ The emergence of these abnormal protein bands (APBs) may represent more durable immune reconstitution and be associated with favorable prognosis in that setting.⁴⁻⁷

B-cell maturation antigen (BCMA)-specific chimeric antigen receptor (CAR) T-cell therapy is emerging as a promising treatment for patients with relapsed or refractory (R/R) MM. BCMA CAR T-cell therapy resulted in high overall response rates (range, 64%-88%) in multiple recent clinical trials.⁸⁻¹¹ CAR T-cell therapy, like ASCT and high-dose chemotherapy, involves the activation and regulation of the immune system.¹² Specifically, plasma cells and mature B lymphocytes targeted by BCMA CAR T cells are also integral components of the humoral immune system. However, the prevalence and clinical significance of APBs in patients with MM after CAR T-cell therapy remain unclear.

Between 1 January 2018 and 1 February 2020, 12 consecutive patients with R/R MM were enrolled in a clinical trial of BCMA CAR T cells (registered at www.clinicaltrials.gov as #NCT04500431). This study was approved by the Tongji Hospital of Tongji University Ethics Committee, and written informed consent was provided by each patient. All studies were conducted in accordance with the Declaration of Helsinki. Full details on BCMA CAR T-cell manufacturing and clinical procedures are provided in the data supplement. In the 12 patients treated, the overall response rate was 75% (9 of 12), with a strict complete response (sCR) in 67% (8 of 12) and a very good partial response in 8% (1 of 12; Figure 1A). Quantitative real-time polymerase chain reaction showed those patients with response (partial response or better) had a peak in CAR transgene copies in peripheral blood between days 7 and 21, which then dropped to low or undetectable levels by 6 months (supplemental Figure 1). With a median follow-up of 15 months (range, 4-26), the median PFS and the median overall survival were 12 months and not reached, respectively (Figure 1B-C). The adverse events within 30 days after infusion were well tolerated. Toxic hematologic effects were the most common grade ≥ 3 events, including neutropenia (67%), anemia (42%), and thrombocytopenia (33%). A total of 11 patients (92%) had cytokine release syndrome, which was grade 1 or 2 in 9 patients (75%) and grade 3 in 2 patients (17%). Only 1 patient experienced grade 1 neurologic toxicity. Three patients (25%) received tocilizumab and/or glucocorticoids. No patients experienced severe infection within 30 days after infusion. Detailed patient baseline characteristics, treatment response, and toxicities are described in supplemental Tables 1 and 2.

During follow-up after CAR T-cell therapy, we observed that 4 patients (33%) had APBs on serum immunofixation electrophoresis distinct from the paraprotein present at diagnosis, which were below the level

Submitted 23 July 2021; accepted 19 October 2021; prepublished online on *Blood Advances* First Edition 10 November 2021; final version published online 11 January 2022. DOI 10.1182/bloodadvances.2021005814.

*Z.L., P.L., and L.K. contributed equally to this study.

Requests for data sharing may be submitted to Aibin Liang (lab7182@tongji.edu.cn).

The full-text version of this article contains a data supplement.

© 2022 by The American Society of Hematology. Licensed under Creative Commons Attribution-NonCommercial-NoDerivatives 4.0 International (CC BY-NC-ND 4.0), permitting only noncommercial, nonderivative use with attribution. All other rights reserved.

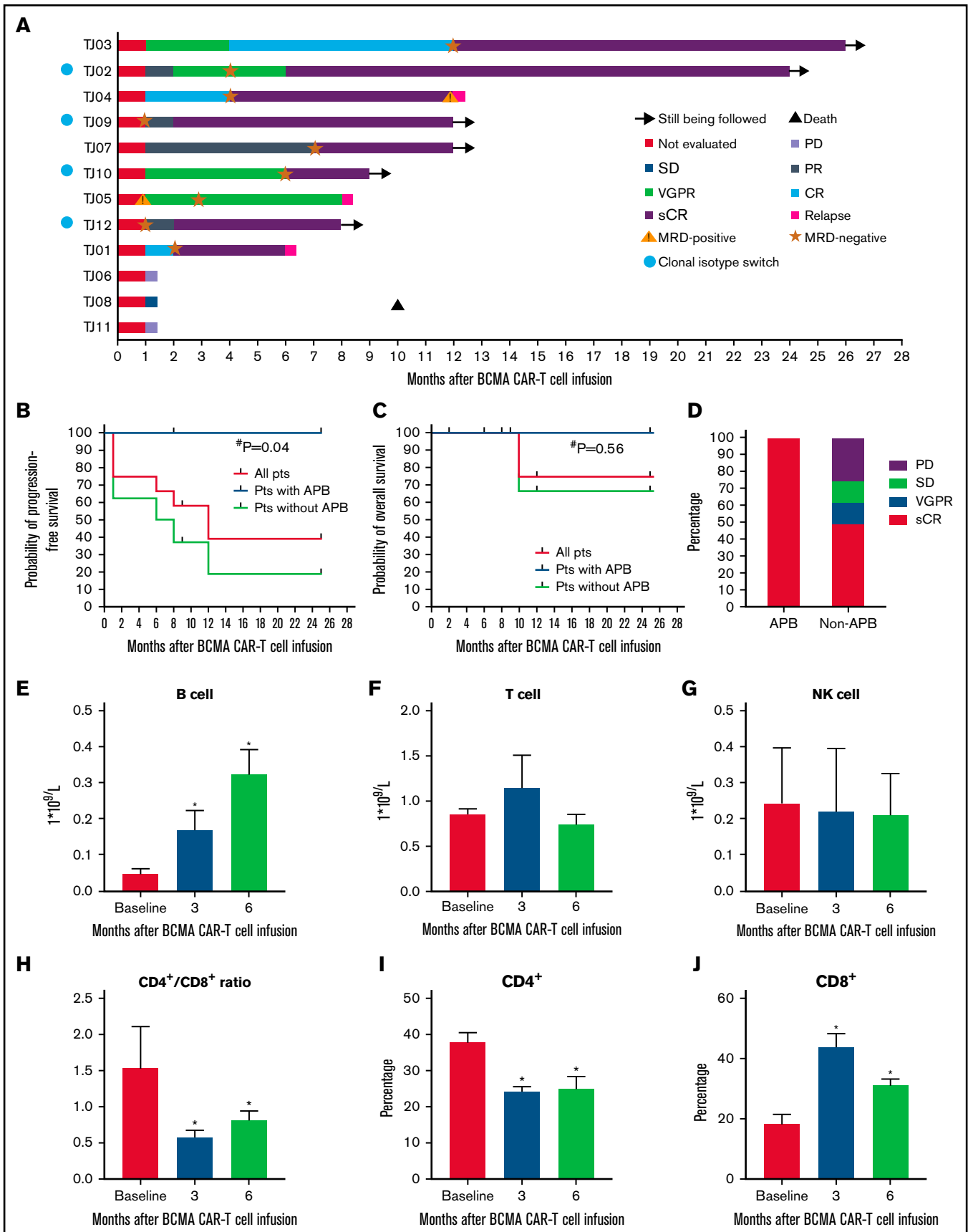


Figure 1.

Table 1. Isotype changes in and characteristics of patients with APBs (n = 4)

ID	Sex	Age, y	Primary monoclonal protein	ASCT	Last treatment line regimen	Time from last line of treatment to CAR T-cell infusion, mo	Clonal band pattern	Time from infusion to onset of APBs, mo	APB duration, mo	Clinical response	PFS, mo
TJ02	M	73	IgG λ	No	TD	3	IgG λ → IgG κ + IgG λ → IgG κ → normal	3	9	sCR	25
TJ09	F	51	IgD λ	No	RCD	6	(IgD) λ → IgG λ → IgG κ + IgG λ → normal	2	7	sCR	12
TJ10	M	49	IgG λ	No	VDEP	3	IgG λ → oligo IgG κ + IgG λ → normal	6	3	sCR	9
TJ12	M	53	κ light chain	No	VRD	3	κ → normal → IgG κ + oligo IgG λ → normal	5	3	sCR	8

Ig, immunoglobulin; RCD, lenalidomide, cyclophosphamide, and dexamethasone; TD, thalidomide and dexamethasone; VDEP, bortezomib, dexamethasone, etoposide, and cisplatin; VRD, bortezomib, lenalidomide, and dexamethasone.

of detection (0.1 g/dL) for all measurements by serum protein electrophoresis (Table 1; supplemental Figure 2). Baseline characteristics, such as age, extramedullary disease, prior lines of therapy, and tumor burden, in the 4 patients with APBs were similar to those in patients without APBs (supplemental Table 3). Several studies reported that APBs emerged during immunomodulatory and/or bortezomib combination therapies as well as after ASCT.^{13,14} In this study, none of these patients with APBs received ASCT before CAR T-cell therapy, and the intervals from last treatment to CAR T-cell infusion in the 4 patients were >3 months (Table 1), suggesting that those agents were less likely to be the sole contributors to APB occurrence. Of the 4 patients with APBs, 2 had only isotype switch (IS), and 2 had both IS and oligoclonal bands. All ISs occurred with clones that made immunoglobulin G κ and/or immunoglobulin G λ (supplemental Figure 2A-D). The median time to occurrence of APBs from CAR T-cell infusion was 4 months (range, 2-6). The median duration of APBs was 5 months (range, 3-9).

At detection of the APBs, all 4 patients were completely asymptomatic and free of hypercalcemia, renal failure, anemia, and bone disease complications. Bone marrow examination showed that bone marrow morphology was normal, and there was no evidence of a neoplastic plasma cell population by flow cytometric analysis at the time of the APBs. Patient TJ12 had 2 abdominal masses before CAR T-cell infusion that resolved on positron emission tomography-computed tomography during APB occurrence (supplemental Figure 2E). These results suggest the APBs were not associated with relapse of disease or emergence of a clone of malignant plasma cells.

APB occurrence has been shown to correlate with superior survival in patients with MM who have undergone ASCT.^{5,6} In this study, we performed a post hoc analysis of clinical outcomes between patients with and patients without APBs to determine if APBs also had prognostic significance in the post-CAR T-cell setting. Interestingly, all 4 patients with APBs achieved an sCR (100%) within 6 months, and the remission states were sustained at the last follow-up. Of those without APBs, 5 patients achieved an objective response, with 4 reaching an sCR (50%) and 1 reaching a very

good partial response (12.5%; Figure 1D). With a median follow-up of 15 months, the median overall survival has not been reached in patients with and without APBs ($P = .56$); however, the median PFS in patients without APBs was only 7 months, whereas the median PFS in patients with APBs was not reached ($P = .04$; Figure 1B-C).

The etiology of the APB phenomenon remains unclear. The appearance of APBs could be associated with immune reconstitution and recovery of B-cell function, as a result of the alleviation of myeloma-induced immunosuppressive effects after high-dose chemotherapy.^{4,7} We hypothesized that a similar mechanism could underlie the phenomenon of APBs occurring after BCMA CAR T-cell therapy. Therefore, we analyzed the changes of blood immune cell subsets pre- and post-CAR T-cell therapy in the cohort of patients with APBs. At baseline, the number of circulating CD19⁺ B cells in those patients were below normal levels, which is a very common condition in patients with MM with disease progression. At time points >3 months after CAR T-cell infusion, patients had normal and greater than normal numbers of circulating B cells (Figure 1E). Although the absolute number of blood T cells did not change significantly after CAR T-cell therapy (Figure 1F), the CD4/CD8 ratios were inverted from 1.54 at baseline to 0.58 at 3 months and 0.81 at 6 months (Figure 1H), which was related to an increase in CD4⁺ T-cell percentage and a decrease in CD8⁺ T-cell percentage (Figure 1I-J). There are no significant changes in the absolute numbers of natural killer cells before and after CAR T-cell therapy (Figure 1G). These results suggest that APB occurrence after CAR T-cell therapy could be a transient process accompanied by restoration of B-cell function and T-cell immune reconstitution. Because of the limited data in this study, the subpopulation of B cells responsible for production of the paraprotein could not be defined, and additional studies are needed to elucidate the precise source of the paraprotein.

In summary, this is the first report of an APB phenomenon in patients with R/R MM after BCMA CAR T-cell therapy. Our results showed an incidence of APBs of 33.3%, and patients with APBs

Figure 1. Clinical response in patients with R/R MM to BCMA CAR T-cell therapy and immune signatures of patients with APBs. (A) Duration of response to CAR T cells and postinfusion survival in 12 patients with R/R MM. Cyan dots indicate that patients developed APBs after CAR T-cell infusion. (B-C) Progression-free survival (PFS) and overall survival of patients with MM with or without APBs after CAR T-cell therapy (mean \pm standard error of the mean [SEM]). (D) Response of patients with MM with or without APBs after CAR T-cell therapy. (E-G) Count of blood B cells, T cells, and natural killer (NK) cells (mean \pm SEM). (H) Ratio of CD4⁺ and CD8⁺ cells. (I-J) Percentage of CD4⁺ and CD8⁺ cells in blood lymphocytes. * $P < .05$. #Patients without APBs vs patients with APBs. MRD, minimal residual disease; PD, progressive disease; PR, partial response; SD, stable disease; VGPR, very good partial response.

had a higher CR percentage and better outcome compared with those without APBs. Our results also suggest that APBs are more likely a temporary benign phenomenon associated with restoration of B-cell function and immune reconstitution rather than malignant transformation. Therefore, it is important for practitioners to clarify the clinical significance of APB occurrence after BCMA CAR-T cell therapy and obviates the inappropriate consideration of salvage therapy. A limitation of this study is the small sample size. The true incidence and clinical significance of APB occurrence after CAR T-cell therapy warrant further validation with larger numbers of patients in prospective clinical trials.

Acknowledgments: This work was supported by funds from the National Natural Science Foundation of China (81830004, 81830006 and 82070168), from a Northeast China Rural Cardiovascular Health translational research grant (2020ZKZC04), and from the Science Foundation of Shanghai Municipal Health Commission (2020CXJQ02).

Contribution: Z.L., P.L., L.K., W.Q., and A.L. were responsible for study design, data interpretation, and data analysis. Z.L. and P.L. wrote the manuscript. All authors recruited patients and contributed to data collection. All authors reviewed, edited, and approved the manuscript.

Conflict-of-interest disclosure: The authors declare no competing financial interests.

ORCID profiles: Z.L., 0000-0003-2764-2970; J.D., 0000-0003-2538-4007.

Correspondence: Aibin Liang, Department of Hematology, Tongji Hospital of Tongji University, No 389 Xincun Road, Shanghai 200065, China; e-mail: lab7182@tongji.edu.cn; Wenbin Qian, Department of Hematology, The Second Affiliated Hospital, College of Medicine, Zhejiang University, No 88 Jiefang Road, Hangzhou 310009, China; e-mail: qianwb@zju.edu.cn; and Lei Yu, Institute of Biomedical Engineering and Technology, Shanghai Engineering Research Center of Molecular Therapeutics and New Drug Development, School of Chemistry and Molecular Engineering, East China Normal University, NO, 3663 North Zhongshan Road, Shanghai 200065, China; e-mail: ylyh188@163.com.

References

1. Rajkumar SV, Dimopoulos MA, Palumbo A, et al. International Myeloma Working Group updated criteria for the diagnosis of multiple myeloma. *Lancet Oncol*. 2014;15(12):e538-e548.
2. Hall SL, Tate J, Gill D, Mollee P. Significance of abnormal protein bands in patients with multiple myeloma following autologous stem cell transplantation. *Clin Biochem Rev*. 2009;30(3):113-118.
3. Maisnar V, Tichý M, Smolej L, et al. Isotype class switching after transplantation in multiple myeloma. *Neoplasma*. 2007; 54(3):225-228.
4. Zent CS, Wilson CS, Tricot G, et al. Oligoclonal protein bands and Ig isotype switching in multiple myeloma treated with high-dose therapy and hematopoietic cell transplantation. *Blood*. 1998; 91(9):3518-3523.
5. Jo JC, Yoon DH, Kim S, et al. Clinical significance of the appearance of abnormal protein band in patients with multiple myeloma. *Ann Hematol*. 2014;93(3):463-469.
6. Ye R, Kundrapu S, Gerson SL, et al. Immune signatures associated with clonal isotype switch after autologous stem cell transplantation for multiple myeloma. *Clin Lymphoma Myeloma Leuk*. 2019; 19(5):e213-e220.
7. Mitus AJ, Stein R, Rapoport JM, et al. Monoclonal and oligoclonal gammopathy after bone marrow transplantation. *Blood*. 1989; 74(8):2764-2768.
8. Brudno JN, Maric I, Hartman SD, et al. T cells genetically modified to express an anti-B-cell maturation antigen chimeric antigen receptor cause remissions of poor-prognosis relapsed multiple myeloma. *J Clin Oncol*. 2018;36(22):2267-2280.
9. Raje N, Berdeja J, Lin Y, et al. Anti-BCMA CAR T-cell therapy bb2121 in relapsed or refractory multiple myeloma. *N Engl J Med*. 2019;380(18):1726-1737.
10. Xu J, Chen LJ, Yang SS, et al. Exploratory trial of a biepitopic CAR T-targeting B cell maturation antigen in relapsed/refractory multiple myeloma. *Proc Natl Acad Sci USA*. 2019; 116(19):9543-9551.
11. Mailankody S, Ghosh A, Staehr M, et al. Clinical responses and pharmacokinetics of MCRH171, a human-derived Bcma targeted CAR T cell therapy in relapsed/refractory multiple myeloma: final results of a phase I clinical trial [abstract]. *Blood*. 2018; 132(suppl 1):959.
12. McLellan AD, Ali Hosseini Rad SM. Chimeric antigen receptor T cell persistence and memory cell formation. *Immunol Cell Biol*. 2019; 97(7):664-674.
13. Fernández de Larrea C, Tovar N, Cibeira MT, et al. Emergence of oligoclonal bands in patients with multiple myeloma in complete remission after induction chemotherapy: association with the use of novel agents. *Haematologica*. 2011; 96(1):171-173.
14. Chim CS. Updated survivals and prognostic factor analysis in myeloma treated by a staged approach use of bortezomib/thalidomide/dexamethasone in transplant eligible patients. *J Transl Med*. 2010;8:124.