

Hurdles in treating Hurler disease: potential routes to achieve a “real” cure

Brigitte T. A. van den Broek,¹⁻³ Jaap van Doorn,⁴ Charlotte V. Hegeman,¹ Stefan Nierkens,^{5,6} Caroline A. Lindemans,^{1,6} Nanda Verhoeven-Duif,⁴ Jaap Jan Boelens,^{1,7} and Peter M. van Hasselt^{1,3}

¹Sylvia Toth Center for Multidisciplinary Follow-up after Hematopoietic Cell Transplantation, ²Pediatric Bone and Marrow Transplantation Program, and ³Department of Pediatric Metabolic Diseases, Wilhelmina Children's Hospital, University Medical Center Utrecht, Utrecht University, Utrecht, The Netherlands; ⁴Section of Metabolic Diagnostics, Department of Genetics, and ⁵Center for Translational Immunology, University Medical Center Utrecht, Utrecht University, Utrecht, The Netherlands; ⁶Princess Maxima Center for Pediatric Oncology, Utrecht, The Netherlands; and ⁷Pediatric Blood and Marrow Transplantation Program, Memorial Sloan Kettering Cancer Center, New York, NY

Mucopolysaccharidoses (MPSs) are multiorgan devastating diseases for which hematopoietic cell transplantation (HCT) and, to a lesser extent, enzyme replacement therapy have substantially altered the course of the disease. Furthermore, they have resulted in increased overall survival, especially for Hurler disease (MPS-1). However, despite the identification of clinical predictors and harmonized transplantation protocols, disease progression still poses a significant burden to patients, although at a slower pace. To design better therapies, we need to understand why and where current therapies fail. In this review, we discuss important aspects of the underlying disease and the disease progression. We note that the majority of progressive symptoms that occur in “hard-to-treat” tissues are actually tissues that are difficult to reach, such as avascular connective tissue or tissues isolated from the circulation by a specific barrier (eg, blood-brain barrier, blood-retina barrier). Although easily reached tissues are effectively cured by HCT, disease progression is observed in these “hard-to-reach” tissues. We used these insights to critically appraise ongoing experimental endeavors with regard to their potential to overcome the encountered hurdles and improve long-term clinical outcomes in MPS patients treated with HCT.

Introduction

It has been >50 years since Fratantoni et al¹ described that cocultured fibroblasts of patients with Hurler disease (mucopolysaccharidosis [MPS]-1) and Hunter disease (MPS-2) corrected each other, leading to a mutual reduction in the intracellular accumulation of glycosaminoglycans (GAGs). Hurler syndrome and Hunter syndrome are 2 of the 7 types of MPSs in which a deficiency in a specific lysosomal enzyme prevents proper degradation of specific metabolites, resulting in a devastating progressive multisystemic disease and, if severe, in premature death.² In 1981, Hobbs et al³ reported the first hematopoietic cell transplantation (HCT) in a 1-year-old patient with MPS-1 based on the principle of cross-correction. HCT has become the standard of care in MPS-1, if diagnosed in a timely manner. Intense international collaboration during the last decade has identified predictors of clinical outcomes, including myeloablative conditioning, early timing of transplantation, and enzyme activity level in blood after HCT. This has resulted in optimized transplantation protocols and 5-year survival rates > 90%. Enzyme replacement therapy (ERT) for MPS-1 was introduced in 2003, followed by ERT for MPS-2, MPS-4, MPS-6, and MPS-7.⁴⁻⁶ Unfortunately, ERT comes with serious limitations (eg, neutralizing antibodies, lack of blood-brain barrier [BBB] passage, and huge costs).

Despite the greatly improved overall survival, current standard treatments still have their “weak spots,” because they are unable to completely halt the disease in specific tissues. Late outcome studies show

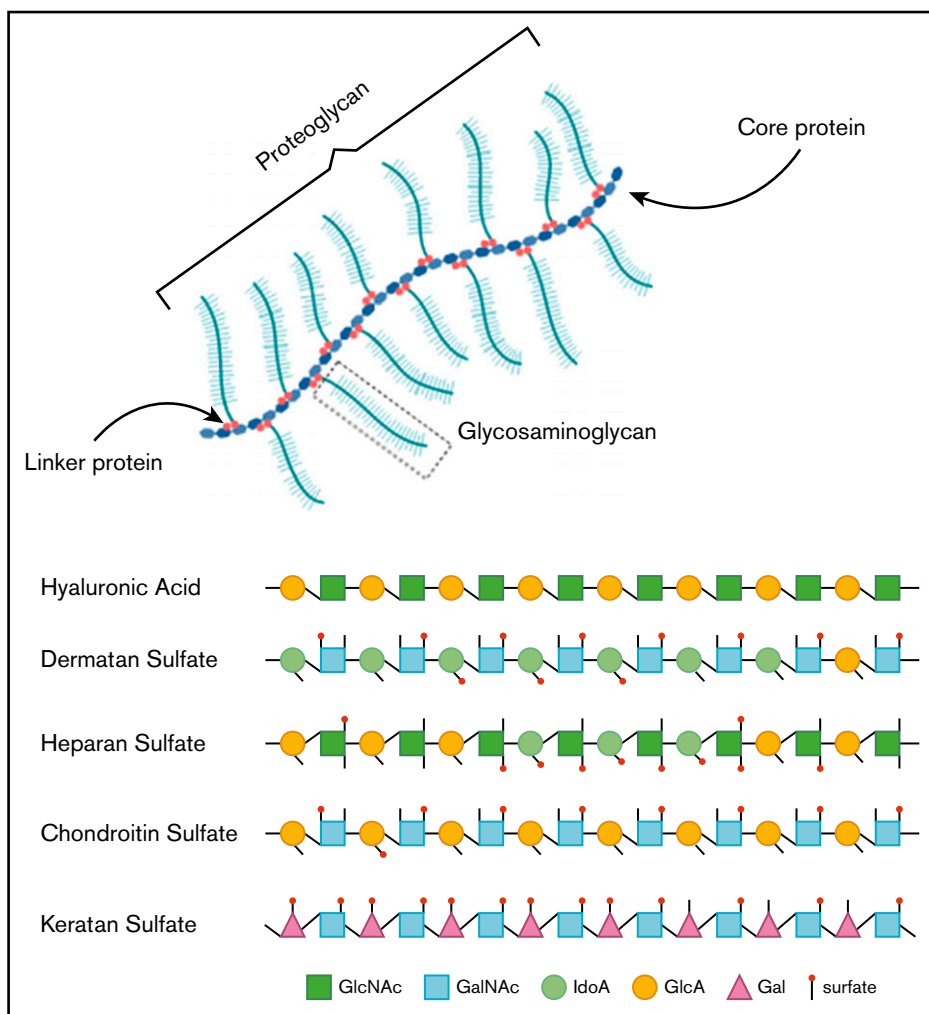


Figure 1. Overview of GAGs within a proteoglycan and the different GAG subtypes.

significant residual disease burden.⁷⁻¹¹ Although many researchers have been trying to develop new therapies to improve clinical outcomes, the primary outcomes in these (animal) studies are often enzyme activity and GAG concentration in receptive tissues: leukocytes in the circulation, brain, liver, spleen, and lungs. This is unfortunate because we are already capable of treating these tissues. In the medical field, Sutton's Law, which is named after the infamous thief Willie Sutton who robbed banks because "that's where the money is," recommends that one should first consider the obvious. Therefore, we propose that, to evaluate whether new therapies are able to improve quality of life in MPS patients, the focus of the effect should be on the "hard-to-treat" tissues and how to improve this effect, because obviously "that's where the money is."

To design better strategies, we first need to understand why current therapies fail. Why are some tissues hard to treat? Therefore, a better understanding of disease pathogenesis and the mechanism of current treatments is necessary. In this review, we summarize important aspects of the underlying disease, establish which tissues are "hard to treat," and define their unifying characteristics. Furthermore, we critically appraise experimental therapeutic endeavors with regard to their potential to overcome these hurdles and improve long-term clinical outcomes of MPS patients.

Understanding the underlying disease

In healthy individuals, GAGs, formerly called mucopolysaccharides, represent complex sugar molecules that are degraded in a stepwise manner by enzymes in the lysosome (Figure 1).¹² The 2 main groups are sulfated GAGs (heparan sulfate [HS], dermatan sulfate [DS], keratan sulfate [KS], and chondroitin sulfate) and nonsulfated GAGs (hyaluronic acid [HA]). All GAG chains, with the exception of HA, are linked to a core protein to form proteoglycans (PGs).¹² PGs are important components of the extracellular matrix (ECM) of connective tissue and, furthermore, contribute to the ordering process of collagen fibers.¹³ During development, PGs are important in the assembly of ECM in tissue morphogenesis to determine form and function of a tissue.¹⁴ ECM is essential in the communication between cells. Communication is modulated via interactions between GAG chains and ECM components, such as collagen, fibronectin, and laminin.^{13,15} Some PGs are also known to bind and regulate a number of distinct proteins, including chemokines, cytokines, and growth factors.¹⁶

Hence, GAGs, either in chain form or as a part of larger PGs, are important components of connective tissue throughout the body, including the skeleton, cornea, cartilage, tendons, and, to a lesser extent, the brain (Figure 2).¹⁷ Free GAGs and proteoglycans are

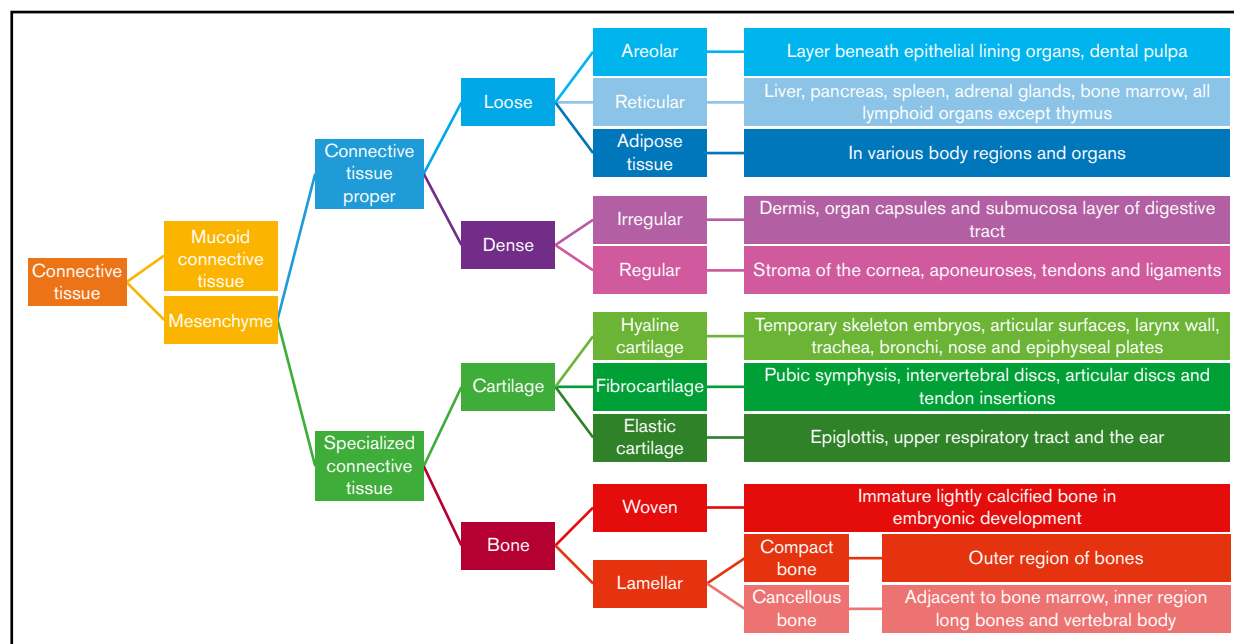


Figure 2. Classification of connective tissue.

biologically active molecules that are involved in critical cellular pathways. They can isolate extracellular humoral factors, modulate the function of cell surface receptors in signal transduction and cross talk between cells. PGs are expressed during skeletal development, and they are spatially and temporally regulated in a highly defined pattern.¹⁸

In MPS, deficiency of a lysosomal enzyme results in the accumulation of partially degraded GAGs. Primary GAG storage leads to perturbation of cellular, tissue, and organ homeostasis.¹⁹ Subsequently, the pathways in which they are involved will become affected. These secondary effects, such as impaired autophagy, increased apoptosis, and inflammation, are also important effectors of the disease symptoms (Figure 3).²⁰ The main clinical symptoms are coarse facial features, hepato- and splenomegaly, dysostosis multiplex, joint stiffness, recurrent respiratory infections, sleep apnea, heart disease, and, in severe subtypes, cognitive impairment and a reduced life expectancy. The time of onset, rate of progression, and extent of disease manifestations vary, depending on the type of MPS.² Details about the specific types of MPS can be found in Table 1.

Understanding disease progression in “hard-to-treat” tissues: in search of common themes

Disease progression related to connective tissue

Skeletal malformations. Skeletal deformities are extremely common in MPS disorders, and the benefits of HCT or ERT are limited.^{5,21-23} Thoracolumbar kyphosis, hip dysplasia, and genu valgum progress in the majority of patients, albeit at a slower pace.²⁴⁻²⁶ Several factors are thought to contribute to skeletal malformations. First, ossification and mineralization depend on the distribution of growth factors (ie, insulin-like growth factors, fibroblast growth factors, parathyroid hormone-related protein,

Indian Hedgehog), and GAGs play a major role in the regulation of these signaling pathways.^{27,28} Second, bone remodeling and growth are based on the ossification of cartilage, which is disturbed as a result of the malfunction of chondrocytes containing accumulated GAGs and altered cathepsin K activity (Figure 2).²⁹ This is supported by the presence of nonossified cartilaginous precursors in bones of MPS patients.^{30,31} Cartilage is avascular and, thus, receives nutrients via diffusion.³² Enzyme delivery from the circulation will most likely also occur via diffusion. The distance that enzymes have to overcome in bone and articular cartilage is large; therefore, ossification continues to be impaired. Third, GAG accumulation stimulates secondary pathophysiological processes in ECM, like inflammation, contributing to osteopenia and the abnormal shape of bones seen in MPS patients.³³ Finally, abnormal weight-bearing forces influence the morphology of bone structures.^{34,35} Malformations in these structures that are already present before HCT alter the forces between them and contribute to further progression of hip dysplasia. Progression of hip deformations also influences the progression of genu valgum.^{36,37} Importantly, many of these malformations already start to develop in utero.

In conclusion, many bone defects have already developed at the time of diagnosis and start of treatment as a result of abnormal ossification, lack of bone remodeling, inflammation, and abnormal forces. Posttreatment with HCT or ERT, enzyme availability continues to be insufficient in the avascular diffusion-dependent cartilage. Ongoing alterations in growth factor signaling pathways and inflammation may play additional roles in the changes in chondrogenesis and bone growth.³⁸

Joints, tendons, and ligaments. In all types of MPS, with the exception of MPS-4, GAG accumulation in ligaments, tendons, and joint capsules results in joint contractures.³⁹⁻⁴¹ Studies on joint stiffness post-HCT or post-ERT show conflicting outcomes.^{5,24,42-45} The joint capsule is a dense connective tissue layer that enhances

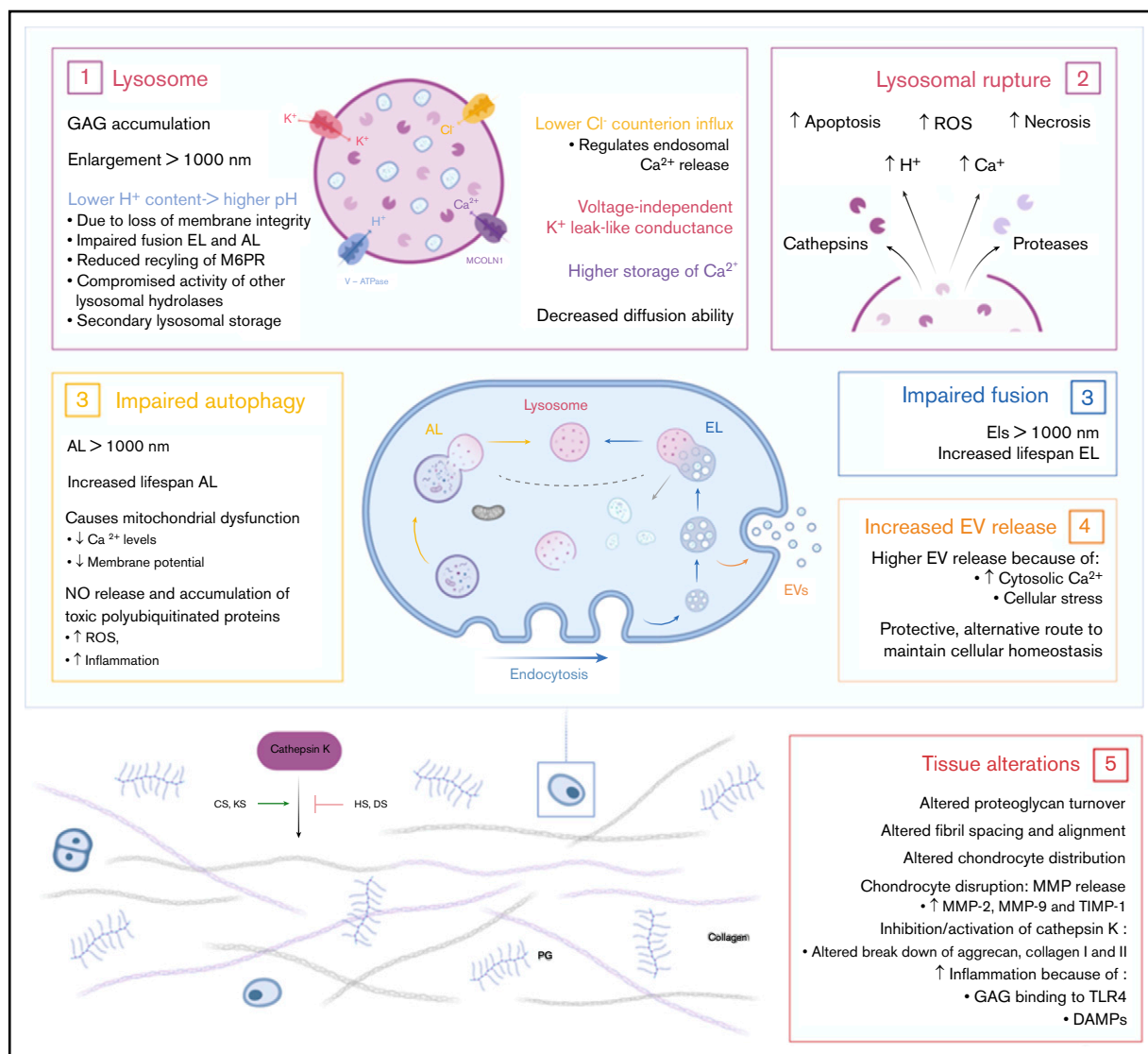


Figure 3. Effects of accumulated lysosomal products on cellular and tissue homeostasis. (1) Accumulation of GAGs in the lysosome leads to enlargement of the lysosome, followed by a loss of membrane integrity. Leakage of H^+ out of the lysosome results in a higher pH and may lead to compromised activity of lysosomal hydrolases and secondary lysosomal storage. Furthermore, the higher pH results in impaired fusion of endolysosomes and autolysosomes and a reduced recycling of the M6P receptor. Finally, enlarged lysosomes have decreased diffusion ability inside the cell. (2) Enlargement of the lysosome ultimately results in lysosomal rupture with the escape of cathepsins and proteases in the cell. Simultaneously, lysosomal rupture leads to increased concentration of H^+ and Ca^{2+} in the cytosol. Together, this results in increased reactive oxygen species (ROS) production, necrosis, and apoptosis of cells. (3) The dysfunctional lysosome leads to impaired autophagy and fusion with endolysosomes. Therefore, increased lifespans are seen for autolysosomes and endolysosomes. Impaired autophagy subsequently results in mitochondrial dysfunction. (4) The increased concentration of cytosolic Ca^{2+} and cellular stress stimulates the release of extracellular vesicles (EVs). This is an alternative protective route for the cell to maintain cellular homeostasis. (5) The accumulation of GAGs in the cell and the secondary affected mechanisms result in tissue alterations and destruction. Connective tissue is the most affected tissue in MPS patients. Studies show altered proteoglycan turnover, altered fibril spacing and alignment, and altered chondrocyte distribution and disruption leading to increased concentrations of matrix metalloproteinase-2 (MMP-2), MMP-9, and tissue inhibitor of metalloproteinase-1 (TIMP-1). Depending on the type of GAG, undegraded GAGs lead to inhibition or activation of cathepsin K, which is necessary for the degradation of aggrecan and collagen I and II. Finally, HS and cellular stress lead to inflammation via activation of the Toll-like receptor 4 (TLR4) pathway. DAMPs, damage associated molecular patterns.

joint security and bone placement; it may also extend into the joint to form a fibrocartilaginous articular disc or meniscus. Normally, the capsule contains blood vessels, but altered forces can drive this tissue into a more fibrocartilage type that becomes much less vascularized. In this process, increases in collagen type II, KS, DS, and chondroitin sulfate are seen.⁴⁶ As a consequence, changes in fibril arrangement, spacing, and size occur, which are destructive for

tendons and ligaments; proper fibril arrangement is pivotal to create functional structures. In addition to joint contractions, weakening of the tendons is seen, which explains, in part, the thoracolumbar kyphosis.⁴⁷ The skeletal malformations, in combination with weakening of the tendons, can also lead to neck instability and, together, complicate anesthetic airway management in patients.⁴⁸ Furthermore, carpal tunnel syndrome, caused by median nerve constriction

Table 1. Enzyme deficiencies, storage material, and clinical manifestations of the different MPS types

Type	Eponym	Enzyme deficiency	Deposited GAGs (secondary)	Clinical manifestations before HCT
I	Hurler* Hurler/Scheie Scheie	α -L-iduronidase	DS HS (KS)	Coarse facies, short stature, dysostosis multiplex, joint stiffness, spinal cord compression, organomegaly, corneal clouding, retinal degeneration, hearing loss, cardiac/respiratory disease, mental retardation in severe phenotype
II	Hunter	Iduronate-2-sulfatase	DS HS (KS)	Coarse facies, short stature, dysostosis multiplex, joint stiffness, spinal cord compression, organomegaly, corneal clouding, retinal degeneration, cardiac/respiratory disease, mental retardation
III-A	Sanfilippo A	Heparan <i>N</i> -sulfatase	HS (KS)	Severe mental impairment, aggressive behavior, sleep disturbances and dementia, relatively mild somatic symptoms, corneal clouding, respiratory disease, hearing loss
III-B	Sanfilippo B	α - <i>N</i> -acetylglucosaminidase		
III-C	Sanfilippo C	Acetyl-coa- α -glucosaminide Acetyltransferase		
III-D	Sanfilippo D	<i>N</i> -acetylglucosamine 6-sulfatase		
IV-A	Morquio type A	Galactosamine-6-sulfatase	KS C6S	Short stature, ligamentous laxity, joint hypermobility, dysostosis multiplex, corneal clouding, hearing loss, cardiac disease
IV-B	Morquio type B	β -Galactosidase	KS	
VI	Maroteaux-Lamy	<i>N</i> -acetylgalactosamine 4-sulfatase	DS C4S (KS)	Coarse facies, short stature, dysostosis multiplex, joint stiffness, odontoid hypoplasia, kyphoscoliosis, genu valgum, organomegaly, corneal clouding and cardiac/respiratory disease; no mental impairment
VII	Sly	β -glucuronidase	HS DS C4S C6S (KS)	Coarse facies, short stature, dysostosis multiplex, joint stiffness, spinal cord compression, odontoid hypoplasia, organomegaly, cardiac disease, corneal clouding and mild mental impairment
IX	Natowicz	Hyaluronidase	HA	Short stature, polyarthropathy, periarticular soft tissue masses with painful swelling and acetabular erosion

*Within MPS-1, there is a phenotype spectrum ranging from the severe Hurler phenotype to the mild Scheie phenotype.

in the wrist due to GAG deposition in the transverse carpal ligament, occurs in 89% of patients, despite HCT. Also, trigger digits, caused by GAG deposition in the flexor tendons, are frequently observed, despite treatment.^{24,49-52}

Thus, GAGs accumulate in ligaments, tendons, and joint capsules, despite current treatments. These tissues have in common that they are avascular connective tissues. Hence, they rely on diffusion of enzyme from the circulation after treatment with HCT or ERT, which is even more challenging in the case of ERT, because of the intermittent availability of enzyme with high peaks of enzyme in plasma for only a short duration. Moreover, most of these structures consist of dense connective tissue in which diffusion of nutrients is even more difficult, and the arrangement of the structure is highly important. This likely explains the poor efficacy of current systemic treatments.

Corneal clouding. Progression of corneal clouding is observed posttreatment with HCT or ERT.^{5,53-55} The cornea, a transparent avascular connective tissue, consists of epithelial and endothelial cells, keratocytes, collagen, and PGs.⁵⁶ GAG accumulation affects the size of keratocytes and disrupts the regular network of the stroma, resulting in abnormal arrangement, spacing, and size of collagen fibrils.^{57,58} Tear fluid could potentially be the supplier of donor enzyme after HCT. However, enzyme activity in tear fluid of MPS-1 patients after HCT remains low, despite normalization in the circulation, insinuating poor enzyme penetration.⁵⁵

Heart valves. Although disease manifestations in the coronary arteries and the heart muscle are effectively addressed following HCT, and partially for ERT, the mitral and aortic valve deformities, persist. In some, this may lead to progressive valvular dysfunction.^{5,59,60} The heart valves contain a highly specialized and organized ECM in which the alignment of collagen fibers is extremely important.⁶¹ GAG accumulation leads to abnormal fibril organization and weakening of valvular connective tissue as a result of decreased stiffness and increased extensibility, which have been associated with valvular prolapse.⁶²⁻⁶⁵ Similar to other avascular connective tissues, valvular disease progression is likely due to enzyme shortage.

Disease progression unrelated to connective tissue

Retinal degeneration. Despite successful HCT, degeneration of the vascularized retina continues.⁵³ This is likely explained by the blood-retina barrier (BRB), which hampers adequate enzyme delivery to the retina. Kaneko et al⁶⁶ used enhanced green fluorescent protein–positive bone marrow cells in mice to study whether donor cells end up in the retina after HCT. They compared damaged retinas (induced by injection of *N*-methyl-*N*-nitrosourea or creation of retinal detachment) with normal retinas and found that only a minute number of donor cells end up in uninjured retinas of mice up to 12 months following HCT. However, damaged retinas showed massive recruitment of donor-derived cells into the retina.⁶⁶ Whether retinas of MPS patients show similar damage and, thus,

recruit donor-derived macrophages after HCT to produce enzyme locally warrants further investigation.

Taken together, we propose that “hard-to-treat” tissues in MPS are actually “hard-to-reach” tissues for which 2 major hurdles need to be addressed: overcoming avascular zones and blood-tissue barriers. Poorly vascularized tissues are dependent on diffusion of the enzyme from the circulation, which can pose a significant hurdle if the distance is too large or the tissue is very dense. An advantage of HCT is its ability to allow monocytes to migrate to the brain and, thus, pass the BBB, suggesting that this physiological barrier is overcome. However, MPS-3 patients, in whom central nervous system symptoms predominate, deteriorate despite HCT.⁶⁷ The predominant accumulating GAG in MPS-3 is HS, which plays an important role in the brain. Speculatively, the central nervous system of these patients may require an amount of enzyme that, apparently, is not provided by HCT. Furthermore, progression of retinal degeneration insinuates that the effect of therapy is still inhibited by the BRB. Therefore, we propose that additional local therapies or therapies that enhance transport of systemic available enzyme to connective tissues or tissues isolated from the circulation because of a specific barrier could help to improve long-term outcomes in MPS patients.

Toward treating “hard-to-reach” tissues

Based on the general considerations above, alternative approaches for enzyme delivery to “hard-to-reach” tissues have been proposed. These include, in order of their proximity to clinical use, gene therapy (GT), direct local administration, small molecule therapies, targeted enzyme-delivery systems, mesenchymal stem cell therapy, and focused ultrasound therapy.

Gene therapy

GT is currently the most advanced experimental therapy. Viral GT has been studied widely; however, nonviral strategies have been explored as well.

Viral GTs. Viral GT in MPS has been explored using retroviruses, lentiviruses, and adeno-associated viruses.⁶⁸ Because of the risk of mutagenesis when using retroviruses, research now focuses mainly on lentiviruses and adeno-associated viruses. Ex vivo LV GT is used in combination with autologous stem cell therapy, aiming for supraphysiological enzyme activity levels in the circulation, with the rationale to improve penetration in poor responding tissues, of which animal studies have shown better correction of the bones and brain.⁶⁹⁻⁷¹ Autologous gene-modified HCT is being studied in a clinical trial for MPS-1 (NCT03488394) and for MPS-3A (NCT04201405) and is being developed for MPS-3B. An important advantage of autologous stem cell GT is reduced morbidity and mortality as a result of the absence of graft failure and graft-versus-host-disease, as well as the reduced toxicity of immunosuppressive medication.⁷² However, it is still unknown whether patients develop antibodies against the enzyme that could subsequently reduce the effect of therapy. Although the initial results are promising, it is still an open question whether greater hematologically available enzyme is able to overcome the diffusion distances in poorly responding avascular tissues and completely cure MPS. In addition to gene-modified autologous HCT, direct administration of GT is being studied and is addressed in “Direct local administration.”

Nonviral GTs. A nonviral GT strategy is the Sleeping Beauty (SB) transposons.⁷³ SB transposons consist of a system using 2 plasmids: 1 containing the internal sequence for the system, the inverted terminal repeat (ITR) and the gene of interest, and the other 1 containing the SB transposase that recognizes the ITR to ensure translocation of the gene into the genome. The SB strategy was studied in MPS-1 mice and showed efficacy in most, but not all (ie, kidney, heart, and aorta), somatic organs. The central nervous system also was not treated with the SB transposons. Therefore, the SB strategy is not yet sufficient for the treatment of MPS.⁷⁴

Direct local administration

To overcome avascularity of tissues and blood-tissue barriers, local (intra-articular) administration of recombinant enzyme has been studied in MPS-1 and MPS-6 animal models.⁷⁵⁻⁷⁷ By injecting the recombinant enzyme directly into the joint cavity of MPS-6 cats, obvious histological improvements were consistently detectable. Following treatment, clearance of lysosomal storage in synovial cells and chondrocytes was seen. Joints that received recombinant enzyme had improved thickness of cartilage, fewer cartilage lesions, better overall joint shape, healthy well-vascularized subchondral bone, and improved synovium compared with the contralateral buffer-treated joints. These encouraging results have led to the treatment of 2 MPS-6 patients with monthly intra-articular injections in the hips for 2 years.⁷⁶ However, the results have yet to be published. Wang et al⁷⁷ found similar results for intra-articular recombinant enzyme in MPS-1 dogs. Administration into intra-articular spaces resulted in reduction of GAG storage in the synovium and chondrocytes in the articular surface of the joint cartilage, as well as in chondrocytes further away from the articular surface.

Major disadvantages of injecting recombinant enzyme are the need for repeated injections, and, possibly, the risk of antibody formation. Vance et al⁷⁸ explored AAV-mediated GT for enzyme delivery by intrastromal injection as an effective treatment for MPS-1–related corneal clouding. Seven days after injection of an AAV8G9-optimized enzyme construct in human corneas, the enzyme was overproduced in the corneal stroma with widespread distribution in multiple cell types, as well as a 10-fold increase in enzyme activity without any indications of toxicity.⁷⁸ Furthermore, AAV-mediated GT directly administered into the brain was successful in animals⁷⁹⁻⁸¹ and resulted in clinical trials that are currently open for MPS-1 (NCT03580083), MPS-2 (NCT03566043), and MPS-3A (NCT03612869 and NCT02716246).

Small-molecule therapies

Alternative strategies that overcome the transport obstacles aim to improve enzyme activity locally or decrease the workload of the faulty enzyme.

An estimated 70% of severe MPS phenotypes are caused by premature stop-codon mutations.⁸² Therefore, stop-codon read-through therapy could be a promising approach; however, most of the well-known drugs with read-through effects, such as gentamycin (an aminoglycoside) and chloramphenicol, are toxic. Therefore, a less toxic derivate was constructed (NB84). The results of a phase 1 clinical trial with the synthetic version of NB84, ELX-02, showed an acceptable safety profile in healthy adults⁸³; however, clinical efficacy in MPS patients has yet to be proven. PTC-124 is a nonaminoglycoside stop-codon read-through therapy compound.

Although promising results for PTC-124 were seen in MPS mouse models, an open-label clinical phase 2 trial was ended early because of low enrolment (European Union Drug Regulating Authorities Clinical Trials Database number 2014-002596-28). No conclusions could be drawn about its effect.

Substrate reduction or optimization therapy. Molecules that reduce the synthesis of GAGs, such as genistein and rhodamine B, are a subject of research in MPS-1, MPS-2, and MPS-3.⁸⁴⁻⁸⁶ A pilot study in MPS-3 patients showed that genistein was safe, reduced urine GAG concentration, and arrested behavioral and cognitive deficits.⁸⁷ A phase 3 study of genistein in MPS-3 patients was completed in 2018; however, the results have yet to be published (European Union Drug Regulating Authorities Clinical Trials Database number 2013-001479-18). In MPS-2 patients, genistein improved joint and connective tissue elasticity.⁸⁸ In addition to substrate-reduction therapies, substrate optimization therapy has been applied. Substrate optimization therapy includes compounds that alter the accumulating substrate to make it more amenable to degradation by other enzymes. In vitro studies showed that modified GAGs were indeed more susceptible to degradation in fibroblasts, and the therapy is currently being developed for MPS-1.^{89,90}

Chaperone therapy. Chaperones are small proteins that aid in the correct folding of enzymes, leading to increased residual enzyme activity.⁹¹ In vitro experiments on several MPS 3B- and 3C-causing mutations indicated that pharmaceutical chaperones can bind and stabilize mutant enzymes and improve their enzymatic activity. Thus, the use of pharmaceutical chaperones to alter enzyme activity might be plausible, especially for those mutations that cause abnormal glycosylation patterns.⁹¹

Small-molecule therapies show promising results in vitro; however, their in vivo efficacy has yet to be proven in clinical trials. Because most compounds are smaller than 50 kilodaltons, they are able to cross the BBB and, possibly, the BRB. Although not suitable as general standard therapies, they could be helpful in achieving better clinical outcomes in specific mutations seen in MPS patients.

Targeted enzyme delivery systems

Targeted drug delivery seeks to concentrate the medication in the tissues of interest and can potentially improve drug delivery in avascular tissues or isolated tissues because of a blood-tissue barrier. Two types of targeted enzyme delivery systems have been studied in recent years: a so-called “Trojan horse strategy” and a nano-targeted delivery route.

Trojan horse strategy. The Trojan horse strategy entails the use of fusion proteins to cross a therapeutic over a specific barrier.⁹² The therapeutic part of the fusion protein can be conjugated to a monoclonal antibody against a tissue-specific target-receptor or to an endogenous ligand for natural binding to the receptor.⁹³ In MPS, fusion proteins have mainly been studied to cross the BBB via the receptors of transferrin, insulin, low-density lipoprotein, or lectin and were demonstrated to create higher yields of enzyme in the brain.⁹⁴⁻⁹⁸ Targeted delivery of drugs to bones with the use of a hydroxyapatite-binding site or alendronate (a drug with a high affinity for bone) has been investigated for several bone diseases and shows promising results in vitro.⁹⁹ In vivo efficacy has yet to be proven. This approach has not been studied for MPS, but it

could be a strategy to get the deficient enzyme into the cartilage and bone and possibly achieve a better clinical response.

Nano-targeted delivery. Nano-therapy has been proposed for gene products and direct enzyme delivery and offers promising therapeutic methods in lysosomal storage diseases.^{100,101} It uses different strategies, including micelles, liposomes, nano-emulsions, or nanoparticles. The choice of which biomaterial is used depends on the biochemicals of the desired drug.¹⁰⁰ Nano-targeted delivery of enzyme might be specifically interesting for the treatment of bone and cartilage disease in MPS patients. Wang et al¹⁰² created a liposome specific for hydroxyapatite, which binds with a high affinity to collagen-hydroxyapatite compositions in vitro. This suggests the possibility of using mineral-targeted ligands in nanoparticles for the delivery of lysosomal enzymes to mineralized tissues. Bidone et al¹⁰³ studied intra-articular administration of cationic nano-emulsions complexed with a plasmid encoding for the IDUA protein. They demonstrated the localization of the nano-emulsion in synovial joints, cellular uptake by synoviocytes, high cell viability, and a 10-fold increase in IDUA expression in the joint 48 hours after injection. IDUA activity was increased fivefold in synovial fluid and 20-fold in synovial joints.¹⁰³

Mesenchymal stem cell therapy and extracellular vesicles

Bone marrow, in addition to HSCs, contains mesenchymal stem cells (MSCs). MSCs are multipotent stromal cells that are characterized by their intrinsic self-renewal capacity and ability to differentiate into cells of the mesenchymal lineage, including osteoblasts and chondrocytes.^{104,105} They are important in tissue homeostasis and regeneration because of their immunomodulatory potential and release of trophic factors;¹⁰⁶ however, direct infusion of expanded MSCs leads to entrapment in the lungs and rapid clearance by the spleen.¹⁰⁷ Furthermore, several studies have shown that MSCs do not engraft after infusion; thus, the effect is only temporary.¹⁰⁷ However, recent studies indicate that extracellular vesicles (EVs) are mainly responsible for the positive effects of MSCs.¹⁰⁸ EVs are small endosome-derived lipid nanoparticles (40-500 nm) that play an important role in intercellular trafficking.¹⁰⁹ Because of their very small size, they are interesting for the delivery of enzyme to avascular or blood-tissue barrier-isolated tissues. EVs can carry macromolecules, including enzymes, to adjacent cells.¹¹⁰ Although literature on EVs in metabolic diseases is scarce, EVs are known to contain lysosomal proteins.¹¹¹ Furthermore, transplantation of MSCs in the cornea of MPS-3 and MPS-7 mice showed that cross-correction of the deficient cells was indeed mediated by EVs and corrected GAG accumulation.^{111,112} Thus, EVs from MSCs could potentially deliver enzyme to deficient cells.

Focused ultrasound therapy

In the past years, ultrasound contrast agents have been used in diagnostic ultrasound imaging.¹¹³ They can also carry drugs or genes to select targeted tissues and cells for treatment or transfection.¹¹⁴ The mechanism behind (focused) ultrasound therapy relies on the administration of microbubbles. These microbubbles are lipid- or protein-containing shells filled with a heavy gas. The use of ultrasonic pressure waves on microbubbles causes them to collapse, resulting in a local widening of endothelial tight junctions, called sonoporation.¹¹⁵ Sonoporation causes temporary disruption of,

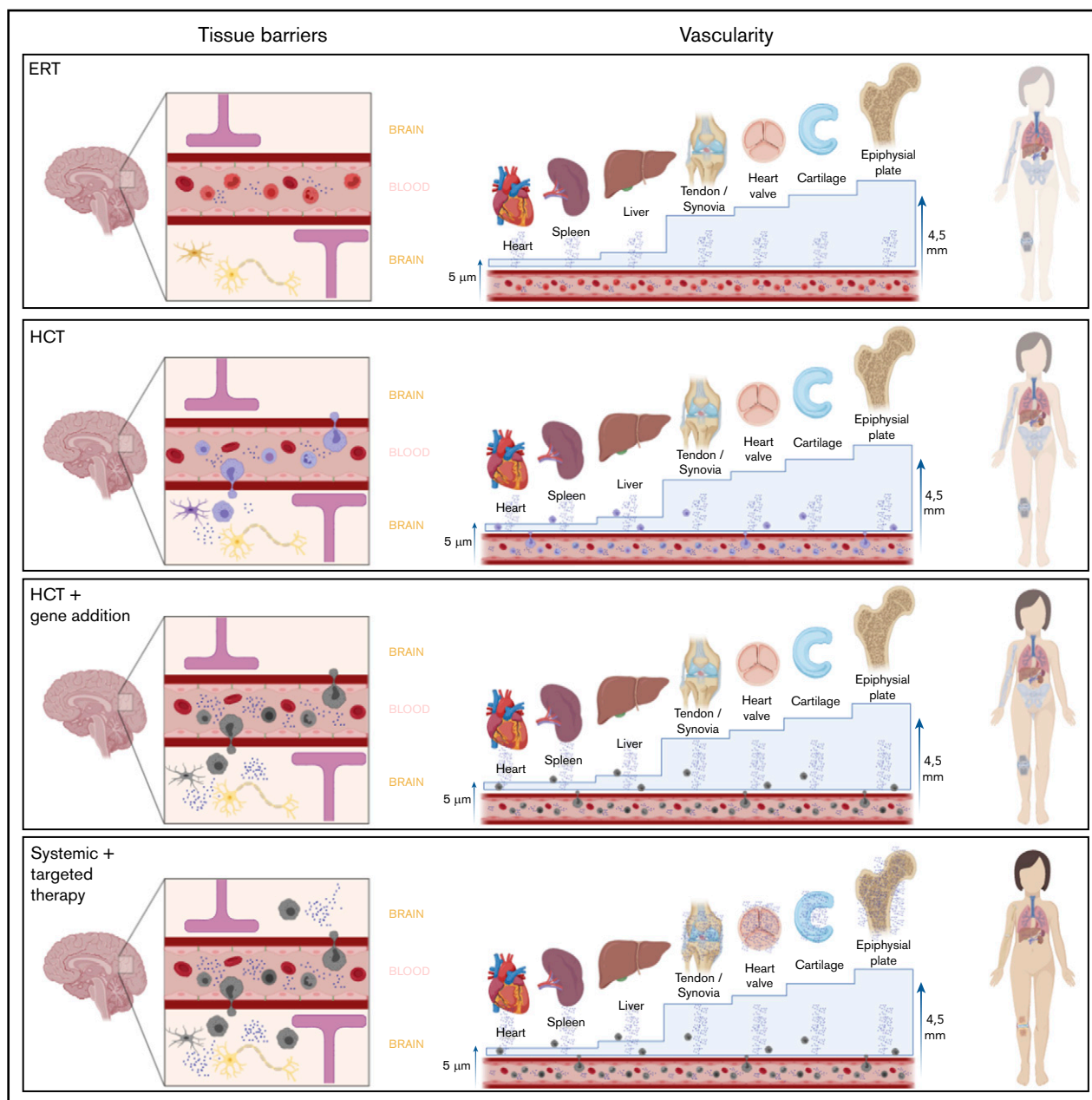


Figure 4. Overview of different therapy strategies on the 2 major hurdles in MPS. Patients treated with current standard treatments, ERT and HCT, still experience significant disease progression. Two major hurdles in the failure of these treatments in specific tissues are the presence of a physical barrier, such as the BBB or the BRB, and the vascularity of the tissue. Connective tissues, in which most disease progression is seen and which are avascular, are isolated from the circulation. Thus, they completely depend on diffusion of monocytes and free enzyme. For the epiphyseal plate for instance, the distance to overcome is 4.5 mm, which is too far; therefore, enzyme availability in the epiphyseal plate is still zero, despite treatment. Only increasing the available amount of enzyme in the circulation, like in the GT strategies, will most likely not solve this problem. Furthermore, it is unknown whether monocytes migrate past the BRB into the retina like it is assumed in the central nervous system. Progression of retinal degeneration insinuates that the available amount of enzyme is insufficient, at the least. Therefore, the route to cure MPS disease is to focus on increasing enzyme availability in these “hard-to-reach” tissues.

for example, the BBB.¹¹⁶ As a consequence, larger molecules up to 2000 kilodalton are able to pass through the BBB.¹¹⁷ The disturbance in the BBB leads to an increased drug concentration in the brain, as already demonstrated in several disease models, including the delivery of recombinant human IDUA in the case of MPS-1 mice.¹¹⁸

Ultrasound therapy has also been investigated to deliver drugs past the BRB. Using a rat model, Park et al¹¹⁹ demonstrated that burst ultrasound, together with a microbubble agent, was able to induce transient increases in retinal vascular permeability for retinal drug delivery in rats without any significant side effects. The BRB appeared to be restored within a few hours, which provided

a suitable time window for ocular pharmaceutical agent delivery while avoiding undesired effects that may result from long-term BRB disruption. In light of this knowledge, focused ultrasound therapy could be especially interesting for cell therapies and GTs targeting the brain and retina, because it would create a 1-time temporary disruption of the BBB and BRB, which allows the product to enter the tissue of interest and, possibly, increase biodistribution.

Conclusions

ERT and HCT are not sufficient to cure MPS disorders. Therefore, the management of MPSs will most likely evolve from monotherapy into combination therapy. A combination of HCT or autologous gene-modified HCT with additional therapies, as mentioned above, could allow for successful and complete correction of the tissue deficiencies seen in MPS (Figure 4). We have summarized 2 important hurdles that explain disease progression in “hard-to-reach” tissues in MPS patients, avascularity and tissue-specific barriers; both lead to unavailability of enzyme. The majority of disease progression occurs in connective tissue because of its avascularity. Additionally, the presence of the BRB and BBB prevent current standard therapies from providing optimal correction. Because the 2 major hurdles presented in this review, avascularity and tissue-specific barriers, are not MPS specific, they can also be applied to other metabolic diseases in which systemic treatments are not sufficient to completely cure the disease. For example, HCT is attempted in, among other diseases, leukodystrophies, α -mannosidosis, fucosidosis, Niemann-Pick disease, Tay-Sachs disease, Pompe disease, and Gaucher disease with variable success.¹²⁰ The experimental therapies mentioned in this review that try to overcome these hurdles might also be explored in these metabolic diseases to achieve a complete treatment of the underlying disease. For MPS, autologous gene-modified HCT appears to be the most promising; although it is likely to lower disease burden, is unlikely to result in a complete cure for MPS. Based on the nature and characteristics of the different MPS subtypes, each might require a different and unique treatment strategy for successful outcomes. Of note, because part of the damage already occurs in utero, some tissues might even be

References

1. Fratantoni JC, Hall CW, Neufeld EF. Hurler and Hunter Syndromes: mutual correction of the defect in cultured fibroblasts. *Science*. 1968;162(3853):570-572.
2. Muenzer J. Overview of the mucopolysaccharidoses. *Rheumatology (Oxford)*. 2011;50(suppl 5):v4-v12.
3. Hobbs JR, Hugh-Jones K, Barrett AJ, et al. Reversal of clinical features of Hurler's disease and biochemical improvement after treatment by bone-marrow transplantation. *Lancet*. 1981;2(8249):709-712.
4. Concolino D, Deodato F, Parini R. Enzyme replacement therapy: efficacy and limitations. *Ital J Pediatr*. 2018;44(suppl 2):120.
5. Kuiper GA, Nijmeijer SCM, Roelofs MJM, van der Lee JH, Hollak CEM, Bosch AM. Limited data to evaluate real-world effectiveness of enzyme replacement therapy for mucopolysaccharidosis type I. *J Inher Metab Dis*. 2019;42(5):762-775.
6. Valayannopoulos V, Wijburg FA. Therapy for the mucopolysaccharidoses. *Rheumatology (Oxford)*. 2011;50(suppl 5):v49-v59.
7. Aldenhoven M, Jones SA, Bonney D, et al. Hematopoietic cell transplantation for mucopolysaccharidosis patients is safe and effective: results after implementation of international guidelines. *Biol Blood Marrow Transplant*. 2015;21(6):1106-1109.
8. Wang J, Luan Z, Jiang H, et al. Allogeneic hematopoietic stem cell transplantation in thirty-four pediatric cases of mucopolysaccharidosis—a ten-year report from the China Children Transplant Group. *Biol Blood Marrow Transplant*. 2016;22(11):2104-2108.
9. Eisengart JB, Rudser KD, Xue Y, et al. Long-term outcomes of systemic therapies for Hurler syndrome: an international multicenter comparison. *Genet Med*. 2018;20(11):1423-1429.

“out-of-reach.” Thus, newborn screening programs are extremely important to identify patients in an early disease state to prevent further irreversible damage. Finally, biomarkers related to the extent of residual disease or the secondary manifestations, such as impaired autophagy, increased apoptosis, and inflammation, are necessary to evaluate the effect of (new) therapies on “hard-to-reach” tissues, because in the end, “that’s where the money is.”

Acknowledgments

All figures were created with BioRender.com.

B.T.A.v.d.B. was supported by a research grant from the Sylvia Toth Charity Foundation (The Hague, The Netherlands) while working on this study.

B.T.A.v.d.B. is a PhD candidate at Utrecht University and this work is submitted in partial fulfillment of the requirements for the PhD.

The sponsors of this study are public or nonprofit organizations that support science in general. They had no role in gathering, analyzing, or interpreting the data.

Authorship

Contribution: B.T.A.v.d.B. conceptualized and designed the review and wrote the manuscript; J.v.D. and C.V.H. wrote and critically reviewed the manuscript; S.N. and J.J.B. designed the review and critically reviewed the manuscript; C.A.L. and N.V.-D. critically reviewed the manuscript; and P.M.v.H. conceptualized and designed the review, wrote the manuscript, and critically reviewed the manuscript.

Conflict-of-interest disclosure: The authors declare no competing financial interests.

ORCID profiles: B.T.A.v.d.B., 0000-0003-3208-0685; S.N., 0000-0003-3406-817X; J.J.B., 0000-0003-2232-6952.

Correspondence: Peter M. van Hasselt, Department of Pediatric Metabolic Diseases, Wilhelmina Children's Hospital, Internal mail number: KE.04.133.1, Lundlaan 6, 3584 EA Utrecht, The Netherlands; e-mail: p.vanhasselt@umcutrecht.nl.

10. Boelens JJ, Aldenhoven M, Purtil D, et al; Centre for International Blood and Marrow Research. Outcomes of transplantation using various hematopoietic cell sources in children with Hurler syndrome after myeloablative conditioning. *Blood*. 2013;121(19):3981-3987.
11. Boelens JJ, Rocha V, Aldenhoven M, et al; EUROCORD, Inborn Error Working Party of EBMT and Duke University. Risk factor analysis of outcomes after unrelated cord blood transplantation in patients with hurler syndrome. *Biol Blood Marrow Transplant*. 2009;15(5):618-625.
12. Gandhi NS, Mancera RL. The structure of glycosaminoglycans and their interactions with proteins. *Chem Biol Drug Des*. 2008;72(6):455-482.
13. Scott JE. Proteoglycan-fibrillar collagen interactions. *Biochem J*. 1988;252(2):313-323.
14. Toole BP. Glycosaminoglycans in morphogenesis. In: Hay ED, ed. *Cell Biology of Extracellular Matrix*, Boston, MA: Springer US; 1981:259-294.
15. Jackson RL, Busch SJ, Cardin AD. Glycosaminoglycans: molecular properties, protein interactions, and role in physiological processes. *Physiol Rev*. 1991;71(2):481-539.
16. Häcker U, Nybakken K, Perrimon N. Heparan sulphate proteoglycans: the sweet side of development. *Nat Rev Mol Cell Biol*. 2005;6(7):530-541.
17. Ruoslahti E. Brain extracellular matrix. *Glycobiology*. 1996;6(5):489-492.
18. Schwartz NB, Domowicz M. Chondrodysplasias due to proteoglycan defects. *Glycobiology*. 2002;12(4):57R-68R.
19. Fecarotta S, Gasperini S, Parenti G. New treatments for the mucopolysaccharidoses: from pathophysiology to therapy. *Ital J Pediatr*. 2018;44(suppl 2):124.
20. Clarke LA. The mucopolysaccharidoses: a success of molecular medicine. *Expert Rev Mol Med*. 2008;10:e1.
21. Oussoren E, Brands MMMG, Ruijter GJG, der Ploeg AT, Reuser AJ. Bone, joint and tooth development in mucopolysaccharidoses: relevance to therapeutic options. *Biochim Biophys Acta*. 2011;1812(11):1542-1556.
22. van der Linden MH, Kruyt MC, Sakkars RJB, de Koning TJ, Oner FC, Castelein RM. Orthopaedic management of Hurler's disease after hematopoietic stem cell transplantation: a systematic review. *J Inherit Metab Dis*. 2011;34(3):657-669.
23. Langereis EJ, den Os MM, Breen C, et al. Progression of hip dysplasia in mucopolysaccharidosis type I Hurler after successful hematopoietic stem cell transplantation. *J Bone Joint Surg Am*. 2016;98(5):386-395.
24. Aldenhoven M, Wynn RF, Orchard PJ, et al. Long-term outcome of Hurler syndrome patients after hematopoietic cell transplantation: an international multicenter study. *Blood*. 2015;125(13):2164-2172.
25. Miebach E, Church H, Cooper A, et al. The craniocervical junction following successful haematopoietic stem cell transplantation for mucopolysaccharidosis type I H (Hurler syndrome). *J Inherit Metab Dis*. 2011;34(3):755-761.
26. Taylor M, Khan S, Stapleton M, et al. Hematopoietic stem cell transplantation for mucopolysaccharidoses; past, present, and future. *Biol Blood Marrow Transplant*. 2019;25(7):e226-e246.
27. Gatto F, Redaelli D, Salvadè A, et al. Hurler disease bone marrow stromal cells exhibit altered ability to support osteoclast formation. *Stem Cells Dev*. 2012;21(9):1466-1477.
28. Habuchi H, Habuchi O, Kimata K. Sulfation pattern in glycosaminoglycan: does it have a code? *Glycoconj J*. 2004;21(1-2):47-52.
29. Wilson S, Hashamiyan S, Clarke L, et al. Glycosaminoglycan-mediated loss of cathepsin K collagenolytic activity in MPS I contributes to osteoclast and growth plate abnormalities. *Am J Pathol*. 2009;175(5):2053-2062.
30. Russell C, Henderson G, Jevon G, et al. Murine MPS I: insights into the pathogenesis of Hurler syndrome. *Clin Genet*. 1998;53(5):349-361.
31. Palmucci S, Attinà G, Lanza ML, et al. Imaging findings of mucopolysaccharidoses: a pictorial review. *Insights Imaging*. 2013;4(4):443-459.
32. Jackson AR, Gu WY. Transport properties of cartilaginous tissues. *Curr Rheumatol Rev*. 2009;5(1):40.
33. Kingma SDK, Wagemans T, IJlst L, et al. Altered interaction and distribution of glycosaminoglycans and growth factors in mucopolysaccharidosis type I bone disease. *Bone*. 2016;88:92-100.
34. Fairbank HAT. Congenital dislocation of the hip: with special reference to the anatomy. *Br J Surg*. 1930;17(67):380-416.
35. Masterson EL, Murphy PG, O'Meara A, Moore DP, Dowling FE, Fogarty EE. Hip dysplasia in Hurler's syndrome: orthopaedic management after bone marrow transplantation. *J Pediatr Orthop*. 1996;16(6):731-733.
36. Guo SJ, Zhou YX, Yang DJ, Yang XC. Lower-limb valgus deformity associated with developmental hip dysplasia. *Chin Med J (Engl)*. 2012;125(22):3956-3960.
37. Siffert RS. Patterns of deformity of the developing hip. *Clin Orthop Relat Res*. 1981;(160):14-29.
38. Opoka-Winiarska V, Jurecka A, Emeryk A, Tylki-Szymańska A. Osteoimmunology in mucopolysaccharidoses type I, II, VI and VII. Immunological regulation of the osteoarticular system in the course of metabolic inflammation. *Osteoarthritis Cartilage*. 2013;21(12):1813-1823.
39. Aldenhoven M, Sakkars RJB, Boelens J, de Koning TJ, Wulffraat NM. Musculoskeletal manifestations of lysosomal storage disorders. *Ann Rheum Dis*. 2009;68(11):1659-1665.
40. Pastores GM, Meere PA. Musculoskeletal complications associated with lysosomal storage disorders: Gaucher disease and Hurler-Scheie syndrome (mucopolysaccharidosis type I). *Curr Opin Rheumatol*. 2005;17(1):70-78.
41. Morishita K, Petty RE. Musculoskeletal manifestations of mucopolysaccharidoses. *Rheumatology*. 2011;50(suppl 5):v19-v25.
42. Aldenhoven M, Boelens JJ, de Koning TJ. The clinical outcome of Hurler syndrome after stem cell transplantation. *Biol Blood Marrow Transplant*. 2008;14(5):485-498.
43. Weisstein JS, Delgado E, Steinbach LS, Hart K, Packman S. Musculoskeletal manifestations of Hurler syndrome: long-term follow-up after bone marrow transplantation. *J Pediatr Orthop*. 2004;24(1):97-101.

44. Souillet G, Guffon N, Maire I, et al. Outcome of 27 patients with Hurler's syndrome transplanted from either related or unrelated haematopoietic stem cell sources. *Bone Marrow Transplant.* 2003;31(12):1105-1117.
45. Breider MA, Shull RM, Constantopoulos G. Long-term effects of bone marrow transplantation in dogs with mucopolysaccharidosis I. *Am J Pathol.* 1989; 134(3):677-692.
46. Ralphs JR, Benjamin M. The joint capsule: structure, composition, ageing and disease. *J Anat.* 1994;184(Pt 3):503-509.
47. Kuiper G-A, Langereis EJ, Breyer S, et al. Treatment of thoracolumbar kyphosis in patients with mucopolysaccharidosis type I: results of an international consensus procedure. *Orphanet J Rare Dis.* 2019;14(1):17.
48. Moretto A, Bosatra MG, Marchesini L, Tesoro S. Anesthesiological risks in mucopolysaccharidoses. *Ital J Pediatr.* 2018;44(suppl 2):116.
49. Yuen A, Dowling G, Johnstone B, Kornberg A, Coombs C. Carpal tunnel syndrome in children with mucopolysaccharidoses. *J Child Neurol.* 2007;22(3): 260-263.
50. Aslam R, Hendriks CJ, Jester A. Objective results of median nerve decompression and tenosynovectomy for carpal tunnel syndrome in patients with mucopolysaccharidoses types I and II. *J Hand Surg Eur Vol.* 2015;40(2):216-218.
51. Van Heest AE, House J, Krivit W, Walker K. Surgical treatment of carpal tunnel syndrome and trigger digits in children with mucopolysaccharide storage disorders. *J Hand Surg Am.* 1998;23(2):236-243.
52. Viskochil D, Muenzer J, Guffon N, et al. Carpal tunnel syndrome in mucopolysaccharidosis I: a registry-based cohort study. *Dev Med Child Neurol.* 2017; 59(12):1269-1275.
53. Gullingsrud EO, Krivit W, Summers CG. Ocular abnormalities in the mucopolysaccharidoses after bone marrow transplantation. Longer follow-up. *Ophthalmology.* 1998;105(6):1099-1105.
54. Summers CG, Fahnehjelm KT, Pitz S, et al. Systemic therapies for mucopolysaccharidosis: ocular changes following haematopoietic stem cell transplantation or enzyme replacement therapy—a review. *Clin Exp Ophthalmol.* 2010;38:34-42.
55. van den Broek BTA, van Egmond-Ebbeling MB, Achterberg JA, et al. Longitudinal analysis of ocular disease in children with mucopolysaccharidosis I after hematopoietic cell transplantation. *Biol Blood Marrow Transplant.* 2020;26(5):928-935. 10.1016/j.bbmt.2019.11.025
56. Sugar J. Corneal manifestations of the systemic mucopolysaccharidoses. *Ann Ophthalmol.* 1979;11(4):531-535.
57. Alroy J, Haskins M, Birk DE. Altered corneal stromal matrix organization is associated with mucopolysaccharidosis I, III and VI. *Exp Eye Res.* 1999;68(5): 523-530.
58. Fahnehjelm KT, Ashworth JL, Pitz S, et al. Clinical guidelines for diagnosing and managing ocular manifestations in children with mucopolysaccharidosis. *Acta Ophthalmol.* 2012;90(7):595-602.
59. Braunlin EA, Stauffer NR, Peters CH, et al. Usefulness of bone marrow transplantation in the Hurler syndrome. *Am J Cardiol.* 2003;92(7):882-886.
60. Stauffer NR, Braunlin E, Whitley C, Krivit W, Bass J. Echocardiographic follow-up of Hurler syndrome after bone marrow transplantation. *Circulation.* 1991;84(suppl II):462a.
61. Hinton RB, Yutzy KE. Heart valve structure and function in development and disease. *Annu Rev Physiol.* 2011;73(1):29-46.
62. Cigliano A, Gandaglia A, Lepedda AJ, et al. Fine structure of glycosaminoglycans from fresh and decellularized porcine cardiac valves and pericardium. *Biochem Res Int.* 2012;2012:979351.
63. Barber JE, Kasper FK, Ratliff NB, Cosgrove DM, Griffin BP, Vesely I. Mechanical properties of myxomatous mitral valves. *J Thorac Cardiovasc Surg.* 2001; 122(5):955-962.
64. Grande-Allen KJ, Griffin BP, Ratliff NB, Cosgrove DM, Vesely I. Glycosaminoglycan profiles of myxomatous mitral leaflets and chordae parallel the severity of mechanical alterations. *J Am Coll Cardiol.* 2003;42(2):271-277.
65. Schoen FJ. Evolving concepts of cardiac valve dynamics: the continuum of development, functional structure, pathobiology, and tissue engineering. *Circulation.* 2008;118(18):1864-1880.
66. Kaneko H, Nishiguchi KM, Nakamura M, Kachi S, Terasaki H. Characteristics of bone marrow-derived microglia in the normal and injured retina. *Invest Ophthalmol Vis Sci.* 2008;49(9):4162-4168.
67. Welling L, Marchal JP, van Hasselt P, van der Ploeg AT, Wijburg FA, Boelens JJ. Early umbilical cord blood-derived stem cell transplantation does not prevent neurological deterioration in mucopolysaccharidosis type III. *JIMD Rep.* 2015;18:63-68.
68. Scarpa M, Orchard PJ, Schulz A, et al. Treatment of brain disease in the mucopolysaccharidoses. *Mol Genet Metab.* 2017;122S:25-34.
69. Macsai CE, Derrick-Roberts ALK, Ding X, et al. Skeletal response to lentiviral mediated gene therapy in a mouse model of MPS VII. *Mol Genet Metab.* 2012;106(2):202-213.
70. Wakabayashi T, Shimada Y, Akiyama K, et al. Hematopoietic stem cell gene therapy corrects neuropathic phenotype in murine model of mucopolysaccharidosis type II. *Hum Gene Ther.* 2015;26(6):357-366.
71. Derrick-Roberts ALK, Panir K, Pyragius CE, Zarinkalam KH, Atkins GJ, Byers S. Reversal of established bone pathology in MPS VII mice following lentiviral-mediated gene therapy. *Mol Genet Metab.* 2016;119(3):249-257.
72. Biffi A. Hematopoietic stem cell gene therapy for storage disease: current and new indications. *Mol Ther.* 2017;25(5):1155-1162.
73. Aronovich EL, Hackett PB. Lysosomal storage disease: gene therapy on both sides of the blood-brain barrier. *Mol Genet Metab.* 2015;114(2): 83-93.
74. Aronovich EL, Bell JB, Khan SA, et al. Systemic correction of storage disease in MPS I NOD/SCID mice using the sleeping beauty transposon system. *Mol Ther.* 2009;17(7):1136-1144.

75. Auclair D, Hopwood JJ, Lemontt JF, Chen L, Byers S. Long-term intra-articular administration of recombinant human N-acetylgalactosamine-4-sulfatase in feline mucopolysaccharidosis VI. *Mol Genet Metab*. 2007;91(4):352-361.
76. Auclair D, Ketteridge D, Oates S, Hopwood JJ, Byers S. An overview of intra-articular therapy for mucopolysaccharidosis VI. *J Pediatr Rehabil Med*. 2010; 3(1):3-6.
77. Wang RY, Aminian A, McEntee MF, et al. Intra-articular enzyme replacement therapy with rhIDUA is safe, well-tolerated, and reduces articular GAG storage in the canine model of mucopolysaccharidosis type I. *Mol Genet Metab*. 2014;112(4):286-293.
78. Vance M, Llanga T, Bennett W, et al. AAV gene therapy for MPS1-associated corneal blindness. *Sci Rep*. 2016;6(1):22131.
79. Belur LR, Temme A, Podetz-Pedersen KM, et al. Intranasal adeno-associated virus mediated gene delivery and expression of human iduronidase in the central nervous system: a noninvasive and effective approach for prevention of neurologic disease in mucopolysaccharidosis type I. *Hum Gene Ther*. 2017;28(7):576-587.
80. Hordeaux J, Hinderer C, Goode T, et al. Toxicology study of intra-cisterna magna adeno-associated virus 9 expressing human alpha-L-iduronidase in rhesus macaques. *Mol Ther Methods Clin Dev*. 2018;10:79-88.
81. Hordeaux J, Hinderer C, Buza EL, et al. Safe and sustained expression of human iduronidase after intrathecal administration of adeno-associated virus serotype 9 in infant rhesus monkeys. *Hum Gene Ther*. 2019;30(8):957-966.
82. Khan SA, Peracha H, Ballhausen D, et al. Epidemiology of mucopolysaccharidoses. *Mol Genet Metab*. 2017;121(3):227-240.
83. Leubitz A, Frydman-Marom A, Sharpe N, van Duzer J, Campbell KCM, Vanhoutte F. Safety, tolerability, and pharmacokinetics of single ascending doses of ELX-02, a potential treatment for genetic disorders caused by nonsense mutations, in healthy volunteers. *Clin Pharmacol Drug Dev*. 2019;8(8):984-994.
84. Jakóbkiewicz-Banecka J, Piotrowska E, Narajczyk M, Barańska S, Wegrzyn G. Genistein-mediated inhibition of glycosaminoglycan synthesis, which corrects storage in cells of patients suffering from mucopolysaccharidoses, acts by influencing an epidermal growth factor-dependent pathway. *J Biomed Sci*. 2009;16(1):26.
85. Roberts ALK, Thomas BJ, Wilkinson AS, Fletcher JM, Byers S. Inhibition of glycosaminoglycan synthesis using rhodamine B in a mouse model of mucopolysaccharidosis type IIIA. *Pediatr Res*. 2006;60(3):309-314.
86. Derrick-Roberts ALK, Jackson MR, Pyragius CE, Byers S. Substrate deprivation therapy to reduce glycosaminoglycan synthesis improves aspects of neurological and skeletal pathology in MPS I mice. *Diseases*. 2017;5(1):E5.
87. Piotrowska E, Jakóbkiewicz-Banecka J, Maryniak A, et al. Two-year follow-up of Sanfilippo disease patients treated with a genistein-rich isoflavone extract: assessment of effects on cognitive functions and general status of patients. *Med Sci Monit*. 2011;17(4):CR196-CR202.
88. Marucha J, Tyłki-Szymańska A, Jakóbkiewicz-Banecka J, et al. Improvement in the range of joint motion in seven patients with mucopolysaccharidosis type II during experimental gene expression-targeted isoflavone therapy (GET IT). *Am J Med Genet A*. 2011;155A(9):2257-2262.
89. Kirkegaard T. Emerging therapies and therapeutic concepts for lysosomal storage diseases. *Expert Opin Orphan Drugs*. 2013;1(5):385-404.
90. Brown J, Brown JR, Carroll R, Glass C, Crawford BE. 22. Small molecule inhibitors of glycosaminoglycan biosynthesis as substrate optimization therapy for the mucopolysaccharidoses. *Mol Genet Metab*. 2010;2(99):S12.
91. Feldhammer M, Durand S, Pshezhetsky AV. Protein misfolding as an underlying molecular defect in mucopolysaccharidosis III type C. *PLoS One*. 2009; 4(10):e7434.
92. Boado RJ. A new generation of neurobiological drugs engineered to overcome the challenges of brain drug delivery. *Drug News Perspect*. 2008;21(9): 489-503.
93. Boado RJ, Zhou Q-H, Lu JZ, Hui EK-W, Pardridge WM. Pharmacokinetics and brain uptake of a genetically engineered bifunctional fusion antibody targeting the mouse transferrin receptor. *Mol Pharm*. 2010;7(1):237-244.
94. Boado RJ, Pardridge WM. Brain and organ uptake in the rhesus monkey in vivo of recombinant iduronidase compared to an insulin receptor antibody-iduronidase fusion protein. *Mol Pharm*. 2017;14(4):1271-1277.
95. Hersom M, Helms HC, Pretzer N, et al. Transferrin receptor expression and role in transendothelial transport of transferrin in cultured brain endothelial monolayers. *Mol Cell Neurosci*. 2016;76:59-67.
96. Böckenhoff A, Cramer S, Wölte P, et al. Comparison of five peptide vectors for improved brain delivery of the lysosomal enzyme arylsulfatase A. *J Neurosci*. 2014;34(9):3122-3129.
97. Wang D, El-Amouri SS, Dai M, et al. Engineering a lysosomal enzyme with a derivative of receptor-binding domain of apoE enables delivery across the blood-brain barrier. *Proc Natl Acad Sci USA*. 2013;110(8):2999-3004.
98. El-Amouri SS, Dai M, Han J-F, Brady RO, Pan D. Normalization and improvement of CNS deficits in mice with Hurler syndrome after long-term peripheral delivery of BBB-targeted iduronidase. *Mol Ther*. 2014;22(12):2028-2037.
99. Farrell KB, Karpeisky A, Thamm DH, Zinnen S. Bisphosphonate conjugation for bone specific drug targeting. *Bone Rep*. 2018;9:47-60.
100. Schuh RS, Baldo G, Teixeira HF. Nanotechnology applied to treatment of mucopolysaccharidoses. *Expert Opin Drug Deliv*. 2016;13(12):1709-1718.
101. Tomatsu S, Alméciga-Díaz CJ, Montaña AM, et al. Therapies for the bone in mucopolysaccharidoses. *Mol Genet Metab*. 2015;114(2):94-109.
102. Wang G, Mostafa NZ, Incani V, Kucharski C, Uludağ H. Bisphosphonate-decorated lipid nanoparticles designed as drug carriers for bone diseases. *J Biomed Mater Res A*. 2012;100(3):684-693.
103. Bidone J, Schuh RS, Farinon M, et al. Intra-articular nonviral gene therapy in mucopolysaccharidosis I mice. *Int J Pharm*. 2018;548(1):151-158.
104. Pittenger MF, Mackay AM, Beck SC, et al. Multilineage potential of adult human mesenchymal stem cells. *Science*. 1999;284(5411):143-147.

105. Jiang Y, Jahagirdar BN, Reinhardt RL, et al. Pluripotency of mesenchymal stem cells derived from adult marrow [published correction appears in *Nature*. 2007;447(7146):879-880]. *Nature*. 2002;418(6893):41-49.
106. Le Blanc K. Immunomodulatory effects of fetal and adult mesenchymal stem cells. *Cytotherapy*. 2003;5(6):485-489.
107. Karp JM, Leng Teo GS. Mesenchymal stem cell homing: the devil is in the details. *Cell Stem Cell*. 2009;4(3):206-216.
108. Mendt M, Rezvani K, Shpall E. Mesenchymal stem cell-derived exosomes for clinical use. *Bone Marrow Transplant*. 2019;54(suppl 2):789-792.
109. Gurunathan S, Kang M-H, Jeyaraj M, Qasim M, Kim J-H. Review of the isolation, characterization, biological function, and multifarious therapeutic approaches of exosomes. *Cells*. 2019;8(4):307.
110. Lema DA, Burlingham WJ. Role of exosomes in tumour and transplant immune regulation. *Scand J Immunol*. 2019;90(5):e12807.
111. Coutinho MF, Prata MJ, Alves S. A shortcut to the lysosome: the mannose-6-phosphate-independent pathway. *Mol Genet Metab*. 2012;107(3):257-266.
112. Coulson-Thomas VJ, Caterson B, Kao WW-Y. Transplantation of human umbilical mesenchymal stem cells cures the corneal defects of mucopolysaccharidosis VII mice. *Stem Cells*. 2013;31(10):2116-2126.
113. Casciari S, Conversano F, Ragusa A, et al. Optimal enhancement configuration of silica nanoparticles for ultrasound imaging and automatic detection at conventional diagnostic frequencies. *Invest Radiol*. 2010;45(11):715-724.
114. Wang Z, Wang Z. Treatment of ultrasound contrast agents for gene or drug delivery. *Zhongguo Jieru Yingxiang Yu Zhilixue*. 2006;4:
115. Bors LA, Erdő F. Overcoming the blood-brain barrier. Challenges and tricks for CNS drug delivery. *Sci Pharm*. 2019;87(1):6.
116. Burgess A, Hynynen K. Noninvasive and targeted drug delivery to the brain using focused ultrasound. *ACS Chem Neurosci*. 2013;4(4):519-526.
117. Horodyckid C, Canney M, Vignot A, et al. Safe long-term repeated disruption of the blood-brain barrier using an implantable ultrasound device: a multiparametric study in a primate model. *J Neurosurg*. 2017;126(4):1351-1361.
118. Hsu Y-H, Liu R-S, Lin W-L, Yuh Y-S, Lin S-P, Wong T-T. Transcranial pulsed ultrasound facilitates brain uptake of laronidase in enzyme replacement therapy for mucopolysaccharidosis type I disease. *Orphanet J Rare Dis*. 2017;12(1):109.
119. Park J, Zhang Y, Vykhodtseva N, Akula JD, McDannold NJ. Targeted and reversible blood-retinal barrier disruption via focused ultrasound and microbubbles. *PLoS One*. 2012;7(8):e42754.
120. Tan EY, Boelens JJ, Jones SA, Wynn RF. Hematopoietic stem cell transplantation in inborn errors of metabolism. *Front Pediatr*. 2019;7:433.