

Activity of brentuximab vedotin in AIDS-related primary effusion lymphoma

Victoria A. Chang,¹ Huan-You Wang,² and Erin G. Reid³

¹University of California, San Diego School of Medicine, La Jolla, CA; ²Department of Pathology, UC San Diego Health System, La Jolla, CA; and ³Division of Hematology/Oncology, UC San Diego Moores Cancer Center, La Jolla, CA

Key Points

- Brentuximab vedotin is active in primary effusion lymphoma, a rare CD30-positive lymphoma with an extremely poor prognosis.

Introduction

Primary effusion lymphoma (PEL) is a rare type of non-Hodgkin lymphoma presenting predominantly in body cavities, universally associated with Kaposi sarcoma-associated herpesvirus (KSHV)¹ and typically arising in the context of HIV infection. PEL carries a poor prognosis with a 10-month median survival.²⁻⁴

Data supporting optimal treatment strategies of PEL are limited due to the rarity of the disease. Anti-retroviral therapy (ART), combination chemotherapy with CHOP-derived regimens (cyclophosphamide, doxorubicin, vincristine or etoposide, and prednisone) with or without high-dose methotrexate² or bortezomib,⁵ antiviral treatment (valganciclovir⁶), and hematopoietic stem cell transplant are often used. Unfortunately, these therapies do not typically result in durable remission or cure.⁷⁻¹⁰

Monoclonal antibodies, including brentuximab vedotin (BV), have dramatically altered the landscape of lymphoma therapy. BV is a CD30-directed antibody-drug conjugate approved for use in Hodgkin lymphoma and CD30-expressing peripheral T-cell lymphomas and mycosis fungoides.¹¹ PEL, which also typically expresses CD30,¹² has been evaluated for response to BV in preclinical models. BV has been shown to have cytotoxic effects in PEL cell lines and to prolong the survival of mice bearing PEL tumors.¹² We herein provide the first reported clinical evidence supporting use of BV for PEL.

Case description

In this report, we describe 2 consecutive patients with AIDS and PEL who received BV after disease refractory to dose-adjusted EPOCH (da-EPOCH: etoposide, prednisone, vincristine, cyclophosphamide, doxorubicin); neither had a history of or concurrent involvement with other KSHV-associated conditions, including Kaposi sarcoma or multicentric Castleman disease. Following 2 cycles of BV, PEL remains in complete remission for over 39 months in patient A; a mixed response occurred in Patient B.

Methods

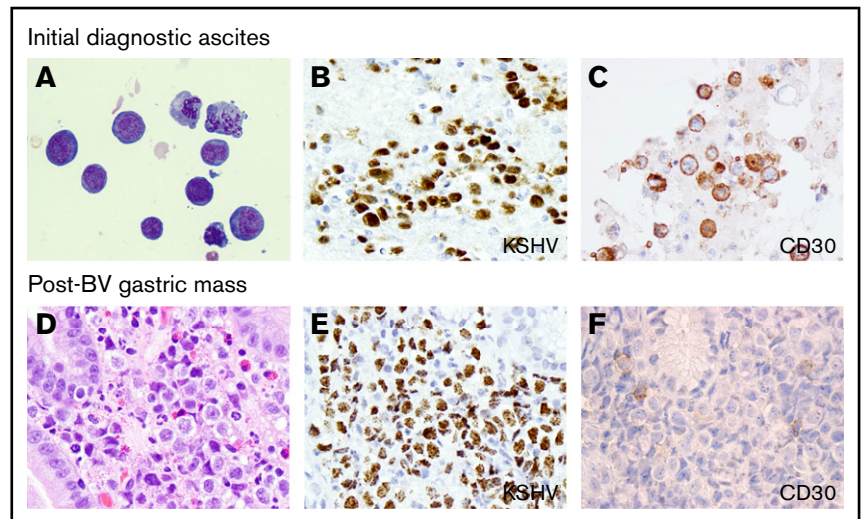
Patient A

A 53-year-old man with hepatitis B cirrhosis, splenomegaly, and thrombocytopenia presented with dyspnea, abdominal distension, and weight loss. Computed tomography (CT) imaging demonstrated ascites, large pericardial and pleural effusions, lymphadenopathy, and splenomegaly. Cytology from the ascites and pericardial fluid demonstrated many large atypical lymphoid cells with pleomorphic nuclei and brisk mitotic figures. These atypical cells were positive for CD45, CD30, CD38, and KSHV and negative for CD19, CD20, and CD138. Laboratory tests were notable for pancytopenia despite no bone marrow involvement, CD4-positive T-cell (CD4) count 62 per μL , and serum HIV 47 067 copies per mL. The patient was diagnosed with AIDS and stage IVB PEL.

ART and da-EPOCH were started with improvement in effusions and negative ascites cytology and flow cytometry after 1 cycle, but the course was complicated by thrombocytopenia with

Figure 1. Microphotographs of diagnostic PEL ascites and post BV-treated gastric biopsy from patient B.

Initial peritoneal fluid contained numerous large atypical lymphoid cells with irregular nuclear contours and conspicuous nucleoli (A; Diff-Quik, original magnification $\times 500$) with immunohistochemistry demonstrating expression of KSHV by LANA (B; original magnification $\times 400$), and CD30 (C; original magnification $\times 400$). The new gastric mass occurring posttreatment with BV (D; hematoxylin and eosin, original magnification $\times 400$) showed sheets of similar atypical large lymphoid cells expressing KSHV (E; original magnification $\times 400$) but without expression of CD30 (F; original magnification $\times 400$).



intracerebral hemorrhage resulting in hemiparesis. Once the patient was stabilized, da-EPOCH was resumed with platelet transfusion support to reduce the risk of bleeding. After cycle 4, CT revealed refractory disease with bilateral pleural effusions, stable ascites, and lymphadenopathy; recurrent PEL was confirmed on ascites cytology. Despite improved immune function (CD4 count 103 per μL , serum HIV undetectable), the patient's poor performance status precluded further combination chemotherapy.

Given the CD30 expression on the PEL cells, treatment with BV was initiated as a palliative measure. The patient received 2 doses of BV 1.8 mg/kg IV 3 weeks apart. After the first cycle, he developed uncomplicated pancytopenia supported with granulocyte colony stimulating factor, red blood cell, and platelet transfusions. Chest and abdominal CT performed 2 weeks after the second dose demonstrated resolution of ascites, abdominal lymphadenopathy, and pleural effusions. Additional doses of BV were held for prolonged neutropenia and thrombocytopenia. Two months later, CT and bone marrow examinations were consistent with continued complete remission (CR). Neutropenia subsequently resolved, and platelet counts improved above prelymphoma baseline.

Nineteen months after starting BV, new abdominal symptoms prompted a positron emission tomography (PET)/CT scan demonstrating low-level fluorodeoxyglucose uptake in pelvic nodes. Core biopsy demonstrated only reactive changes, and the patient's symptoms spontaneously resolved. Since completion of BV, HIV remains undetectable with CD4 count ranging between 86 and 318 per μL on uninterrupted ART. PEL is in continued CR >39 months after completion of BV, and the patient is independent with all activities of daily living.

Patient B

A 53-year-old man with AIDS (CD4 count 181 per μL , HIV 128 582 copies per mL) presented with abdominal distention after a 2-year hiatus from ART. CT demonstrated widespread lymphadenopathy, with marked ascites composed of large atypical lymphoid cells (Figure 1A) positive for KSHV (Figure 1B), CD30 (Figure 1C), CD45, and CD138, negative for CD19 and CD20,

with monoclonal immunoglobulin heavy chain gene rearrangement on polymerase chain reaction, consistent with PEL. Laboratory tests were notable for mild anemia but normal neutrophil and platelet counts, with elevated KSHV viral load > 8.8 copies per mL and interleukin-6 at 10 pg/mL (normal <5). The patient resumed ART and enrolled in a clinical trial with vorinostat plus da-EPOCH. After cycle 4, CD4 count was improved at 434 per μL , and HIV viral load at 166 copies per mL, but PET/CT demonstrated a new duodenal mass.

Given the high level of CD30 expression in his lymphoma, the patient received 2 doses of BV 1.8 mg/kg IV 3 weeks apart. KSHV viral load was noted to have decreased to 4.9 from >8.8 log copies per mL at time of diagnosis. CD4 count increased further to 519 per μL with low-level HIV viremia at 78 copies per mL. Subsequent PET/CT demonstrated resolution of the duodenal mass and decreased size of prior lymphadenopathy but development of new pericardiac lymphadenopathy and a gastric mass confirmed a solid-variant PEL (Figure 1D); however, lymphoma cells from the gastric mass were negative for CD30 expression (Figure 1F) in contrast to the initial diagnostic ascites (Figure 1C). The patient received 3 cycles of ifosfamide, carboplatin, etoposide, and bortezomib resulting in CR after cycle 2 (confirmed by PET/CT and undetectable serum KSHV) followed by autologous hematopoietic stem cell transplant. Four weeks after transplant, the CD4 count was 256 copies per μL and low-level HIV viremia persisted. at 211 copies per mL. PET/CT demonstrated recurrence, with lymphadenopathy and a new site of uptake in the left abdomen closely associated with multiple loculated fluid collections and loops of bowel. The patient declined additional evaluation and pursued hospice, subsequently passing away 16 months after PEL diagnosis.

Results and discussion

PEL is a rare and very aggressive B-cell lymphoma with limited data to guide treatment, particularly in the setting of refractory disease. Due to the short median survival, novel approaches are warranted. Referral to centers conducting clinical trials in PEL, including the National Cancer Institute and AIDS Malignancy Consortium sites, is crucial to improving outcomes (ClinicalTrials.gov Identifiers #NCT02911142 and #NCT02823327).

CD30 is consistently expressed by PEL, similar to classical Hodgkin lymphoma and many T-cell lymphomas for which BV is approved. In our 2 patients, second-line therapy of PEL with single-agent BV was tolerable and resulted in ongoing complete remission at 39 months in patient A. Notably, the new sites of disease in patient B demonstrated loss of CD30 expression, suggesting preferential expansion of clone(s) expected to be unsusceptible to BV. Concurrent administration of BV with cytotoxic chemotherapy would be expected to increase depth and durability of response in patients with functional status sufficient to receive combination therapy. BV has been feasibly combined with upfront^{13,14} and second-line¹⁵ lymphoma regimens. Considering the typically poor prognosis with standard chemotherapy, addition of

BV to combination chemotherapy should be considered in both upfront and salvage therapy of PEL.

Authorship

Contribution: V.A.C. and E.G.R. wrote the manuscript; H.-Y.W. prepared figures for the manuscript; and V.A.C., E.G.R., and H.-Y.W. reviewed and approved the manuscript.

Conflict-of-interest disclosure: The authors declare no competing financial interests.

Correspondence: Erin G. Reid, Moores Cancer Center, 3855 Health Sciences Dr, La Jolla, CA 92093-0987; e-mail: egreid@ucsd.edu.

References

1. Nador RG, Cesarman E, Chadburn A, et al. Primary effusion lymphoma: a distinct clinicopathologic entity associated with the Kaposi's sarcoma-associated herpes virus. *Blood*. 1996;88(2):645-656.
2. Guillet S, Gérard L, Meignin V, et al. Classic and extracavitary primary effusion lymphoma in 51 HIV-infected patients from a single institution. *Am J Hematol*. 2016;91(2):233-237.
3. Boulanger E, Gérard L, Gabarre J, et al. Prognostic factors and outcome of human herpesvirus 8-associated primary effusion lymphoma in patients with AIDS. *J Clin Oncol*. 2005;23(19):4372-4380.
4. Carbone A, Gloghini A, Vaccher E, et al. Kaposi's sarcoma-associated herpesvirus/human herpesvirus type 8-positive solid lymphomas: a tissue-based variant of primary effusion lymphoma. *J Mol Diagn*. 2005;7(1):17-27.
5. Reid EG. Bortezomib-induced Epstein-Barr virus and Kaposi sarcoma herpesvirus lytic gene expression: oncolytic strategies. *Curr Opin Oncol*. 2011; 23(5):482-487.
6. Sunil M, Reid E, Lechowicz MJ. Update on HHV-8-associated malignancies. *Curr Infect Dis Rep*. 2010;12(2):147-154.
7. Simonelli C, Spina M, Cinelli R, et al. Clinical features and outcome of primary effusion lymphoma in HIV-infected patients: a single-institution study. *J Clin Oncol*. 2003;21(21):3948-3954.
8. Lugtenburg PJ, Visser O, Doorduyn JK, Dinmohamed AG. Treatment and survival of primary effusion lymphoma (PEL): a population-based study among 25 patients diagnosed in the Netherlands between 2002 and 2015 [abstract]. *Hematol Oncol*. 2017;35(S2). Abstract 342.
9. Sullivan RJ, Pantanowitz L, Casper C, Stebbing J, Dezube BJ. HIV/AIDS: epidemiology, pathophysiology, and treatment of Kaposi sarcoma-associated herpesvirus disease: Kaposi sarcoma, primary effusion lymphoma, and multicentric Castlemans disease. *Clin Infect Dis*. 2008;47(9):1209-1215.
10. Okada S, Goto H, Yotsumoto M. Current status of treatment for primary effusion lymphoma. *Intractable Rare Dis Res*. 2014;3(3):65-74.
11. Adcetris (brentuximab vedotin) [package insert]. Bothell, WA: Seattle Genetics, Inc; 2018.
12. Bhatt S, Ashlock BM, Natkunam Y, et al. CD30 targeting with brentuximab vedotin: a novel therapeutic approach to primary effusion lymphoma. *Blood*. 2013;122(7):1233-1242.
13. Connors JM, Jurczak W, Straus DJ, et al; ECHELON-1 Study Group. Brentuximab Vedotin with Chemotherapy for Stage III or IV Hodgkin's Lymphoma. *N Engl J Med*. 2018;378(4):331-344.
14. Horwitz S, O'Connor OA, Pro B, et al. Brentuximab vedotin with chemotherapy for CD30-positive peripheral T-cell lymphoma (ECHELON-2): a global, double-blind, randomised, phase 3 trial [published correction appears in *Lancet*. 2019;393(10168):228]. *Lancet*. 2019;393(10168):229-240.
15. Cassaday RD, Fromm J, Cowan AJ, et al. Safety and activity of brentuximab vedotin (BV) plus ifosfamide, carboplatin, and etoposide (ICE) for relapsed/refractory (Rel/Ref) classical Hodgkin lymphoma (cHL): initial results of a phase I/II trial [abstract]. *Blood*. 2016;128(22). Abstract 1834.