

BRIEF REPORT

Cytosine Arabinoside Therapy for Disseminated Herpes Zoster in a Patient with IgG Pyroglobulinemia

By EUGENE M. MCKELVEY AND HAU C. KWAAN

PATIENTS WITH LYMPHOMA, leukemia, multiple myeloma, or other conditions characterized by an altered immunologic state have an increased susceptibility to the manifestations of common viral infections. In such patients, disseminated infections with the DNA viruses, herpes simplex, and herpes zoster have carried a poor prognosis.^{1,2}

Various attempts have been made to treat these disseminated infections with antiviral agents which act by interfering with DNA synthesis. 5-iodo-2-desoxyuridine (IUDR) has been used in the treatment of disseminated herpes zoster,³ herpes simplex encephalitis,⁴ and in the topical therapy of herpes keratitis.⁵ However, systemic IUDR therapy has been associated with severe toxicity to bone marrow and liver. A recently developed pyrimidine nucleoside analog, cytosine arabinoside, selectively interferes with DNA synthesis.^{6,7} It inhibits the growth of herpes simplex and herpes zoster viruses in vitro and is useful as topical therapy for herpetic keratitis, both in experimental animals and in man.^{8,9} Systemic therapy with cytosine arabinoside has been effective in the treatment of human acute leukemia and lymphoma^{10,11} and has generally been well tolerated. Cytosine arabinoside has not, however, been previously used in the treatment of disseminated human herpetic disease.

The occurrence of a progressive, disseminated herpes zoster infection in a patient with a dysproteinemia and an advanced lymphoproliferative disorder offered an opportunity to investigate the effects of cytosine arabinoside upon these two diseases.¹²

CASE REPORT

Our patient, a 65 year old hospital orderly, was in good health until December 1965 when he first noted a painless swelling in his neck. Four months later generalized lymphadenopathy, mild hepatosplenomegaly and anemia developed. A lymph node biopsy was interpreted as a primary lymphoproliferative disorder of uncertain histologic classification. His total serum protein was 14.4 Gm. per 100 ml. with 7.5 Gm. globulin per 100 ml. Immuno-

From the Department of Medicine, Northwestern University Medical School, and the Veterans Administration Research Hospital, Chicago, Ill.

First submitted May 6, 1969; accepted for publication July 10, 1969.

EUGENE M. MCKELVEY, M.D.: *Assistant Professor of Medicine, Department of Medicine, Northwestern University Medical School.* HAU C. KWAAN, M.D., F.R.C.P. (Edin.): *Associate Professor of Medicine, Department of Medicine, Northwestern University Medical School, Chicago, Ill.*

Requests for reprints should be addressed to Hau C. Kwaan, M.D., Veterans Administration Research Hospital, 333 E. Huron Street, Chicago, Ill.

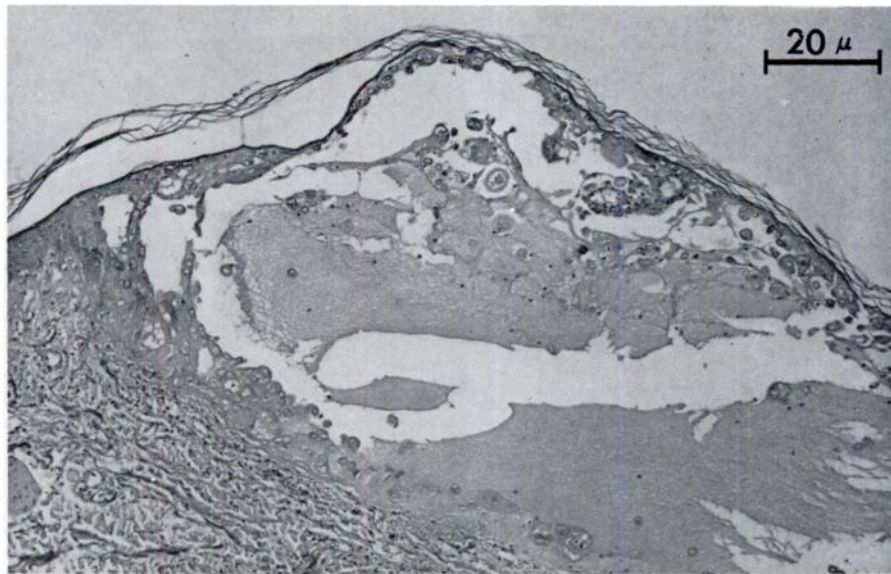


Fig. 1.—Section of skin biopsy showing characteristic herpetic lesion. Hematoxylin and eosin stain.

electrophoretic analysis revealed the presence of a monoclonal IgG, Type K protein which had the characteristics of a pyroglobulin. A detailed description of this pyroglobulin has been previously reported.¹³

Laboratory studies revealed a hemoglobin of 7.2 Gm./100 ml., hematocrit of 21.5 per cent and a white blood count of 16,000/mm³ with 49 per cent neutrophils, and 47 per cent lymphocytes, including many atypical, plasmacytoid forms. On bone marrow aspiration, 27 per cent of the cells were lymphocytes with many plasmacytoid forms while 14 per cent were mature plasma cells. Treatment with cytoxan and prednisone and intermittent therapy with melphalan and prednisone was administered throughout the following 2 years without significant improvement in clinical status or serum pyroglobulin.

In February, 1968, the patient was given a brief, intensive course of treatment with melphalan (14 mg./day for 18 days), prednisone, and procarbazine. Transient leukopenia followed and the serum IgG concentration fell from 50 mg./ml. to 26 mg./ml. Serum IgA fell from .29 to .19 mg./ml. and IgM from 0.3 to 0.2 mg./ml.

One month later, the patient was hospitalized with clinical signs of a left lower lobe pneumonia. Treatment was begun with procaine penicillin, but when his blood cultures became positive for *E. coli*, parenteral kanamycin was initiated. Fever persisted, however, and 4 weeks after the onset of his pneumonia a vesicular eruption was noted on the face and trunk. This eruption became widespread and crops of new lesions continued to appear. A skin biopsy from the site of a vesicular lesion revealed a multiloculated vesicle with reticular degeneration of the epidermal cells. Along the wall and septa of the vesicles a large number of giant cells and degenerating balloon cells containing eosinophilic intranuclear inclusion bodies were seen (Fig. 1). There was no evidence of infiltration by atypical plasma cells or lymphocytes.

The patient's clinical condition became steadily worse with progressive facial, pulmonary and oronasal involvement (Fig. 2). Accordingly, on the third day of the eruption, a 120-hour continuous intravenous infusion of cytosine arabinoside was begun with 180 mg. (100 mg./M²) being administered in each 24-hour period.* The patient also received one 20 ml. injection of gamma globulin. Within 24 hours the facial swelling had decreased significantly

*Cytosine arabinoside was kindly supplied by the Upjohn Company.

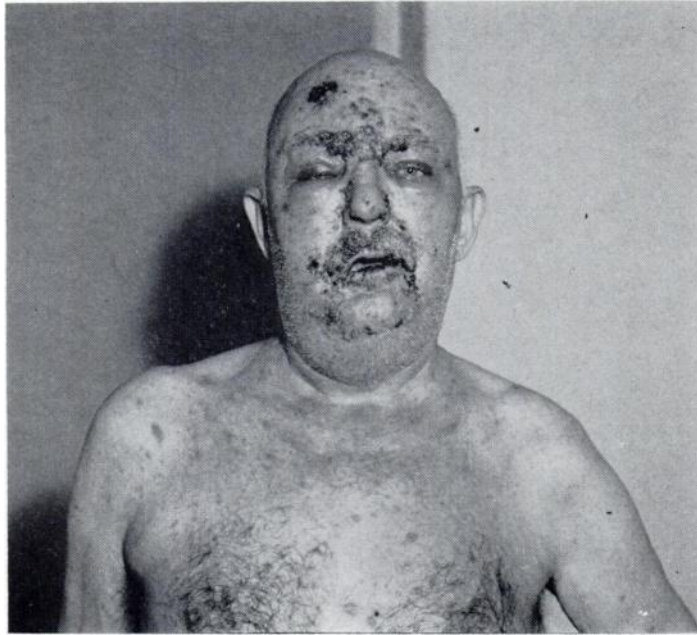

Fig. 2.—Appearance of the patient on the day prior to cytosine arabinoside therapy. Note presence of marked facial edema.

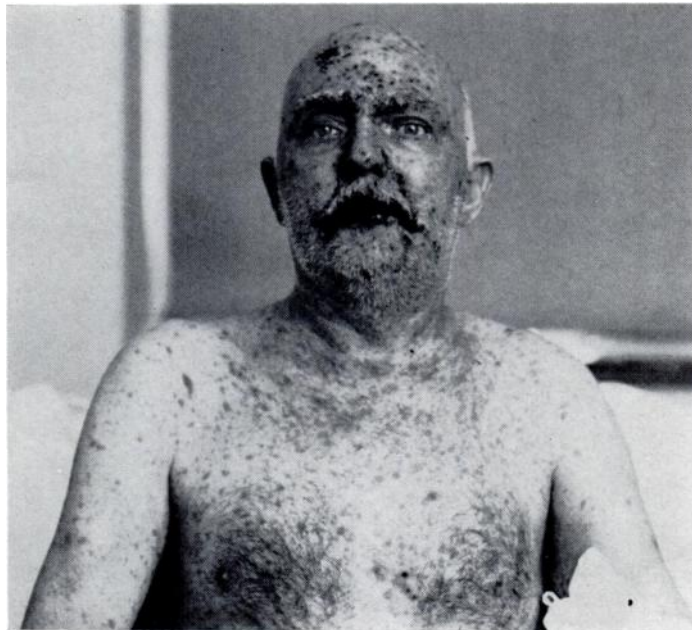


Fig. 3.—Appearance of patient after twenty four hours of cytosine arabinoside therapy. Note the disappearance of facial edema and continued eruption.

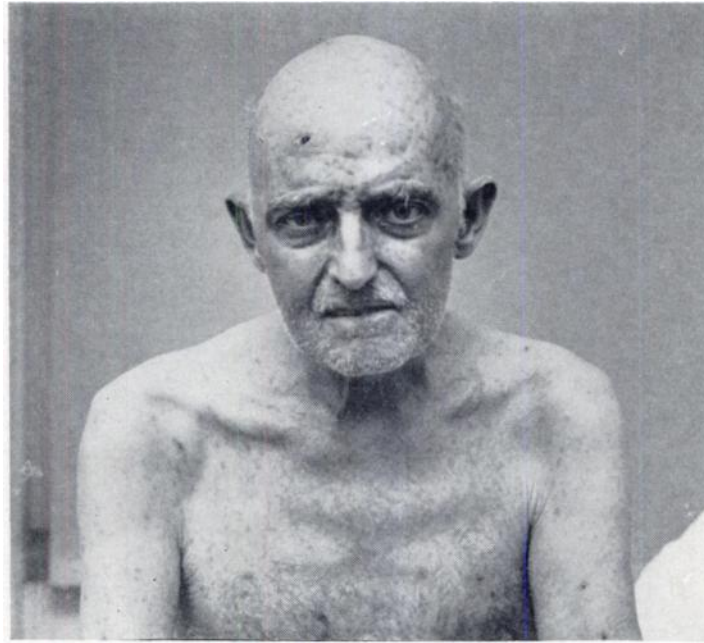


Fig. 4.—Appearance of patient two months after cytosine arabinoside therapy.

(Fig. 3). The skin lesions which appeared at this time were less erythematous and did not progress to the vesicular stage. The patient's clinical condition improved dramatically so that by the third day of infusion no new skin lesions were apparent and after three weeks, only minimal residual skin changes remained.

Twenty days after completion of the first course, the patient received a second infusion of cytosine arabinoside. A total dose of 765 mg. (450 mg./M²) was administered over a 48 hour period. This was given as treatment for his lymphoproliferative disorder; no indication of active herpetic disease was present. The shorter course schedule was designed to lessen the likelihood of significant bone marrow toxicity. Both courses of treatment were tolerated quite well, and produced only a transient leukopenia of moderate degree. A bone marrow specimen obtained one week after the second course of treatment demonstrated a normal myeloid and erythroid maturation pattern. While 13 per cent mature plasma cells were again noted, the lymphocytic elements were not predominant and no abnormal lymphocytes were observed in either the bone marrow or the peripheral blood. Upon discharge the patient was completely asymptomatic with no evidence of any continuing viral or bacterial infection (Fig. 4).

DISCUSSION

Since Pancoast and Pendergrass¹⁴ first published their finding of a high incidence of herpes zoster in Hodgkin's disease, an increasing number of reports have appeared associating herpes infection with a variety of disorders, particularly malignant conditions characterized by a low circulating level of gamma globulin or other alterations in the host immune response. In addition, treatment with large doses of corticosteroids, alkylating agents or radiation appears to contribute to an increased susceptibility to such infections.^{1,2,15} Several of these factors pertain to our patient. He had a longstanding IgG dysproteinemia with low concentrations of other serum immunoglobulins. His

serum immune globulins were then further reduced by an intensive course of chemotherapy with melphalan, procarbazine and prednisone which was completed 5 weeks before the onset of his vesicular eruption.

Our patient's clinical course was characteristic of a disseminated herpetic infection. Unfortunately, attempts to culture virus directly from the skin vesicles were unsuccessful and it was necessary to defer serologic testing with herpes zoster antigen for technical reasons. The patient's stored serum became highly anticomplementary and subsequent complement fixation tests were therefore uninterpretable. The skin biopsy is quite typical of a herpes vesicle, but since the pathologic appearance of herpes simplex and herpes zoster lesions are identical, they cannot be distinguished by this means. However, low serum levels of herpes simplex antibody were documented throughout our patient's course and no change was noted in the herpes simplex complement fixation titer between the acute and convalescent serums. These tests were completed before the serum had become anticomplementary. Therefore, on the basis of his clinical course and this pathologic and serologic data, our patient was presumed to have a disseminated herpes zoster infection.

Cytosine arabinoside is a recently synthesized pyrimidine nucleoside. It is believed to inhibit the reduction of cytidine diphosphate and its incorporation into DNA molecules. Since cytosine arabinoside is cytotoxic primarily in the "S" or synthesis phase of the cellular growth cycle,¹⁶ the temporal duration of cytosine therapy is as important as the dose level in respect to the biologic effect which is achieved. While megaloblastic changes¹⁷ and chromosome aberrations¹⁸ in both the erythroid and myeloid elements have been observed during cytosine arabinoside therapy, withdrawal of the drug or termination of its effect by administration of deoxycytidine is followed by rapid disappearance of these abnormalities.

Our patient showed a dramatic improvement in his clinical condition following cytosine arabinoside administration. No significant toxicity was encountered and, indeed, fewer abnormalities were noted in his bone marrow and peripheral blood following therapy. In view of these findings, further trials of cytosine arabinoside in disseminated herpes infections seem indicated.

SUMMARY

Cytosine arabinoside is a new chemotherapeutic agent which inhibits DNA synthesis and has shown activity against experimental DNA virus infections. This drug was used to treat a 65 year old man with an IgG, Type K serum pyroglobulin accompanying a lymphoproliferative disorder who developed a fulminant, disseminated herpes zoster infection. Rapid attenuation of his disease was apparent. No new skin lesions developed after the second day of treatment and within 6 weeks the patient had achieved a complete recovery from his viral disease.

ACKNOWLEDGMENTS

The authors are indebted to Dr. Bryon S. Berlin, Chief of the Clinical Virology Laboratory, Northwestern University Medical Center for his assistance in performing the viral studies, and to Drs. Donald Hajek, Allen Belmont, and Ted Gasteyer for their help in the clinical management of this patient.

ADDENDUM

Since this manuscript was first submitted, Hall and associates have also reported clinical responses with cytosine arabinoside in additional patients with widely disseminated herpetic disease.¹⁹

SUMMARIO IN INTERLINGUA

Arabinosida de cytosina es un nove agente chimotherapeutic que inhibi le synthese de ADN e que ha manifestate un activitate contra infectiones experimental a virus de ADN. Iste pharmaco esseva usate pro tractar un masculo de 65 annos de etate con un pyroglobulina seral IgG del typo K in association con un disordine lymphoproliferative, sequite del disveloppamento de un fulminante infection disseminate de herpes zoster. Un rapide attenuation del morbo esseva apparente. Nulle nove lesiones cutanee se disveloppava post le secunde die del tractamento, e intra 6 septimanas le patiente esseva completamente restabite ab su morbo viral.

REFERENCES

1. Shanbrom, E., Miller, S., and Haar, H.: Herpes zoster in hematologic neoplasias. Some unusual manifestations. *Ann. Intern. Med.* 53:523, 1960.
2. Merselis, J. G., Kaye, D., and Hook, E. W.: Disseminated herpes zoster. *Arch. Intern. Med.* 113:679, 1961.
3. Waltuch, G., and Sachs, F.: Herpes zoster in a patient with Hodgkin's disease. *Arch. Intern. Med.* 121:458, 1968.
4. Breeden, C. J., Hall, T. C., and Tyler, H. R.: Herpes simplex encephalitis treated with systemic 5-iodo-2-deoxyuridine. *Ann. Intern. Med.* 65:1050, 1966.
5. Kaufman, H. E., and Maloney, E. D.: Use of 5-iodo-2'-deoxyuridine (IDU) in treatment of herpes simplex keratitis. *Arch. Ophthalmol.* 68:235, 1962.
6. Cardeilhac, P. T., and Cohen, S. S.: Some metabolic properties of cytosine arabinoside. *Cancer Res.* 24:1595, 1964.
7. Chu, M., and Fischer, G. A.: Proposed action of cytosine arabinoside. *Biochem. Pharm.* 11:423, 1962.
8. Underwood, G. E.: Activity of 1- β -D-arabinofuranosylcytosine hydrochloride against herpes simplex keratitis. *Proc. Soc. Exp. Biol. Med.* 111:660, 1962.
9. Kaufman, H. E., and Maloney, E. D.: IDU and cytosine arabinoside in experimental herpetic keratitis. *Arch. Ophthalmol.* 69:626, 1963.
10. Howard, J. P., Cerik, H., and Murphy, M. L.: Cytosine arabinoside in acute leukemia in children. *Cancer Chemother. Rep.* 50:287, 1966.
11. Talley, R. W., O'Bryan, R. M., Tucker, W. G., and Loo, R. V.: Clinical pharmacology and human anti-tumor activity of cytosine arabinoside. *Cancer* 20:809, 1967.
12. Kwaan, H. C., McKelvey, E. M., Hajek, D. F., and Belmont, A.: Disseminated herpes zoster treated with cytosine arabinoside. *Clin. Res.* 17:330, 1969.
13. Patterson, R., Weiszer, I., Rambach, W., Roberts, M., and Suszko, I.: Comparative cellular and immunochemical studies of two cases of pyroglobulinemia. *Amer. J. Med.* 44:147, 1968.
14. Pancoast, H. K., and Pendergrass, E. P.: The occurrence of herpes zoster in Hodgkin's disease. *Amer. J. Med. Sci.* 168:326, 1924.
15. Cortisone and herpes zoster. *Editorial, New Eng. J. Med.* 261:517, 1959.
16. Brewen, J. G.: The induction of chromatid lesions by cytosine arabinoside in post-DNA synthetic human leukocytes. *Cytogenetics* 4:28, 1965.
17. Talley, R. W., and Vaitkevicius, V. K.: Megaloblastosias produced by a cytosine antagonist 1- β -D arabinofuranosyl-cytosine. *Blood* 21:352, 1963.
18. Bell, W., Whang, J., Carbone, P., Brecher, B., and Block, J.: Cytogenetic and morphologic abnormalities in human bone marrow cells during cytosine arabinoside therapy. *Blood* 27:771, 1966.
19. Hall, T., Wilfert, C., Jaffe, N., Traggis, D., Lux, S., Rompf, P., and Katz, S.: Treatment of varicella-zoster with cytosine arabinoside. *Clin. Res.* 17:470, 1969.