

Chromosome Studies in Preleukemia

I. Aneuploidy of Group C Chromosomes in Three Patients

By JANET D. ROWLEY, RICHARD K. BLAISDELL AND LEON O. JACOBSON

*With the technical assistance of Judith Mikuta,
Rachel Byrne and Lona Shepley*

IT IS NOW ESTABLISHED that many patients with acute leukemia exhibit abnormalities of chromosome number or morphology in the affected (leukemic) cells which may be constant in any one patient, but may vary considerably from one patient to another.^{1,2} Although it is presumed that these chromosomal abnormalities are related to the neoplastic behavior of leukemic cells,³ the precise role of such changes in the evolution of the leukemic state remains to be determined. Direct evidence bearing on this issue would accrue from systematic analyses of chromosome constitution beginning with the presumably normal subject, progressing through the preleukemic phase and culminating in the overtly leukemic stage in affected individuals.

Such evidence has not been forthcoming because human acute leukemia is still a relatively rare disorder, most cases of which occur sporadically, apparently arising *de novo*, and the disease is usually not recognized until clinically manifest. However, the occurrence of certain hematologic syndromes with a propensity to terminate in acute leukemia⁴ affords an opportunity to assess the importance of chromosomal alterations in the pathogenesis of leukemia. These preleukemic or, more precisely, potentially leukemic syndromes may be classified into the aplastic, myelodysplastic, and myeloproliferative disorders. Although the first and the third of these terms are conventional designations requiring no further elaboration, the myelodysplasias^{4,5} refer to a group of disorders exhibiting morphologic evidence in the marrow and the blood of disturbed formation of any, or any combination, of the major blood cell lineages (erythroid, granulocytic, megakaryocytic), not characteristic of the aplastic, the myeloproliferative, or the leukemic states, yet displaying features often intermediate or transitional between these conditions. The following examples

From the Department of Medicine, University of Chicago, and the Argonne Cancer Research Hospital (operated by the University of Chicago for the United States Atomic Energy Commission), Chicago, Ill.

This work was supported in part by the Clarence J. Irwin Memorial Research Fund and by the Cancer Society of St. Joseph County, Inc., South Bend, Ind. Dr. Blaisdell is the recipient of the Lederle Medical Faculty Award.

First submitted July 2, 1965; accepted for publication Oct. 21, 1965.

JANET D. ROWLEY, M.D.: *Research Associate (Assistant Professor), Department of Medicine, University of Chicago Hospitals and Clinics, and the Argonne Cancer Research Hospital.* RICHARD K. BLAISDELL, M.D.: *Assistant Professor, Department of Medicine, University of Chicago Hospitals and Clinics, and the Argonne Cancer Research Hospital.* LEON O. JACOBSON, M.D.: *Professor, Department of Medicine, University of Chicago Hospitals and Clinics, Dean of the Division of the Biological Sciences, and Director, Argonne Cancer Research Hospital.*

illustrate the heterogeneity of this group and yet its separateness from the aplastic, myeloproliferative and leukemic classes: refractory hyperplastic anemia, sideroachrestic anemia, atypical myeloid disorder, preleukemic acute leukemia, primary splenic hematopenia. Although certain causal factors might be implicated, the etiology in most cases remains obscure, and although recovery may ensue, most cases are fatal or terminate after conversion to acute leukemia.

Only five cases of persistent abnormalities of chromosome morphology have been reported in patients with potentially leukemic disorders, in whom leukemic transformation has not occurred;⁶⁻¹⁰ in all other cases with abnormal karyotypes, leukemia was evident when the marrow was first examined.^{6,8,11}

During the investigation of 15 potentially leukemic patients who manifested obscure anemia, leukopenia, thrombocytopenia or thrombocytosis, we have found three individuals with abnormal chromosome numbers, none of whom has yet developed acute leukemia. In each case, the abnormality is confined to the C group chromosomes, but it is a different alteration in each instance. The respective diagnoses have been aplastic anemia, idiopathic sideroachrestic anemia, and idiopathic thrombocythemia—each being an example of the three classes of potentially leukemic hematologic syndromes referred to above. This is the first report of chromosome abnormalities in sideroachrestic anemia and thrombocythemia. A case of aplastic anemia with 47 chromosomes has been reported, although no karyotypic analysis was included.¹²

Since these conditions may all terminate in leukemia, it seems likely that the existence of such chromosomal abnormalities before the onset of overt leukemia is an important observation which should be considered in any hypothesis relating aneuploidy and leukemia. Our purpose in presenting these cases at this time is to consider the possible significance of the chromosomal alteration and to encourage other investigators to report similar cases of patients with potential leukemia associated with a stable abnormal cell-line.

MATERIALS AND METHODS

Chromosome preparations were made using a modification of the direct bone marrow technic of Tjio and Whang.¹³ The bone marrow sample of approximately 1 ml. was put in a centrifuge tube containing 5 ml. of Hank's solution to which was added 0.1 ml. of commercial heparin (1000 units/ml.) and 0.1 ml. of an 0.5 µg./ml. solution of vincalukoblastine (Velban, Lilly). After thorough mixing, the sample was incubated for 1 hour at 37 C. and centrifuged at 600 r.p.m. for 10 minutes; the supernatant was discarded, and 8-10 ml. of warm (37 C.) hypotonic (0.95 per cent) sodium citrate solution was added. The material was incubated for 20 minutes at 37 C., centrifuged for 10 minutes at 600 r.p.m., and the supernate was discarded. The cells were gently resuspended in 5 ml. of fresh 1:3, glacial acetic acid: absolute methanol, fixative. After 45 minutes, the cell suspension was centrifuged, the first fixative supernatant was removed, and the cells were resuspended in 5 ml. of 45 per cent glacial acetic acid and 55 per cent methanol. This second fixative was changed twice daily until chromosome preparations of suitable quality were obtained. This occasionally took over one week and required more than a dozen changes of fixative. The material was stored at -4 C. during this period. Slide preparations of the cells were then made by the standard air-dry technic;¹⁴ they were stained with Leishman-Giemsa stain and mounted in Histoclad (Clay-Adams, Inc.).

Peripheral blood was cultured using essentially the technic of Moorhead.¹⁵ The leukocytes

were separated from the red cells by centrifuging the heparinized blood at 600 r.p.m. for 10 minutes. The buffy coat was removed and added to TC medium 199, with phytohemagglutinin M (Difco). Velban was added either overnight or for 2 hours before terminating the culture, which was usually after about 72 hours.

Buccal smears were prepared according to a modified technic of Ross.¹⁶

CASE REPORTS

Case 1

A 23-year-old white, unmarried, male spray-painter was apparently well until November 1963, when he first noted furuncles of the buttocks. Chloramphenicol orally and intramuscularly was prescribed, totaling approximately 16.0 Gm. during a 3-week period. The infection subsided, but in January 1964, he began to have frequent epistaxis, easy bruising, and progressive weakness. In April 1964, a second course of chloramphenicol, 3.0 Gm. over 4 days, was given for a sore throat.

As a painter, the patient had used lacquer and various thinners for the previous three years. No hematologic examinations had been performed prior to exposure to the volatile solvents or to the chloramphenicol.

There was no family history of a similar illness, other hematologic disorders, or developmental anomalies.

When seen at the University of Chicago Hospitals on May 15, 1964, physical examination revealed pallor and petechiae over the extremities. There was no palpable enlargement of the lymph nodes, the spleen or the liver. He had normal adult male external genitalia and hair distribution.

Laboratory examination disclosed hematocrit 21 per cent, hemoglobin 6.8 Gm./100 ml., reticulocytes 0.1 per cent, total leukocytes 3000/cu. mm., with segmented neutrophils 19 per cent, lymphocytes 77 per cent, and monocytes 4 per cent; and platelets 4400/cu. mm. The granulocyte alkaline phosphatase score was 81 (normal range 15 to 50). The red cells were Xg (a+). Assays of hemolysates for glucose-6-phosphate dehydrogenase (G-6-PD) activity were within normal limits; starch gel electrophoresis revealed the normal G-6-PD B pattern.

Sternal bone marrow sections showed pronounced hypocellularity, with substantial reduction of granulocytes, erythroid precursors, and megakaryocytes, and replacement of these elements by fatty tissue. No abnormal cells were seen. Excessive stainable iron was demonstrated.

The pancytopenia had failed to respond to iron, liver extract, folic acid, and vitamin B₁₂ therapy during April 1964, and only transient benefit had been noted after four separate blood transfusions.

In September 1964, after 4 months of oral fluoxymesterone (Halotestin) 40 mg. daily, the patient's hemoglobin value rose to 15.9 Gm./100 ml. In February 1965, another bone marrow examination, 7 months after the preceding one, revealed moderate erythroid activity, a persistent paucity of myeloid cells and megakaryocytes, but no evidence of leukemia.

When most recently seen on May 14, 1965, the patient had married and returned to work as a lift machine operator. There was still no palpable enlargement of hemopoietic organs, but recent purpuric lesions were evident on his limbs. The patient's hemoglobin level has remained normal in spite of a reduction in androgen dosage to 10 mg. daily. However, a moderate leukopenia has persisted (white cell count 3200/cu. mm.) with normal differential percentages; the severe thrombocytopenia (platelets 7700/cu. mm.) has not improved significantly.

The diagnosis has been aplastic anemia (marrow panhypoplasia with pancytopenia) probably related to chloramphenicol and/or organic solvents, with partial remission, induced by androgen therapy.

Case 2

This 62-year-old man was found to have a severe refractory anemia in July 1961. In November 1961 his spleen was removed; it weighed 746 Gm. and exhibited "hyperemia"

microscopically. This procedure failed to relieve the anemia. A total of 17 units of blood (approximately 4.25 Gm. of iron) were given over a 4-year period. In January 1963, mental deterioration, hepatomegaly, and diabetes mellitus were noted.

Family history included no known similar or related illnesses.

Although the patient had been married twice, each wife had had a hysterectomy prior to marriage, and thus, there were no children.

Examination at the time of admission to the University of Chicago Hospitals on November 1, 1964, revealed mental confusion, brown-grey dermal pigmentation, moderate enlargement of the heart, and pedal edema. The liver was slightly enlarged, but there were no palpable lymph nodes. The external genitalia were of normal male size and form.

Blood examinations disclosed hemoglobin 6.5 Gm./100 ml., hematocrit 20 per cent, red cell count 1.80×10^6 /cu. mm., mean cell volume 110 cu. mu., mean cell hemoglobin concentration 32 per cent, and reticulocyte count 4.6 per cent. The total leukocyte count was 8200/cu. mm. (corrected for normoblastemia), with segmented neutrophils 44 per cent, lymphocytes 44 per cent, monocytes 10 per cent, eosinophils 1 per cent, and basophils 1 per cent. The platelets numbered 252,000 to 607,200 per cu. mm. Red cell aniso-poikilocytosis, hypochromia, iron-positive inclusions, target cells and 94 nucleated erythrocytes per 100 white cells were seen in the blood smears.

Sternal marrow material aspirated in November 1964 showed intense erythroid hyperplasia, with a predominance of early erythroid precursors and an abundance of normoblasts with stainable iron inclusions ("ring sideroblasts"). There was no morphologic evidence of disturbed granulopoiesis or altered megakaryocyte-platelet formation. Stainable iron was pronounced and electron microscopy revealed heavy aggregates of iron in the mitochondria of marrow normoblasts, which is considered to be characteristic of certain sideroblastic anemias.¹⁷ A second marrow examination on April 20, 1965, just prior to death, revealed no significant change.

Death followed heart failure, atrial fibrillation, and pneumonia with septicemia. The clinical diagnosis was idiopathic sideroachrestic anemia, with progression to hemochromatosis involving the liver, pancreas, skin and the heart.

Autopsy confirmed the clinical diagnoses and revealed no evidence of leukemia. Histologic examination of the testes showed hyalinization of the basement membrane of the tubules, and absent spermatogenesis consistent with chronic liver disease; but examination showed no prominence of Leydig cells to support a diagnosis of the Klinefelter syndrome.

Case 3

This 59-year-old Negro housewife first noted prolonged bleeding following dental extractions in 1945. Since 1956, she had had four episodes of upper abdominal distress with melena, requiring blood transfusion, and in 1960 x-ray examination revealed a duodenal ulcer.

No similar illness or hematologic disorder was known in the family.

The patient had a normal menstrual history with menopause at age 49. However, although she had become pregnant on 4 occasions, spontaneous abortions with profuse uterine hemorrhage had occurred within a few months of the beginning of each pregnancy.

Physical examination, when the patient was first seen at the University of Chicago Hospitals on January 1964, disclosed no deformities, normal adult female external genitalia, but a somewhat small cervix and uterine corpus. Neither the liver, spleen, nor lymph nodes were palpably enlarged. There were no external evidences of hemorrhage and no signs of vascular occlusive disease.

Laboratory examinations showed a hemoglobin value of 10.4 Gm./100 ml., hematocrit 34 per cent, mean cell volume 77 cu. microns, mean cell hemoglobin concentration 31 per cent, reticulocytes 1.9 per cent, plasma iron 85 μ g./100 ml. and unsaturated transferrin 300 μ g./100 ml. In the blood smear, the red cells were hypochromic. Total leukocytes numbered 10,100/cu. mm., with neutrophils 76 per cent, lymphocytes 15 per cent, monocytes 3 per cent, and eosinophils 6 per cent. Platelet counts varied from 667,000 to 1,375,000 per cu. mm. Granulocyte alkaline phosphatase scores ranged from 39 to 104.

Sternal marrow sections revealed normal overall cellularity; however, megakaryocytes and platelets were unusually prominent. Stainable iron was reduced.

Table 1.—Chromosome Analyses in Three Patients

Case No.	Date	Source	Chromosome Number					Other	Total	Comment
			<45	45	46	47	48			
1	7/24/64	Marrow	16 (9)	36 (13)	5 (5)			1 cell—91 (1)	58 (28)	One C chromosome missing
	9/28/64	Blood	4 (1)	1 (1)	20 (4)				25 (6)	
	2/16/65	Marrow	11 (4)	46 (17)	1 (1)			1 cell—92 (1)	59 (23)	
	2/16/65	Blood	0	0	14 (7)		1 (1)		15 (8)	
2	1/12/65	Marrow	3 (3)	5 (5)	6 (5)	37 (18)	2 (2)	1 cell—68 (1)	54 (34)	One extra C chromosome
	3/5/65	Blood	1 (1)	4 (2)	40 (17)	2 (2)	1 (1)	1 cell—49 (1)	49 (24)	
	4/26/65	Marrow	8 (0)	6 (1)	14 (11)	42 (11)	1 (1)	1 cell—45-46	76 (24)	
								4 cells—46-47		
3	1/15/65	Marrow	1 (1)	5 (4)	27 (19)	3 (3)	10 (9)		46 (36)	Two extra C chromosomes
	1/15/65	Blood	1 (0)	5 (4)	17 (12)				23 (16)	
	3/29/65	Marrow*	1	1	1			3 cells—46-47 (3)	5 (3)	
			1 (1)	1 (1)	2 (2)	1 (1)		1 cell—<46 (1)	6 (6)	
	4/14/65	Marrow	7 (4)	5 (3)	13 (8)	1 (1)	4 (4)	1 cell—45-46 (1)	34 (24)	
	4/14/65	Marrow*						3 cells—46-47 (3)		

() Numbers in parentheses indicate number of photographed cells analyzed in detail.

*Six-hour incubation with H³ thymidine.

Following iron administration, the patient's hematocrit rose to a high of 55 per cent and on one occasion a peak red cell volume measurement of 38.4 ml./Kg. (normal 23 to 36 mg./Kg.) was recorded.

After the three marrow examinations, busulfan (Myleran) was prescribed in oral doses of 2-8 mg. daily; but only after one month did the blood platelet counts fall to the 200,000 to 300,000 per cu. mm. range.

The diagnosis has been idiopathic thrombocythemia; however, the elevated hematocrit and red cell volume value on one occasion after iron therapy permits consideration of the diagnosis of polycythemia vera masked by chronic bleeding and iron deficiency.

CHROMOSOME STUDIES

Case 1

Analysis of the marrow chromosomes revealed two cell populations (Table 1). In the first bone marrow specimen, 5/58 cells had 46 chromosomes and an apparently normal karyotype, whereas 36/58 cells had 45 chromosomes (Fig. 1). Thirteen of the hypodiploid cells were analyzed in detail and one group C chromosome was consistently missing from each metaphase. Nine of the 16 metaphases which contained less than 45 chromosomes were karyotyped and each of these cells was consistently lacking one C group chromosome, in addition to one or more other chromosomes, apparently on a random basis.

In contrast, the majority of cells from the peripheral blood had 46 chromosomes and a normal karyotype. Hypodiploid cells showed random loss of one or more chromosomes, presumably due to cell breakage.

Similar results were obtained on analysis of the second bone marrow specimen, aspirated 7 months later. However, only 1/59 metaphases contained 46 chromosomes, whereas 5/58 chromosomes had appeared normal in the first sample. Seventeen of the 46 metaphases containing 45 chromosomes were analyzed in detail and, again, showed the consistent loss of a C group chromosome. Analyzed cells from the second peripheral blood specimen had 46 normal chromosomes with one exception. This cell had 48 chromosomes; chromosome morphology was too poor to karyotype with certainty, but the cell appeared to have two extra small chromosomes belonging to groups E, F, or G-Y.

The proportion of hypodiploid cells in both bone marrow samples and the first peripheral blood specimen is much higher than normal for our laboratory. This may reflect some increased fragility of the patient's mitotic cells.

Case 2

The modal chromosome number in metaphases from both direct bone marrow preparations was 47 (Table 1). The extra chromosome was medium-sized, submetacentric, and belonged to the C group (Fig. 2). In the first sample of the 6 cells containing 46 chromosomes, none was clearly normal: 3 cells had an extra C and were missing an E chromosome, 2 cells had an extra C and were missing a G, and one cell could not be karyotyped because of poor morphology. In the second sample 3 months later of the 11 analyzed cells with 46 chromosomes, 5 had the normal number of chromosomes in the C-X group. These 5 could be normal cells or, as seems quite likely, they could be the result of breakage of a 47 chromosome metaphase with loss of a C group chromo-




Fig. 1.—Case 1, aplastic anemia. *Above:* metaphase plate from bone marrow, photographed using phase contrast. *Below:* karyotype of the same cell containing 45 chromosomes, with one C group chromosome missing.

some. Each of the other 6 analyzable cells with 46 chromosomes had an extra C chromosome; 1 was lacking an A chromosome, 1 was lacking a D, 2 were lacking an E, and 2 were lacking G-Y chromosomes. One of 5 metaphases with 45 chromosomes was lacking an F and G chromosome but had an extra C chromosome. The other 4 metaphases were lacking both a C plus some other chromosome, assuming they resulted from breakage of the hyperdiploid line. In the first sample, 2 metaphases had 48 chromosomes with 2 extra chromosomes in the C group. However, in the second preparation, the one metaphase with 48 chromosomes had an extra C and an extra E. This would suggest that

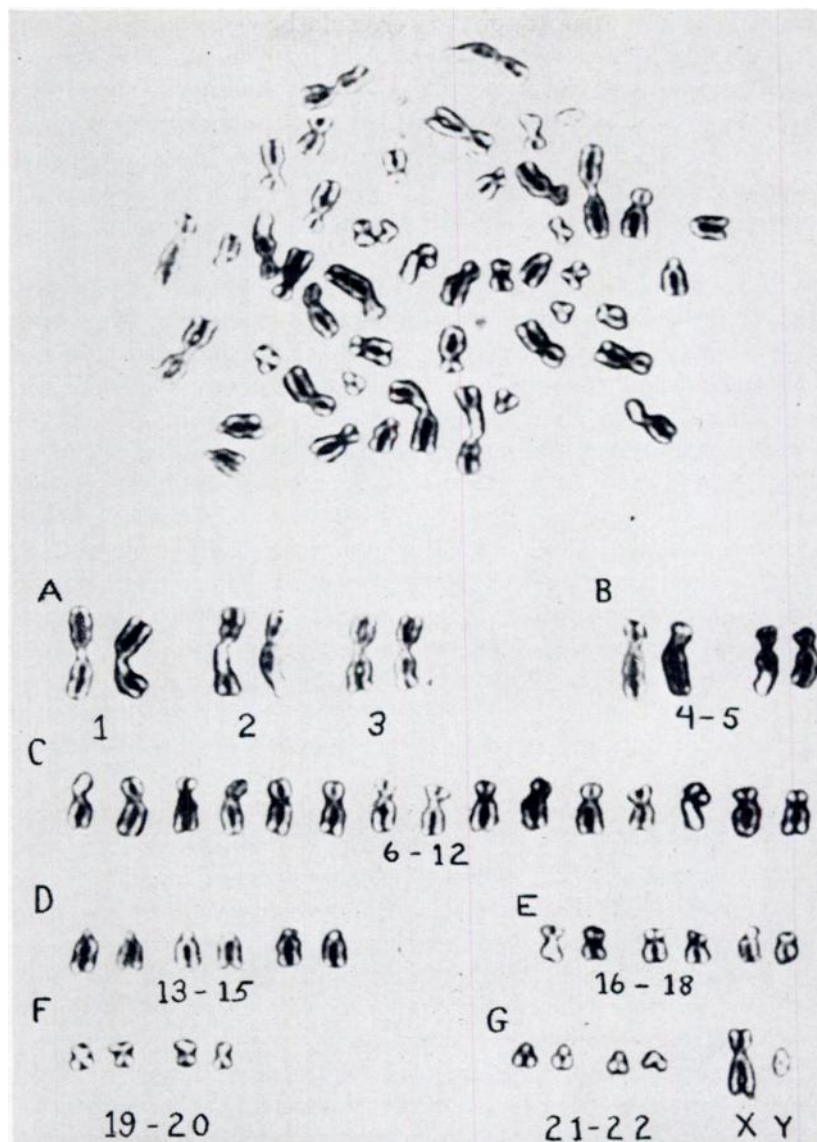


Fig. 2.—Case 2, sideroachrestic anemia. *Above:* metaphase plate obtained from direct bone marrow preparation, photographed using phase contrast. *Below:* karyotype of the above cell showing 47 chromosomes with one extra C group chromosome.

the cells with 48 chromosomes were the result of mitotic accidents, such as nondisjunction, rather than representatives of an additional stable hyperdiploid stem line.

Forty out of 49 cells obtained from a 72-hour peripheral blood culture contained 46 chromosomes. Seventeen of these were karyotyped and revealed normal chromosomes. Cells with less than 46 chromosomes showed random loss as a result of breakage. The metaphases with more than 46 chromosomes were of poor morphology, but the extra chromosomes appeared to be small

and could belong to group F, or G-Y, or could be fragments. No metaphases with a karyotype similar to the hyperdiploid line found in the marrow were obtained from the peripheral blood. Two 6-hour bone marrow cultures with H^3 thymidine have been done; no labeled metaphases were obtained from either culture. Two separate skin cultures have been established; both cultures became contaminated and no mitotic figures were obtained. Buccal smears were negative for sex chromatin (Barr) bodies.

Case 3

Two distinct cell lines were present in the two bone marrow specimens (Table 1). In the first sample, 27 of 46 metaphases contained 46 chromosomes and had an apparently normal karyotype. Six cells were hypodiploid with random loss of one or more chromosomes due to breakage of diploid cells. Nine of 46 metaphases had 48 chromosomes with two extra chromosomes in group C (Fig. 3). Metaphases with 47 chromosomes probably resulted from breakage of this latter cell line, as one metaphase had 2 extra C's and was without a D chromosome; the other 2 cells with 47 chromosomes had one extra C chromosome. The same two stem-lines were present in the second bone marrow preparation, but the proportion of hyperdiploid metaphases was lower. This might be related to the 6-hour culture period used to study the H^3 thymidine labeling pattern of these chromosomes. As Sandberg and colleagues have shown,¹⁸ aneuploid bone marrow cells do not tolerate in vitro culture as well as diploid cells do. Only one late-labeling C group chromosome was found, as would be expected in a normal female.

No hyperdiploid cells were found in the peripheral blood culture. Most hypodiploid cells had resulted from random loss of chromosomes from diploid cells. Detailed analysis of the cells with 46 chromosomes revealed that 5 of 17 cells in the peripheral blood had inconsistent abnormalities in the karyotype. In 2 such cells there appeared to be two extra C chromosomes, replacing a D and an F in one cell, and an E and a G in the other cell. These two cells would appear to be related to the cells with 48 chromosomes found in the marrow; however, since no hyperdiploid cells have been found in the peripheral blood, this apparent relationship seems doubtful. Of the other 3 abnormal yet diploid cells, one appeared to have 7 A group chromosomes while lacking a C; the second seemed to have an extra C in place of an E, and the third had an extra G replacing a D group chromosome. Buccal smears showed only 1 sex chromatin mass in 27 per cent of 200 cells counted.

DISCUSSION

Our 3 patients presented with apparently unrelated hematologic syndromes, yet all 3 of them had marrow chromosomal abnormalities involving the C group. These cases illustrate the principle that any cytogenetic examination of hematologic disorders must include a study of the bone marrow as well as of the blood, if the investigation is to be complete. All 3 patients showed persistent chromosomal aberrations in some or all metaphases from the bone marrow; and all had essentially normal karyotypes in metaphases from the periph-

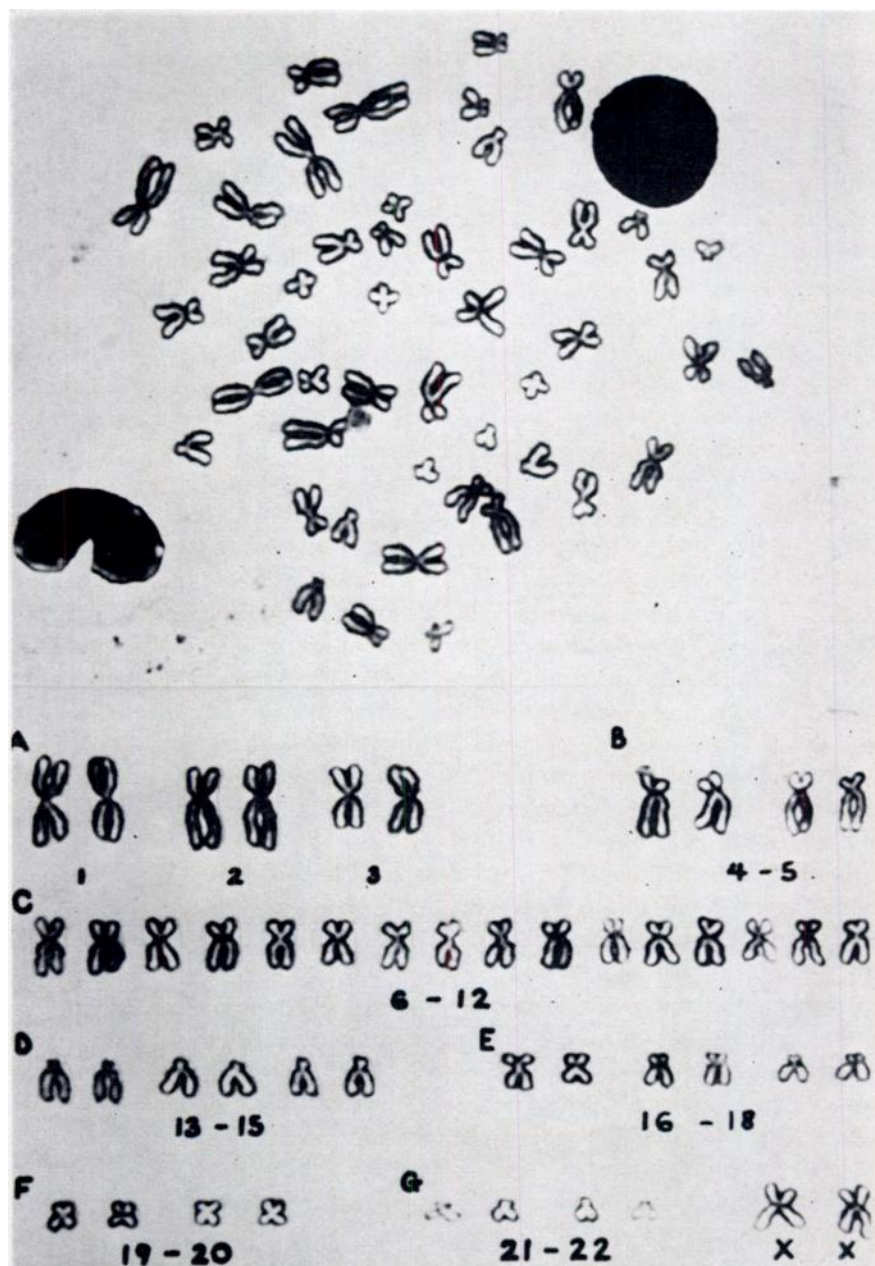


Fig. 3.—Case 3, idiopathic thrombocythemia. Above: metaphase plate obtained from a direct bone marrow preparation, photographed using phase contrast. Below: karyotype of the same cell containing 48 chromosomes with 2 extra C group chromosomes.

eral blood. Because of the predominantly diploid pattern of the lymphocytes cultured from the peripheral blood, the chromosomal abnormalities described are confined to marrow cells and have developed after embryogenesis—that is, they are presumably acquired and not congenital.

In Case No. 1 (aplastic anemia with 45 chromosomes) an autosome in the C group has been lost. The presence in the patient's red blood cells of the Xg^a antigen¹⁹ and a B band for G-6-PD²⁰ which are X-linked, indicate that the patient does have an X chromosome and thus excludes the possibility that the lost C chromosome is an X chromosome. The karyotype of the hypodiploid cells in the bone marrow has remained constant over a 7-month period; indeed, the proportion of hypodiploid cells apparently has increased at the expense of normal diploid cells. Clinically the patient's anemia has responded to androgen therapy, although his white blood cell and platelet counts remain low. The chromosome changes are probably not specific for chloramphenicol marrow toxicity for we have found a normal marrow karyotype in a woman who developed pancytopenia after exposure to chloramphenicol.

With regard to Case No. 2 (sideroachrestic anemia with 47 chromosomes) and Case No. 3 (idiopathic thrombocythemia with 48 chromosomes), our present interpretation is that they are examples of autosomal trisomy. The alternative diagnoses of Klinefelter's syndrome for Case No. 2, and quadruple-X female for Case No. 3, seem unlikely for the following reasons: the majority of cells in the peripheral blood have 46 chromosomes, the external genitalia are normal, and the buccal smears are compatible with normal male and normal female sex chromosome complements, respectively. Autoradiography is being used to determine the number of late-labeling X chromosomes in Cases No. 2 and 3.²¹ If our diagnoses are correct, Case No. 2 should have no late-labeling X chromosome and Case No. 3 should have only one. (This statement is discussed in Cases 1 and 3 above.)

In the five cases of group C trisomy that have been previously reported,²²⁻²⁶ the abnormality apparently occurred in the developing zygote. All were mosaics, with some cells containing 46 normal chromosomes, and a variable proportion of metaphases that had 47 chromosomes, with trisomy in the C group. The chromosome abnormality was observed in cells from the blood and/or skin; there was no mention of a bone marrow examination in any of these cases. These patients had developmental anomalies of the skeleton, nervous system, and/or genitalia, and no hematologic abnormality, with the exception of one woman who was normal but whose children in 2 of 3 pregnancies had multiple, severe, congenital abnormalities.

The majority of the reported cases of aneuploidy for group C chromosomes have involved patients with leukemia, especially acute leukemia, although patients with chronic myelogenous leukemia may also show chromosomal abnormalities in addition to the Ph¹ chromosome.²⁷ A review of the following papers is given, since in most of these presentations there is one case with a stable karyotypic abnormality occurring in a potentially leukemic patient allegedly "without leukemia." In Nowell and Hungerford's report⁶ of 7 cases of myeloproliferative disorders, 4 patients showed marrow chromosomal aberra-

tions. Two, or possibly three, patients whose illness had converted to subacute granulocytic leukemia, had abnormalities involving C group chromosomes. The first patient, with polycythemia converted to granulocytic leukemia, had 47 chromosomes with trisomy C and deletion of a D chromosome, yielding one resembling a G chromosome. In the second case, diagnosed as myeloid metaplasia which "converted to subacute granulocytic leukemia," one missing E group chromosome was replaced by a chromosome resembling a C group chromosome. The third case was a patient with polycythemia which had converted to myelofibrosis, but with blood counts suggestive of leukemia; the modal chromosome number was 45, with chromosomes missing from either the C or E group. The fourth, a patient with polycythemia vera who had received extensive radiophosphorus therapy and x-radiation to the spleen, had a modal chromosome number of 46, but all 6 analyzed bone marrow cells showed a deletion of the long arm of a D chromosome resulting in an apparent extra chromosome in the G group. This patient is the only one in whom there were no signs of leukemia.

Sandberg and colleagues studied 20 patients with myeloproliferative disorders "other than leukemia" and found only one patient with a chromosomal aberration.¹¹ The karyotypic abnormality occurred in an unusual case of myeloid metaplasia with "a possible leukemic-like terminal phase" and was considered to be trisomy of C 9. Forty-seven chromosomes were found in both bone marrow and peripheral blood cells on the initial examination, and in the bone marrow on a second examination. Sandberg and collaborators, in discussing their patients as well as those of Nowell and Hungerford, concluded that "chromosomal abnormalities were seen predominantly in patients with a terminal leukemic stage of the myeloproliferative disorder."

Goh and Swisher found no consistent morphologic chromosomal abnormalities in their 8 cases of myeloid metaplasia.²⁸ Solari's group⁷ described a patient with myeloid metaplasia following polycythemia vera who had been treated with x-radiation to the large bones and spleen, as well as radiophosphorus, and whose marrow cells showed a consistent replacement of one C group chromosome by an abnormally short acrocentric-type of chromosome. It was their impression that the abnormal chromosome resulted from the deletion of most of the long arm of one C group autosome. This patient had an elevated white blood count of 42,800 with 12 per cent myelocytes and 5 per cent metamyelocytes, present in the differential examination. Although no blasts were reported, these blood cell findings raise the possibility of leukemia. It is also conceivable that the chromosomal change was related to ionizing radiation. That irradiation can produce chromosomal aberrations is well known.²⁹ These aberrations consist of achromatic gaps, breaks, fragments, dicentrics, and rings, which occur sporadically in a variable percentage of cells. The consistent karyotypic abnormality reported by Nowell and Hungerford, and by Solari and his co-workers, in their irradiated patients may represent a stem-line which evolved from these aberrant cells or may be entirely unrelated to the patients' radiation therapy.

Freireich and associates⁸ reported three cases of refractory anemia, throm-

Table 2.—Summary of Chromosome Constitution of Marrow and Blood Cells in Cases of Myeloproliferative Syndrome without Overt Leukemia

Age	Sex	Source	Chromosome Number					Karyotype Analysis			Comments	Reference
			<45	45	46	47	48	Normal	Abnormal	Other		
36	F	Marrow + (2)	6	28				0	6	Deletion of long arm of D → G	Polycythemia vera; Rx-P-32 and x-radiation to spleen; mild thrombocytopenia	Nowell ¹⁶
		Blood + (2)	3	14			1	1	1	Fragments		
54	M	Marrow	2	2	45			0	7	Replacement of C chromosome by a short acrocentric, probably deletion of most of long arm of C group autosome	Polycythemia vera; Rx-x-ray to bone and spleen, P-32; WBC, 42,800; myelocytes, 12 per cent; metamyelocytes, 5 per cent	Solari ¹⁷
		Marrow	*	*	*					One C chromosome missing	Refractory anemia, thrombocytopenia, granulocytic hyperplasia of bone marrow	Freireich ¹⁸
		Blood and Skin								Data not given in abstract	Myelofibrosis-myeloid metaplasia	Kiossoglou ¹⁹
	F	Marrow Blood		*	*					Data not given in abstract	Polycythemia vera	Kemp ²⁰
23	M	Marrow + (2)	27	82	6			6	30	One C chromosome missing	Pancytopenia, hypocellular marrow	Present report, Case No. 1
		Blood + (2)	4	1	34	1		11	1	Two extra small chromosomes		
62	M	Marrow + (2)	11	11	20	79	3	5†	29	One extra C chromosome	Siderochrestic anemia	Case No. 2
		Blood	1	4	40	2	1	17	4	One to 3 extra small chromosomes or fragments of chromosomes		
59	F	Marrow + (3)	9	12	43	5	14	29	13	Two extra C chromosomes	Idiopathic thrombocytopenia	Case No. 3
		Blood	1	5	17			12	5†	Inconsistent abnormalities		

+ Combined results of several examinations, all of which yielded similar results. Numbers in parentheses indicate number of studies.

* Exact figure not given; indicates modal number stated in report.

† See discussion in text.

bocytopenia and marrow granulocytic hyperplasia, in which the marrow cells had only 45 chromosomes and one missing C group chromosome, whereas cultured peripheral blood and skin cells showed 46 chromosomes. Two of the three patients died of "acute myelomonocytic leukemia." These patients resemble our Case No. 1 with regard to cytogenetic findings, anemia, and thrombocytopenia, but our patient had a very hypocellular marrow.

Kiosoglou and Mitus,⁹ in a recent abstract describing chromosomal studies in chronic myeloproliferative syndromes, report that 14/14 patients with polycythemia vera and 2/2 with thrombocythemia had normal marrow karyotypes; 1/3 patients with myelofibrosis-myeloid metaplasia showed hyperdiploidy with an extra C group chromosome. Kemp¹⁰ has followed a patient for 4 years whose clinical diagnosis is polycythemia vera; a significant number of cells in her bone marrow have 48 chromosomes with 2 extra chromosomes in the C group, whereas peripheral blood cells and cells from fibroblast cultures contain the normal diploid number. She has shown no sign as yet of leukemic transformation.

If one considers only the five patients in the above-mentioned reports (Table 2) who, to date, have shown no sign of overt leukemia, 4 out of the 5 show abnormalities of C group chromosomes involving either deletion of most of the long arms of a C, monosomy, trisomy, or tetrasomy (or, alternatively, a double trisomy) for a C chromosome. Only one of Nowell and Hungerford's cases involved a chromosome of another group—namely, deletion of a portion of the long arms of a D chromosome which resulted in a chromosome resembling a G group autosome.

The addition of our three cases, each showing a different abnormality, but all involving a C group chromosome, reveals the remarkable association of aberrant C chromosomes with a diversity of hematologic disorders, many of which terminate in acute leukemia.

Reisman and co-workers have published a careful study of 8 cases of acute stem-cell leukemia in children in which serial observations were made during repeated relapses and intervening remissions.³ During remission, the normal diploid mode of 46 in marrow cells was invariably restored, regardless of the duration of the disease or the therapy employed. All patients, untreated or in relapse, had hyperdiploid modal numbers ranging from 47 to 65. In the second or third relapses studied, the originally observed aneuploid karyotype always reemerged after remissions of varying lengths up to 4 months. They concluded that a change in the chromosomal constitution of the malignant cell is one of the basic alterations in acute leukemia and is present in the earliest phases of the disease that can be investigated.

Our patients have changes in the chromosome constitution of marrow cells similar to those found in acute leukemia, and thus a crucial question to be asked about our 2 surviving patients is, will they develop leukemia? How long can a cell line be maintained with an abnormal genetic constitution which apparently continues to respond to homeostatic control mechanisms? If a patient can live for more than 7 months (as in Case No. 1) or for more than 4 years¹⁰ with a large proportion of bone marrow cells having an aneuploid num-

ber, then it would seem that a stable aneuploid cell line is not of itself sufficient for the development of leukemia.

On the other hand, Engel et al.'s report of 7 infants with Down's syndrome (mongolism) with transient congenital leukemia³⁰ suggests that aneuploidy and leukemia may be reversible in rare instances. One child was considered to have acute myelogenous leukemia diagnosed on the tenth day of life on the basis of hepatosplenomegaly, ecchymoses, white blood cell count of 34,400 with 36 per cent blasts and a platelet count of less than 10,000. Bone marrow examination showed 40 per cent granulocytes and 33 per cent primitive mononuclear cells. The modal chromosome number in a direct marrow preparation was 57. A complete hematologic remission without therapy was noted in 3 months and the child was still well at 3 years of age. Marrow chromosome examination in remission revealed 47 chromosomes with trisomy 21 which is "usual" for Down's syndrome. Karyotyping was not done on the other 6 cases during the initial "leukemic" phase; 4 of the children were examined in remission and had the standard trisomy 21.

Our patients are clinically quite dissimilar, one having aplastic anemia possibly due to chloramphenicol; the second, idiopathic sideroachrestic anemia; the third, idiopathic thrombocythemia. All three conditions are related in their predisposition to terminate in acute leukemia,^{4,31,32} a predisposition which also characterizes the 5 cases reported by others and summarized above.

It is possible that a leukemogenic agent (for example, virus, radiation or chemical carcinogen) acts initially to alter the genetic constitution of the cell. This altered genome may be reflected in a gross change in the chromosomes which results in the gain or loss of a chromosome or in the deletion of part of a chromosome. A genetically significant chromosomal deletion could occur which would be undetected by our current, relatively insensitive technics. However, while our data suggest that an altered chromosome number does not of itself denote a neoplastic change, a stable aneuploid stem line may provide a more propitious milieu for the original agent or a different agent to transform abnormal, but still partially controllable, cells to abnormal but autonomous cells.

The significance of the observation that all 3 of our cases, plus 4 of the 5 cases of others, involve abnormalities of group C chromosomes may now be considered. Patau³³ has shown that the variation in size between known homologous chromosomes may be greater than the difference in size between adjacent pairs of chromosomes in group C. Because of the uncertainties attending the exact identification of group C chromosomes, specific identification of the missing C chromosome in Case No. 1 and the duplicated C chromosome(s) in Cases 2 and 3 is not possible at present. It is conceivable that the same chromosome is involved in all three cases. It is also worth noting that many cases of aneuploidy in acute leukemia involve C group chromosomes.¹ In part, this probably results from the larger number of chromosomes present in the C group. It is also possible that genes responsible for the homeostatic control of hemopoietic tissue are located on one or more C group chromosomes. Any alteration in the number of C group chromosomes, whether by an increase or a decrease, may change the genetic balance of the system and thus disturb the

normal homeostatic control of hemopoiesis. This would account for the observations that deletion as well as duplications of C group chromosomes seem to be associated with hematologic disorders, many of which terminate in acute leukemia. However, the determination of the possible relationship between C group aneuploidy and acute leukemia and related hematopoietic disorders depends on the accumulation of more case reports. Much valuable information could be obtained from the publication of similar cases of chromosome abnormalities observed in patients without overt signs of malignant neoplasia.

SUMMARY

Three patients with different obscure hematologic disorders are presented. All 3 patients had abnormalities of chromosome number confined to marrow cells. Case 1 is a 23-year-old man with aplastic anemia; most of his bone marrow cells contained 45 chromosomes, with one missing from group C. Case 2 is a 62-year-old man who died of idiopathic sideroachrestic anemia; most of his bone marrow cells contained 47 chromosomes with an extra C group chromosome which appeared to be an autosome. Case 3 is a 59-year-old woman with idiopathic thrombocythemia; while the majority of her bone marrow cells contained 46 chromosomes, a stable minority cell line had 48 chromosomes.

Although many of the reported patients with myelodysplastic-myeloproliferative disorders have normal chromosomes, 5 cases with some chromosomal aberration, previously reported by others, are summarized. None of these patients had clinical evidence of leukemia. In 4 of the patients, the chromosomal anomaly involved a chromosome in group C, which is the group in which aneuploidy occurred in all 3 of our patients.

It is postulated that a stable, aneuploid stem line does not of itself produce neoplasia, but rather that this alteration of the genome may provide a more favorable milieu for the action of some transforming agent. Because of the frequent occurrence of C group abnormalities in these cases of marrow disorders, it is further postulated that genes on one or more C chromosomes might be responsible for homeostatic control of hemopoiesis, and that a change in genetic balance involving a C group chromosome(s) coupled with a transforming agent might result in leukemia in a greater proportion of individuals than aneuploidy of some other chromosomal group.

SUMMARIO IN INTERLINGUA

Es presentate le casos de 3 patientes con differente disordines hematologic de natura obscur. Omne le 3 patientes habeva anormalitates del numeros del chromosomas solmente in le cellulas medullari. Caso No. 1 es un masculo de 23 annos de etate con anemia aplastic. Le majoritate de su cellulas de medulla ossee contineva 45 chromosomas, i.e., un chromosoma mancava in gruppo C. Case No. 2 es un masculo de 62 annos de etate qui moriva de idiopathic anemia sideroachrestic. Le majoritate de su cellulas de medulla ossee contineva 47 chromosomas, i.e., ille habeva un chromosoma supernumerari de gruppo C le qual pareva esser un autosoma. Caso No. 3 es un femina de 59 annos de etate

con thrombocythemia idiopathic. Durante que le majoritate de su cellulas de medulla ossee contine 46 chromosomas, un stabile linea de cellulas habeva 48.

Ben que multes del reportate pacientes con disordines myelodysplastic-myeloproliferative ha chromosomas normal, 5 casos con le un o le altere aberration chromosomatic, previamentee reportate per alteres, es summarisate. Nulle de iste pacientes manifestava evidencia clinic de leucemia. In 4, le anormalitate chromosomatic concerneva un chromosoma de gruppo C, i.e., le gruppo in le qual aneuploidia occorreva in omne nostre 3 patientes.

Es postulate que un stabile aneuploidic linea primordial non produce per se neoplasia sed que, plus tosto, iste alteration del genoma provide un plus favorable ambiente pro le action de un agente transformatori. Viste le frequente occurrentia de anormalitates del gruppo C in iste casos de disordines medullari, il es postulate in plus que genes in un o plure chromosomas de gruppo C es responsabile pro le regulation homeostatic del hemopoiese e que un alteration in le balancia genetic afficiente un chromosoma o plure chromosomas del gruppo C pote, in le presentia de un agente transformatori, resultar in leucemia in un plus grande proportion de subjectos que aneuploidia in un del altere gruppos chromosomatic.

ACKNOWLEDGMENTS

We wish to make the following acknowledgments: To Drs. Ernest Beutler, Fred H. Katz, Gerald A. Mendel, H. Paul Miller, and Stanley Yachnin, for referring the patients reported and for making available special material in each case; to Drs. James E. Bowman and Paul E. Carson for the Xg^a blood typing and red cell enzyme determinations in Case 1; and to Dr. Margot Doyle and Mrs. Frances Skozen for invaluable editorial assistance.

ADDENDUM

Skin cultures obtained from Case No. 2 became contaminated and no mitotic cells were obtained. No labeled metaphases were obtained from Case No. 2; only one late-labeling C group chromosome was found in Case No. 3. More recent studies on Case No. 3 are in press in *The Lancet*.

REFERENCES

1. Sandberg, A. A., Ishihara, T., Kikuchi, Y., and Crosswhite, L. H.: Chromosome differences among the acute leukemias. *Ann. N. Y. Acad. Sci.* 113:663. 1964.
2. Reisman, L. E., Mitani, M., and Zuelzer, W. W.: Chromosome studies in leukemia. I. Evidence for the origin of leukemic stem lines from aneuploid mutants. *New Eng. J. Med.* 270:591. 1964.
3. Reisman, L. E., Zuelzer, W. W., and Thompson, R. I.: Further observation on the role of aneuploidy in acute leukemia. *Cancer Res.* 24:1448. 1964.
4. Blaisdell, R. K., and Jacobson, L. O.: The diversity of preacute leukemic syndromes (abstract). *Amer. Soc. Hemat., 8th Annual Meeting, Dec., 1965.*
5. Blaisdell, R. K., Hrubec, Z., Ichimaru, M., Hoshiro, T., Nakamura, R. M.: Aplastic anemia as a late radiation effect: a clinical, pathological and epidemiological study of Hiroshima and Nagasaki atomic bomb survivors. Atomic Bomb Casualty Commission Technical Report. (To be published.)
6. Nowell, P. C., and Hungerford, D. A.: Chromosome studies in human leukemia. IV. Myeloproliferative syndrome and other atypical myeloid disorders. *J. Nat. Cancer Inst.* 29:911. 1962.
7. Solari, A. J., Sverdlick, A. B., and Viola, E. R.: Chromosome abnormality in myeloid metaplasia. *Lancet* 2:613. 1962.
8. Freireich, E. J., Whang, J., Tjio, J. N., Levin, R. H., Britten, G. M., and Frei,

- E., III: Refractory anemia, granulocytic hyperplasia of bone marrow, and a missing chromosome in marrow cells (abstract). *Clin. Res.* 12:284. 1964.
9. Kiosoglou, K. A., and Mitus, W. J.: Chromosomal studies in chronic myeloproliferative syndromes (abstract). *Clin. Res.* 13:276, 1965.
 10. Kemp, N. H.: Personal communication.
 11. Sandberg, A. A., Ishihara, T., and Crosswhite, L. H.: Group C trisomy in myeloid metaplasia with possible leukemia. *Blood* 24:716. 1964.
 12. Sandberg, A. A., Koepf, G. F., Crosswhite, L. H., and Hauschka, T. S.: The chromosome constitution of human marrow in various developmental and blood disorders. *Amer. J. Hum. Genet.* 12:231. 1960.
 13. Tjio, J. H., and Whang, J.: Chromosome preparations of bone marrow cells without prior in vitro culture or in vivo colchicine administration. *Stain Technol.* 37:17, 1962.
 14. Rothfels, K. H., and Siminovitch, L.: An air-drying technique for flattening chromosomes in mammalian cells grown in vitro. *Stain Technol.* 33:73. 1958.
 15. Moorhead, P. S., Nowell, P. C., Mellman, W. J., Battips, D. M., and Hungerford, D. A.: Chromosome preparations of leukocytes cultured from human peripheral blood. *Exp. Cell Res.* 20:613. 1960.
 16. Ross, A.: The demonstration of sex chromatin in buccal smears. *J. Med. Lab. Tech.* 17:178. 1960.
 17. Bessis, M. C., and Jensen, W. N.: Sideroblastic anemia, mitochondria and erythroblastic iron. *Brit. J. Haemat.* 11:49, 1965.
 18. Sandberg, A. A., Ishihara, T., Crosswhite, L. H., and Hauschka, T. S.: Chromosomal dichotomy in blood and marrow of acute leukemia. *Cancer Res.* 22:748. 1962.
 19. Mann, J. D., Cahan, A., Gelb, A. G., Fisher, N., Hamper, J., Tippet, P., Sanger, R., and Race, R. R.: A sex-linked blood group. *Lancet* 1:8. 1962.
 20. Childs, B., Zinkham, W. H., Browne, E. A., Kimbro, E. L., and Torbert, I. V.: A genetic study of a defect in glutathione metabolism of the erythrocyte. *Bull. Hopkins Hosp.* 102:21. 1958.
 21. Rowley, J., Muldal, S., Gilbert, C. W., Lajtha, L. G., Lindsten, J., Fraccaro, M., and Kaijser, K.: Synthesis of deoxyribonucleic acid on X-chromosomes of an XXXXY male. *Nature* 197:251. 1963.
 22. Jacobs, P. A., Buckton, K. E., Harnden, D. G., Court Brown, W. M., King, M. J., McBride, J. A., MacGregor, T. N., and Maclean, N.: Cytogenetic studies in primary amenorrhoea. *Lancet* 1: 1183. 1961.
 23. Pfeiffer, R. A., Schellong, G., and Kosnow, W.: Chromosomenanomalien in den Blutzellen eines Kindes mit multiplen Abartungen. *Klin. Wechr.* 40:1058. 1962.
 24. El-Alfi, O. S., Powell, H. C., and Biese, J. J.: Possible trisomy in chromosome group 6-12 in a mentally retarded patient. *Lancet* 1:700. 1963.
 25. Stalder, G. R., Buhler, E. M., and Weher, J. R.: Possible trisomy in chromosome group 6-12. *Lancet* 1: 1379, 1963.
 26. Stolte, L., Evers, J., and Blankenborg, G.: Possible trisomy in chromosome group 6-12 in a normal woman. *Lancet* 2:480. 1964.
 27. Tough, I. M., Jacobs, P. A., Court Brown, W. M., Baikie, A. G., and Williamson, E. R. D.: Cytogenetic studies on bone marrow in chronic myeloid leukemia. *Lancet* 1:844. 1963.
 28. Goh, K., and Swisher, S. N.: Specificity of the Philadelphia Chromosome. *Ann. Intern. Med.* 61:609. 1964.
 29. Bender, M. A., and Gooch, P. C.: Persistent chromosome aberrations in irradiated human subjects. *Rad. Res.* 16:44. 1962.
 30. Engel, R. R., Hammond, D., Eitzman, D. V., Pearson, H., and Krivit, W.: Transient congenital leukemia in 7 infants with mongolism. *J. Pediat.* 65: 303, 1964.
 31. Bjärkman, S. E.: Chronic refractory anemia with sideroblastic bone marrow. A study of four cases. *Blood* 11:250. 1956.
 32. Heilmeyer, L.: *Disturbances of Heme Synthesis*. Springfield, Ill., Charles C Thomas, Publisher. 1964.
 33. Patau, K.: Identification of individual chromosomes especially in man. *Amer. J. Hum. Genet.* 12:250. 1960.