blood work
images in hematology

Vacuolated lymphocytes, a leading piece of diagnostic evidence for a rare storage disorder

Elham Jamali, Peyvand Pathobiology and Genetic Lab Complex; and Reza Ranjbaran, Shiraz University of Medical Sciences

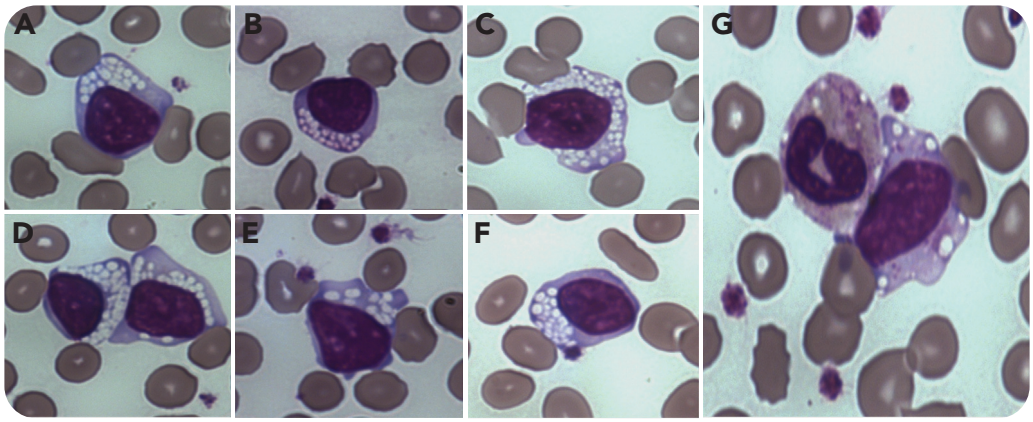

A 7-year-old girl presented with coarse facial features, cardiomegaly, intellectual disability, seizures, and macular cherry red spot. A mucopolysaccharidosis (MPS) disorder was suspected. Hepatosplenomegaly was absent. A comprehensive metabolic panel revealed normal kidney, liver, and thyroid function (thyrotropin: 1.75 µU/mL; T4: 9.5 µg/dL; blood urea nitrogen: 17 mg/dL; creatinine: 0.38 mg/dL), and the level of glycosaminoglycans in urine was normal (urine MPS: 4.2 mg/mmol creatinine), which excludes most of the common MPS disorders. Hematologic parameters showed hemoglobin:11.8 g/dL; white blood cells: 4.48 × 10^9/L; platelets: 234 × 10^9/L. There was mild neutropenia (absolute neutrophil count: 1.75 × 10^9/L). However, the blood film showed prominent cytoplasmic vacuoles in peripheral blood lymphocytes (panels A-F; 100× objective, total magnification ×1000; Wright's stain) suggestive of a storage disorder. Whole exome sequencing revealed a diagnosis of galactosialidosis due to homozygous mutations in the *CTSA* gene (c.556C>A: p. P186T).

Lysosomal storage disorders (LSDs) are a group of rare inherited diseases, and patients frequently encounter delay in diagnosis. Cytoplasmic vacuoles in neutrophils and monocytes are seen in a variety of conditions due to the phagocytic function of these cells (panel G; 100× objective, total magnification ×1000; Wright's stain). Vacuoles in mature lymphocytes should raise suspicion of an LSD.

https://doi.org/10.1182/blood.2023019735