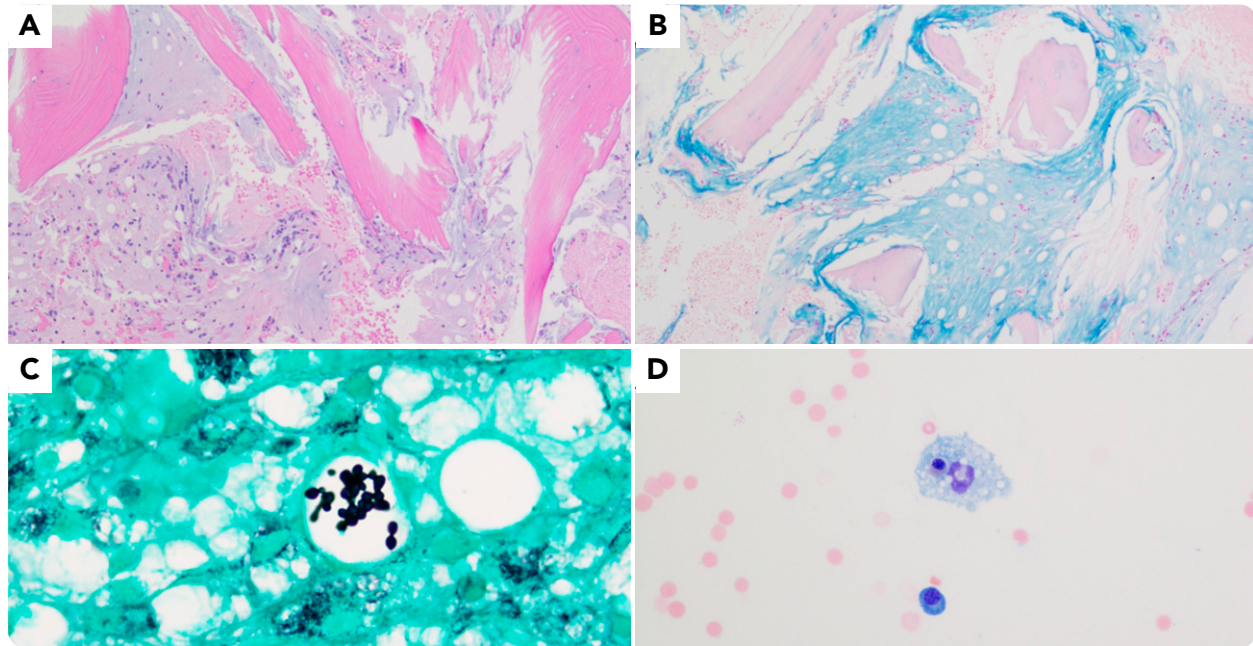


## Gelatinous transformation of bone marrow and concomitant fungal infection in a patient with HIV

Sri Bharathi Kavuri and Kirill A. Lyapichev, The University of Texas Medical Branch



A 61-year-old homeless woman with untreated HIV infection and severe malnutrition was admitted to the hospital following a fall. On admission, she was found to have severe pancytopenia and CD4 count of 28 cells per  $\mu\text{L}$ , for which bone marrow biopsy was performed. Biopsy revealed bone marrow replacement by a gelatinous material, which stained positive with Alcian blue (panel A; 10 $\times$  objective,  $\times$ 100 magnification; hematoxylin and eosin stain; panel B; 10 $\times$  objective,  $\times$ 100 magnification; Alcian blue stain). In addition, Grocott methenamine silver (GMS) staining revealed multiple fungal organisms contained within vacuoles in the bone marrow (panel C; 100 $\times$  objective,  $\times$ 1000 magnification; GMS stain). Concomitantly, the patient was tested positive for *Histoplasma* antigen, supporting the special stain findings. Immunostaining for

human herpesvirus 8 returned negative. Bone marrow aspirate revealed polytypic plasma cells and hemophagocytosis (panel D; 40 $\times$  objective,  $\times$ 400 magnification; hematoxylin and eosin stain), which could be related to either HIV infection or fungal infection.

Gelatinous bone marrow transformation is a rare but well-documented entity characterized by adipocyte atrophy and deposition of extracellular gelatinous substance in the bone marrow, adversely affecting hematopoiesis. This gelatinous substance stains positive with Alcian blue, indicating the presence of acidic mucin. This interesting case demonstrates gelatinous bone marrow transformation in a severely malnourished HIV patient with concomitant histoplasma infection and hemophagocytosis.