

*SF3B1* MT patients compared with 40% among those with WT.<sup>5</sup> Recent data from a phase 2 clinical study with imetelstat suggest potential preferential and disease modifying activity among small number of *SF3B1* MT patients.<sup>6</sup>

We reclassified our patients based on IWG *SF3B1* new proposal criteria.<sup>1</sup> Notably, 175 patients were classified as MDS-*SF3B1* by the new proposed criteria, 145 patients with *SF3B1* MT not meeting the new proposed criteria, and 1412 *SF3B1* WT MDS patients (Table 1). The median OS was 120 months (95% CI, 77-164 months), 55 months (95% CI, 42-69 months), and 31.5 months (95% CI, 28-35 months), respectively ( $P < .005$ ; Figure 1C). The median leukemia-free survival was not reached among all *SF3B1* MT patients compared with 58 months among *SF3B1* WT patients ( $P < .005$ ) (Figure 1D). The rate of AML transformation was 4.7%, 22%, and 38%, respectively ( $P < .005$ ). t-MDS was observed in 10%, 9%, and 17% of the 3 above-mentioned groups. Excluding t-MDS, the median OS was 142, 57, and 36 months, respectively ( $P < .005$ ). There was no difference in response rates to erythroid stimulating agents, hypomethylating agents, and lenalidomide between patients classified as *SF3B1* by IWG new criteria compared with other *SF3B1* MT MDS.

In summary, we confirm and validate the findings reported recently by Malcovati et al that *SF3B1* MT MDS should be classified as a unique disease entity based on the new proposal criteria. Furthermore, we demonstrate that *SF3B1* MT retained favorable prognostic value in the context of t-MDS and worse outcome among patients with isolated del(5q), and we compliment the IWG findings by reporting responses to current available therapies based on *SF3B1* MT status.

## Authorship

Contribution : R.K. wrote the manuscript, designed the research study, and analyzed and interpreted data; V.V., O.C., N.A.A., and D.S. collected and analyzed data and approved the final manuscript; E.P. designed the research study and approved the final manuscript; and D.A.S. reviewed data, designed the research study, and approved the final manuscript.

Conflict-of-interest disclosure : R.K. received speakers bureau fees from Jazz Pharma, Bristol Myers Squibb, and Agios and honoraria

from Jazz Pharma, Bristol Myers Squibb, Geron, AbbVie, Incyte, Acceleron, and Novartis. E.P. received honoraria from Novartis and research funding from Incyte, Kura, and BMS. D.S. received research funding from Celgene and Jazz Pharma and consultancy fees from Agios, Bristol Myers Squibb, Celyad Oncology, Incyte, Intellia Therapeutics, Kite Pharma, Novartis, and Syndax. The remaining authors declare no competing financial interests.

ORCID profiles: R.S., 0000-0002-1876-5269; O.C., 0000-0003-2872-1961; D.M., 0000-0002-6102-1695.

Correspondence: Rami Komrokji, H. Lee Moffitt Cancer Center, 12902 Magnolia Dr, CSB7, Tampa, FL 33612; e-mail: rami.komrokji@moffitt.org.

## Footnote

Submitted 15 January 2021; accepted 23 April 2021; prepublished online on *Blood* First Edition 25 May 2021.

## REFERENCES

1. Malcovati L, Stevenson K, Papaemmanuil E, et al. *SF3B1*-mutant MDS as a distinct disease subtype: a proposal from the international working group for the prognosis of MDS. *Blood*. 2020;136(2):157-170.
2. Swoboda DM, Lee J-H, Chan O, et al. Marrow ring sideroblasts are highly predictive for TP53 mutation in MDS with excess blasts. *Blood*. 2019; 134(suppl 1):4244.
3. Zhang Q, Haider M, Al Ali NH, et al. *SF3B1* mutations negatively predict for response to immunosuppressive therapy in myelodysplastic syndromes. *Clin Lymphoma Myeloma Leuk*. 2020;20(6):400-406.e2.
4. Fenaux P, Platzbecker U, Mufti GJ, et al. Luspatercept in patients with lower-risk myelodysplastic syndromes. *N Engl J Med*. 2020;382(2):140-151.
5. Platzbecker U, Germing U, Götze KS, et al. Luspatercept for the treatment of anaemia in patients with lower-risk myelodysplastic syndromes (PACE-MDS): a multicentre, open-label phase 2 dose-finding study with long-term extension study. *Lancet Oncol*. 2017;18(10):1338-1347.
6. Steensma DP, Fenaux P, Van Eygen K, et al. Imetelstat achieves meaningful and durable transfusion independence in high transfusion-burden patients with lower-risk myelodysplastic syndromes in a phase II study. *J Clin Oncol*. 2021;39(1):48-56.

DOI 10.1182/blood.2021010831

© 2021 by The American Society of Hematology

## TO THE EDITOR:

# The use of IV immunoglobulin in the treatment of vaccine-induced immune thrombotic thrombocytopenia

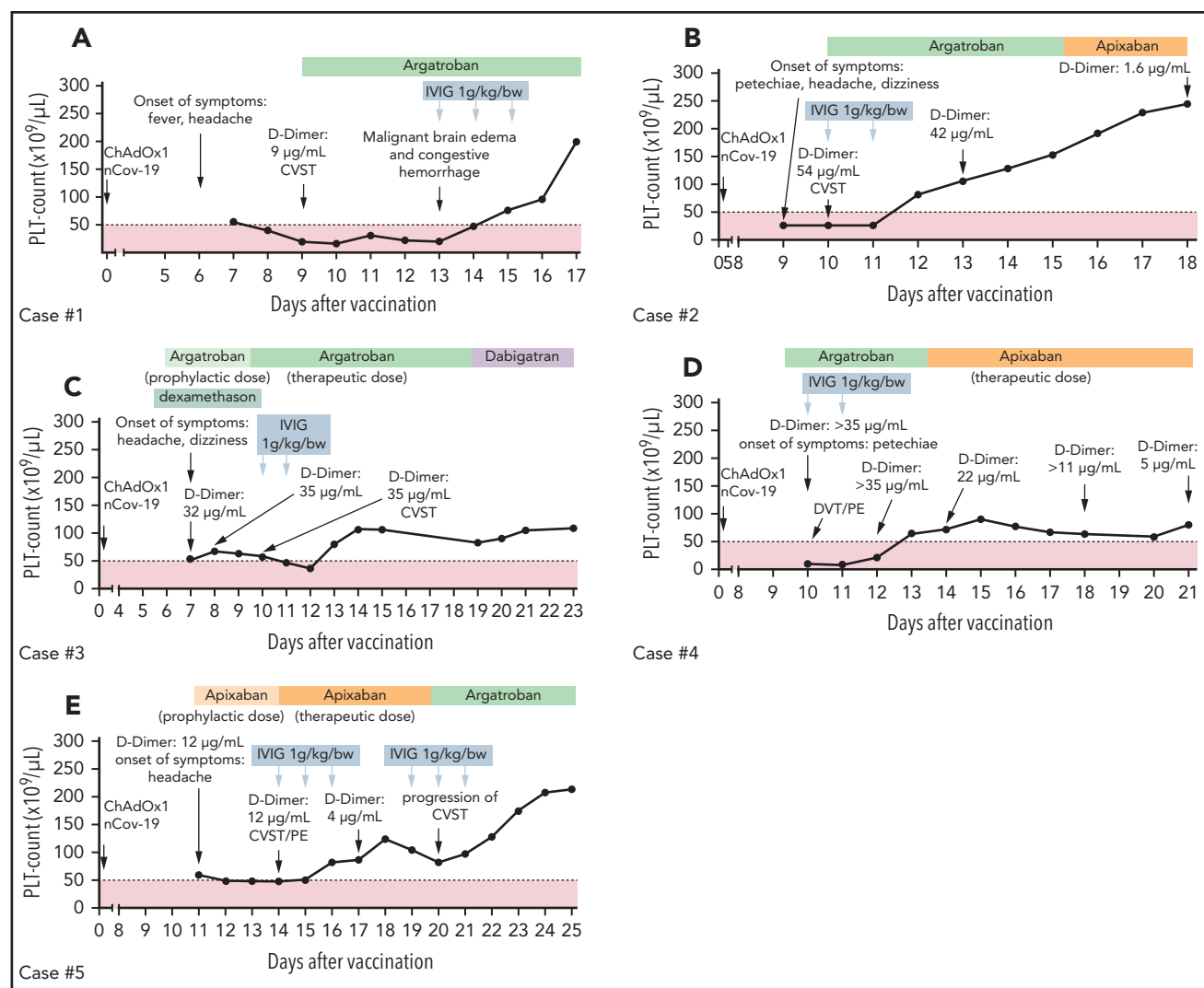
Günalp Uzun,<sup>1</sup> Karina Althaus,<sup>1,2</sup> Anurag Singh,<sup>2</sup> Peter Möller,<sup>3</sup> Ulf Ziemann,<sup>4</sup> Annerose Mengel,<sup>4</sup> Peter Rosenberger,<sup>5</sup> Martina Guthoff,<sup>6</sup> Gabor C. Petzold,<sup>7</sup> Jens Müller,<sup>8</sup> Martin Büchsel,<sup>9</sup> Katharina Feil,<sup>4</sup> Hans Henkes,<sup>10</sup> Nils Heyne,<sup>6</sup> Matthias Maschke,<sup>11</sup> Caroline Limpach,<sup>11</sup> Simon Nagel,<sup>12</sup> Ulrich J. Sachs,<sup>13</sup> Falko Fend,<sup>14</sup> and Tamam Bakchoul<sup>1,2</sup>

<sup>1</sup>Center for Clinical Transfusion Medicine, Tuebingen, Germany; <sup>2</sup>Institute for Clinical and Experimental Transfusion Medicine, Medical Faculty of Tuebingen, University Hospital of Tuebingen, Tuebingen, Germany; <sup>3</sup>Institute for Pathology, University Hospital of Ulm, Ulm, Germany; <sup>4</sup>Department of Neurology & Stroke, Eberhard-Karls University, Tuebingen, Germany; <sup>5</sup>Department of Anaesthesiology and Intensive Care Medicine, University Hospital of Tuebingen, Tuebingen, Germany; <sup>6</sup>Department of Internal Medicine IV, Section of Nephrology and Hypertension, University Hospital of Tuebingen, Tuebingen, Germany; <sup>7</sup>Division of Vascular Neurology and <sup>8</sup>Institute for Experimental Hematology and Transfusion Medicine, University Hospital Bonn, Bonn, Germany; <sup>9</sup>Institute of Clinical Chemistry and Laboratory Medicine, Medical Centre–University of Freiburg, Freiburg im Breisgau, Germany; <sup>10</sup>Department of Neuroradiology, Klinikum Stuttgart, Stuttgart, Germany; <sup>11</sup>Department of Neurology, Krankenhaus der Barmherzigen Brüder Trier, Trier, Germany; <sup>12</sup>Department of Neurology, University Hospital Heidelberg, Heidelberg, Germany; <sup>13</sup>Department of Thrombosis and Hemostasis, Institute of Immunology and Transfusion Medicine, Giessen, Germany; and <sup>14</sup>Institute for Pathology and Neuropathology, University Hospital of Tuebingen, Tuebingen, Germany

The ChAdOx1 nCoV-19 is a recombinant chimpanzee adenoviral vector vaccine encoding the spike glycoprotein of severe acute respiratory syndrome coronavirus 2, which has a good efficacy rate and safety profile.<sup>1</sup> Over the past 2 months, concern has been raised over reported thrombotic events associated with thrombocytopenia after ChAdOx1 nCoV-19 vaccination, a complication called vaccine-induced immune thrombotic thrombocytopenia (VITT).<sup>2-6</sup> The pathophysiology of VITT is still unclear but seems to be similar to spontaneous autoimmune heparin-induced thrombocytopenia (aHIT).<sup>2,7</sup> In fact, as in aHIT, VITT patients develop platelet factor-4 (PF4) antibodies without any recent exposure to heparin. These antibodies are able to activate platelets and induce procoagulant platelet phenotype via cross-linking the Fc  $\gamma$  receptor IIA on platelet surface. IV immunoglobulin (IVIg) has been successfully used in the treatment of spontaneous aHIT.<sup>8,9</sup> We and others have recently shown that IVIg inhibits the in vitro induction of procoagulant platelet phenotype by sera from VITT patients.<sup>2,7</sup> Herein, we report our clinical experience on the use of IVIg in the management of

VITT and present novel laboratory analysis of the effect of IVIg therapy on anti-PF4 antibody level and platelet activation in VITT patients.

The study cohort consisted of patients who were admitted to our hospitals between February 1 and May 5, 2021 with suspected VITT due to neurological or hematological symptoms after first immunization with ChAdOx1 nCoV-19 (Vaxzevria; AstraZeneca, London, United Kingdom). The diagnosis of VITT was serologically confirmed according to the recommendations of the International Society on Thrombosis and Haemostasis Scientific and Standardization Subcommittee on Platelet Immunology,<sup>10</sup> using an immunoglobulin G (IgG)-enzyme immune assay (EIA) to detect IgG antibodies against PF4 (Hyphen Biomed, Neuville-sur-Oise, France). The ability of the sera to activate platelets was tested using a modified heparin-induced platelet aggregation assay as previously described.<sup>7</sup> Sera-induced procoagulant platelets were analyzed using flow cytometer as previously described.<sup>11</sup> For more details, see the supplemental material, available on the



**Figure 1. Individual course of the platelet counts and therapies.** Five cases (A-E) of VITT after severe acute respiratory syndrome coronavirus 2 vaccination were identified. Patients were treated with nonheparin anticoagulation (argatroban, green blocks; danaparoid, lavender blocks; direct oral anticoagulants, orange blocks) combined with IVIg. Patients receiving therapeutic anticoagulation with platelet counts below  $50 \times 10^9/L$  (dashed line) were considered to be at enhanced risk for major hemorrhage. CSVT, cerebral sinus vein thrombosis; DVT, deep vein thrombosis; PE, pulmonary embolism; PLT, platelet.

Blood Web site. The study was conducted in accordance with the Declaration of Helsinki. The study protocol was approved by the Institutional Review Board of the University of Tuebingen (236/2021BO1). We used GraphPad Prism, version 7.0 (GraphPad, La Jolla, CA) for statistical analysis. A value of  $P < .05$  was accepted as statistically significant.

Five patients (3 females) with a median age of 47 years (range, 20-57) were included in this study. The duration between vaccination and hospital admission was 7 to 9 days. All patients had severe thrombocytopenia ( $41.2 \pm 9.7 \times 10^9/L$ ; range, 10-60; Figure 1A-E) and increased D-dimer ( $9 \mu g/mL$  or higher; range, 9-54). At admission, several thrombotic events, including cerebral venous sinus thrombosis (CVST; 4 patients, cases 1-3 and 5), pulmonary embolism (2 patients, cases 4 and 5), and deep vein thrombosis (case 4), were detected. Detailed case descriptions and patient characteristics are given in the supplemental methods and in supplemental Table 1A. VITT diagnosis was confirmed by detecting anti-PF4 IgG antibodies in EIA (optical density [OD]  $2.98 \pm 0.23$ ; range, 2.07-3.36), platelet activation in the modified heparin-induced platelet aggregation assay (median time to platelet aggregation, 5 minutes; range, 5-5 minutes), and formation of procoagulant platelets (CD62p/PS<sup>+</sup> platelets mean:  $45 \pm 7$ ; range, 23-66). Laboratory investigations at admission and after IVIG therapy are presented in supplemental Table 1B.

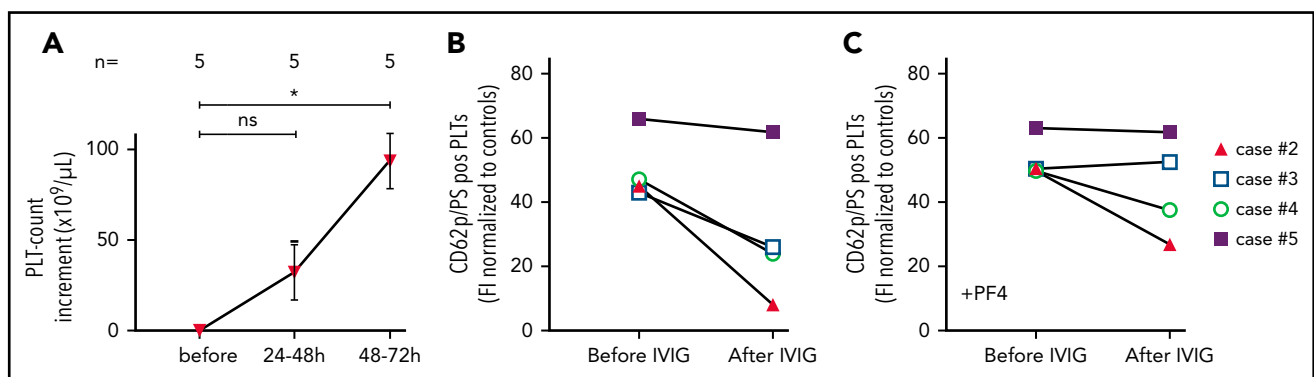
All patients received parenteral anticoagulation with argatroban ( $n = 4$ ) or danaparoid ( $n = 1$ ), and 1 patient (case 5) initially received apixaban. Two patients (cases 3 and 5 on a prophylactic dose of argatroban and apixaban, respectively) developed a new thromboembolic complication at day 4 and 3 of hospitalization (before IVIG administration), respectively. Anticoagulation was continued in these patients with argatroban in a therapeutic dosage (Figure 1C,E).

IVIG was administered at a dose of 1 g/kg body weight for 2 to 5 days. Median of total IVIG dose was 140 g (range, 95-600 g). Absolute platelet increment was  $32.6 \pm 17.1 \times 10^9/L$  within 48 hours ( $P$  vs baseline, .12) and  $94.2 \pm 23.3 \times 10^9/L$  within 72 hours after IVIG ( $P$  vs baseline, .01; Figure 2A). A complete platelet response (platelet count  $\geq 100 \times 10^9/L$ ) was achieved in 4 patients

within 96 hours. One patient had a platelet response (platelet count  $\geq 30 \times 10^9/L$  and at least twofold increase the baseline count) within 72 hours after IVIG therapy. From a clinical perspective, increasing the platelet count is important in thrombocytopenic patients requiring therapeutic anticoagulation. This is most critical when thrombosis occurs at unusual sites, such as CVST, because of the increased mortality risk due to hemorrhagic transformation after an arterial stroke or CVST. In our cohort, 1 patient (case 1) suffering from VITT-associated CVST had postthrombotic hemorrhage during the thrombocytopenic period, prior to receiving IVIG.

Successful use of IVIG in the treatment of aHIT has been reported.<sup>8,9,12</sup> Mainly because of similarities between aHIT and VITT, recent societal guidelines recommend the use of IVIG in VITT with the assumption that IVIG could mitigate the platelet activation induced by anti-PF4 antibodies and thus reduce the platelet consumption and the development of new thrombosis.<sup>10,13,14</sup> However, concerns of increased new thrombotic events limit its use.<sup>15</sup> Serial D-dimer levels were available from 3 cases, and all of them showed a decrease within 72 hours after IVIG therapy (Figure 1). We observed progression of CVST in 1 patient (case 5). Other patients receiving nonheparin anticoagulation at therapeutic doses combined by IVIG did not develop new thrombosis, indicating sufficient antithrombotic efficacy. Similarly, Thaler et al successfully used IVIG (1 g/kg for 2 consecutive days) and argatroban in a patient with VITT.<sup>16</sup> Tiede et al reported a positive platelet response in 3 VITT patients after IVIG therapy (1 g/kg for 2 consecutive days).<sup>5</sup> However, 2 patients developed new thromboembolic events (extensive splanchnic vein thrombosis and popliteal artery occlusion).<sup>5</sup> New thromboembolic events are common in patients with VITT.<sup>5-7</sup> Therefore, clinicians should pay attention to dynamic changes in clinical as well as laboratory parameters and exercise extra vigilance in VITT patients in order to detect new thromboembolic events in a timely manner.

To assess the mechanism by which high-dose IVIG downregulates hypercoagulability in VITT, we analyzed the ability of VITT patients' sera to generate procoagulant platelets before and after IVIG therapy. The reactivity in PF4 EIA did not change significantly after IVIG administration ( $n = 4$ ,  $3.21 \pm 0.06$  OD vs  $3.18 \pm 0.08$  OD;  $P$ : .798; supplemental Table 1B). On the other hand, the



**Figure 2. Effect of IVIG therapy on PLT count and procoagulant platelets.** Platelet count increment (A) and procoagulant platelets after IVIG therapy (B-C). Procoagulant platelets (CD62p/Phosphatidylserine [PS]<sup>+</sup>) were analyzed in patients before and after IVIG therapy via Annexin V-FITC and CD62p-APC antibody staining. Where indicated, PLTs were pretreated with PF4 (C). Data are presented as fold increase compared with healthy control. ns, not significant. \* $P < .05$ . The number of sera tested is reported in each graphic.

ability of the sera from VITT patients to induce procoagulant platelets reduced after IVIG therapy in 3 cases in the absence and in 2 out of 4 cases in the presence of PF4 (Figure 2B-C; supplemental Table 1B). Noteworthy, diluted sera showed specific platelet activation only in the presence of PF4 (supplemental Figure 1A-D). These data suggest that IVIG interferes with the pathogenic anti-PF4 antibodies by competing with them to bind to Fc  $\gamma$  receptor IIA receptors, which might be in vivo associated with reductions in platelet activation and disseminated intravascular coagulation. The later ones are confirmed in our study by the rapid response in platelet count and decrease in D-dimer levels.<sup>7,9</sup> However, the effect of IVIG on other cells cannot be ruled out as another explanation for the observed therapeutic benefit.

In summary, we showed that high-dose IVIG inhibits antibody-mediated procoagulant platelet generation, rapidly increases the platelet count, and finally, deescalates the hypercoagulable state in VITT. Adjunct use of IVIG can be recommended as a therapeutic option to prevent disease progression.

## Acknowledgments

This work was supported by grants from the German Research Foundation and from the Herzstiftung BA5158/4 and TSG-Study (T.B.), by special funds from the state of Baden-Württemberg for autopsy-based COVID-19 research, and the DEFEAT PANDEMIcs network funded by the BMBF (Federal Ministry of Education and Research) (P.M. and F.F.).

## Authorship

Contribution: G.U., K.A., and T.B. designed the study; P.M., U.Z., A.M., P.R., M.G., G.C.P., J.M., M.B., K.F., H.H., N.H., M.M., C.L., and S.N. were responsible for the treatment of the patients and collected and analyzed the clinical data; G.U., K.A., U.J.S., F.F., and T.B. reviewed medical reports; G.U., K.A., and A.S. performed the experiments; G.U., K.A., A.S., and T.B. analyzed the data, interpreted the results, and wrote the manuscript; and all authors read and approved the manuscript.

Conflict-of-interest disclosure: T.B. has received research funding from CoaChrom Diagnostica GmbH, DFG, Robert Bosch GmbH, Stiftung Transfusionsmedizin und Immunhämatologie eV, Ergomed, Surrey, DRK Blutspendedienst, Deutsche Herzstiftung, Ministerium fuer Wissenschaft, Forschung und Kunst Baden-Wuerttemberg, has received lecture honoraria from Aspen Germany GmbH, Bayer Vital GmbH, Bristol Myers Squibb GmbH & Co, Doctrina Med AG, Meet the Experts Academy UG, Schoechl Medical Education GmbH, Mattsee, Stago GmbH, Mitsubishi Tanabe Pharma GmbH, Novo Nordisk Pharma GmbH, has provided consulting services to Terumo, has provided expert witness testimony relating to heparin-induced thrombocytopenia and non-heparin-induced thrombocytopenia thrombocytopenic and coagulopathic disorders. All of these are outside the current work. The remaining authors declare no competing financial interests.

ORCID profiles: G.U., 0000-0002-8717-6230; U.Z., 0000-0001-8372-3615; A.M., 0000-0002-2399-3020; M.G., 0000-0002-4294-980X; G.C.P., 0000-0002-0145-8641; K.F., 0000-0002-4566-712X; H.H., 0000-0002-6534-036X; U.J.S., 0000-0001-5486-5542.

Correspondence: Tamam Bakchoul, Institute for Clinical and Experimental Transfusion Medicine, Medical Faculty of Tuebingen, Otfried-Müller

Str. 4/1, 72072 Tuebingen, Germany; e-mail: tamam.bakchoul@med.uni-tuebingen.de.

## Footnotes

Submitted 10 May 2021; accepted 30 May 2021; prepublished online on *Blood* First Edition 24 June 2021.

Data may be requested for academic collaboration from the corresponding author.

The online version of this article contains a data supplement.

There is a *Blood* Commentary on this article in this issue.

## REFERENCES

1. Voysey M, Clemens SAC, Madhi SA, et al; Oxford COVID Vaccine Trial Group. Safety and efficacy of the ChAdOx1 nCoV-19 vaccine (AZD1222) against SARS-CoV-2: an interim analysis of four randomised controlled trials in Brazil, South Africa, and the UK. *Lancet*. 2021;397(10269):99-111.
2. Greinacher A, Thiele T, Warkentin TE, Weisser K, Kyrle PA, Eichinger S. Thrombotic thrombocytopenia after ChAdOx1 nCov-19 vaccination. *N Engl J Med*. 2021;384(22):2092-2101.
3. Schultz NH, Sørvoll IH, Michelsen AE, et al. Thrombosis and thrombocytopenia after ChAdOx1 nCoV-19 vaccination. *N Engl J Med*. 2021;384(22):2124-2130.
4. Scully M, Singh D, Lown R, et al. Pathologic antibodies to platelet factor 4 after ChAdOx1 nCoV-19 vaccination. *N Engl J Med*. 2021;384(23):2202-2211.
5. Tiede A, Sachs UJ, Czwalińska A, et al. Prothrombotic immune thrombocytopenia after COVID-19 vaccination. *Blood*. 2021;138(4):350-353.
6. Wolf ME, Luz B, Niehaus L, Bhogal P, Bänzner H, Henkes H. Thrombocytopenia and intracranial venous sinus thrombosis after "COVID-19 Vaccine AstraZeneca" exposure. *J Clin Med*. 2021;10(8):1599.
7. Althaus K, Möller P, Uzun G, et al. Antibody-mediated procoagulant platelets in SARS-CoV-2 vaccination associated immune thrombotic thrombocytopenia. *Haematologica*. 2021;106(8):2170-2179.
8. Warkentin TE. High-dose intravenous immunoglobulin for the treatment and prevention of heparin-induced thrombocytopenia: a review. *Expert Rev Hematol*. 2019;12(8):685-698.
9. Bakchoul T, Borst O, Riessen R, et al. Autoimmune heparin-induced thrombocytopenia after transcatheter aortic valve implantation: successful treatment with adjunct high-dose intravenous immunoglobulin. *TH Open*. 2019;3(2):e200-e202.
10. Nazy I, Sachs UJ, Arnold DM, et al. Recommendations for the clinical and laboratory diagnosis of vaccine-induced immune thrombotic thrombocytopenia (VITT) for SARS-CoV-2 infections: communication from the ISTH SSC Subcommittee on Platelet Immunology. *J Thromb Haemost*. 2021;19(6):1585-1588.
11. Althaus K, Marini I, Zlamal J, et al. Antibody-induced procoagulant platelets in severe COVID-19 infection. *Blood*. 2021;137(8):1061-1071.
12. Park BD, Kumar M, Nagalla S, et al. Intravenous immunoglobulin as an adjunct therapy in persisting heparin-induced thrombocytopenia. *Transfus Apheresis Sci*. 2018;57(4):561-565.
13. Oldenburg J, Klamroth R, Langer F, et al. Diagnosis and management of vaccine-related thrombosis following AstraZeneca COVID-19 vaccination: guidance statement from the GTH. *Hamostaseologie*. 2021;41(3):184-189.
14. Expert Haematology Panel. Guidance produced by the Expert Haematology Panel (EHP) focussed on vaccine induced thrombosis and thrombocytopenia (VITT). <https://b-s-h.org.uk/about-us/news/guidance>

## TO THE EDITOR:

# Immune thrombocytopenic purpura after vaccination with COVID-19 vaccine (ChAdOx1 nCov-19)

Finn-Ole Paulsen,<sup>1,\*</sup> Christoph Schaefers,<sup>1,\*</sup> Florian Langer,<sup>1</sup> Christian Frenzel,<sup>1</sup> Ulrich Wenzel,<sup>2</sup> Felicitas E. Hengel,<sup>2</sup> Carsten Bokemeyer,<sup>1</sup> and Christoph Seidel<sup>1</sup>

<sup>1</sup>Division of Pneumology, Department of Oncology, Hematology, and Bone Marrow Transplantation, University Medical Center Hamburg-Eppendorf, Hamburg, Germany; and <sup>2</sup>Department of Medicine, University Hospital Hamburg-Eppendorf, Hamburg, Germany

Coronavirus disease 2019 (COVID-19) is an ongoing pandemic caused by the severe acute respiratory syndrome coronavirus 2 (SARS-CoV-2).<sup>1</sup> Newly developed vaccines are powerful tools for interrupting the ongoing dissemination of SARS-CoV-2. Because the first vaccines were approved for clinical use within a short period of time, the available data on adverse effects in relation to vaccination for SARS-CoV-2 are still limited.<sup>2</sup> One available vaccine is the adenovirus vector-based ChAdOx1 nCov-19 (also known as AZD122) from AstraZeneca.<sup>3,4</sup> As this vaccine is considered to be safe,<sup>2,4</sup> a new condition named vaccine-induced immune thrombotic thrombocytopenia (VITT) syndrome was reported in relation to previous administration of ChAdOx1 nCov-19<sup>5-7</sup> and Ad26.COVS.2.S (Janssen Pharmaceuticals).<sup>8</sup>

VITT is associated with thrombocytopenia accompanied by thrombosis and antibodies against platelet factor 4 (PF4) in the serum, but it differs from postvaccination immune thrombocytopenic purpura (ITP), a phenomenon associated with both live and inactivated vaccines.<sup>9-11</sup> To our knowledge, however, ITP has not yet been described as being associated with administration of ChAdOx1 nCov-19 vaccine. Here, we report our findings in a cohort of 4 patients who presented with severe thrombocytopenia in the absence of thrombosis a short time after receiving a ChAdOx1 nCov-19 adenoviral vector vaccine at our (single-center) institution.

We conducted retrospective and prospective analyses of patients who received treatment in our institution for ITP associated with ChAdOx1 nCov-19 vaccination within a 19-day period in May 2021. We evaluated patients' records and confirmed the diagnosis of ITP. Patients' demographic and clinical characteristics are presented in Table 1. Detailed case descriptions are provided in the supplemental information (available on the *Blood* Web site). Informed consent was provided by each patient, and monocentric data acquisition was in line with local requirements according to the Hamburg Hospital Act (HmbKHG) §12 and in accordance with the Declaration of Helsinki.

The patients were White women and men between 64 and 72 years of age from Germany. They presented 2 to 15 days after receiving the first dose of ChAdOx1 nCov-19 with severe symptomatic thrombocytopenia of  $\leq 6 \times 10^9/L$  cells. Patients 1 and 2

had a medical history of thyroid disorders (autoimmune thyroiditis and latent autoimmune hypothyroidism, respectively), patient 3 was previously diagnosed with minor thrombocytopenia ( $\sim 60 \times 10^9/L$ ), and patient 4 reported preexisting conditions, including chronic obstructive pulmonary disease and arterial hypertension. Initial symptoms included petechiae (patients 1, 3, and 4), hematomas (patient 1), headaches (patient 2), hyposphagma (patient 3), and epistaxis (patient 4). All patients reported that prior vaccinations against seasonal influenza (all patients), pneumococcus, and rubella (patients 2 and 3) were well tolerated. At admission, all patients were SARS-CoV-2 negative according to a polymerase chain reaction test. In addition, patient 2 had a serologic test that was positive for SARS-CoV-2 spike receptor-binding domain and SARS-CoV-2 spike trimer immunoglobulin G (IgG) or IgM antibodies and negative for SARS-CoV-2 nucleocapsid IgG or IgM antibodies (Elecsys Anti-SARS-CoV-2, electrochemiluminescence immunoassay [ECLIA], Roche), indicating active immune response after vaccination.

The patients did not present with signs or symptoms of thrombotic events, and no antibodies to PF4-polyanion complexes were detected in enzyme-linked immunosorbent assay (Asserachrom HPIA-IgG, Stago), so the patients discussed were not associated with VITT. In addition, a magnetic resonance imaging scan was conducted in patient 2 to rule out intracranial bleeding and cerebral vein or sinus thrombosis because she presented with headaches. A bone marrow biopsy from patient 2 revealed an increased megakaryocyte count with no signs of malignancy. No clinical signs or symptoms of infection were present in any of the patients. On the basis of presentation and after ruling out differential diagnoses, ITP was diagnosed in all 4 patients.<sup>12</sup>

The patients received corticosteroids (prednisolone 100 mg/day; initial bolus of 250 mg in patient 1) as initial treatment (Figure 1). No further treatment was initiated in patients 3 and 4 because of a quick recovery of the platelet counts that increased to  $23 \times 10^9/L$  and  $98 \times 10^9/L$  after 4 and 6 days, respectively. Patients 3 and 4 were discharged for outpatient follow-up with a steroid reduction plan. Intravenous immunoglobulin (IVIg) was administered to patients 1 (0.4 g/kg) and 2 (1 g/kg) (Figure 1). Patient 2 did not respond, so dexamethasone (40 mg) was initiated for 7 more days. Platelet counts increased in patients 1 ( $142 \times 10^9/L$ )