blood®
Letters to *Blood*

Check for updates

TO THE EDITOR:

Long-term follow-up of mTOR inhibition for Erdheim-Chester disease

Francesco Pegoraro,[1,*] Valerio Maniscalco,[1,*] Francesco Peyronel,[2] Pieter J. Westenend,[3] Tadek R. Hendriksz,[4] Rosa M. Roperto,[5] Alessandro A. Palumbo,[6] Elena Sieni,[7] Paola Romagnani,[5,8] Eric F. H. van Bommel,[9] and Augusto Vaglio[5,8]

[1]Department of Health Sciences, University of Firenze, Florence, Italy; [2]Nephrology Unit, University Hospital, Parma, Italy; [3]Department of Pathology and [4]Department of Radiology, Albert Schweitzer Hospital, Dutch National Center of expertise for retroperitoneal fibrosis, Dordrecht, The Netherlands; [5]Nephrology and Dialysis Unit, Meyer Children's Hospital, Florence, Italy; [6]Department of Radiology, University Hospital, Parma, Italy; [7]Department of Pediatric Hematology and Oncology, Meyer Children's Hospital, Florence, Italy; [8]Department of Biomedical, Experimental and Clinical Sciences "Mario Serio," University of Firenze, Florence, Italy; and [9]Department of Nephrology, Albert Schweitzer Hospital, Dutch National Center of Expertise for Retroperitoneal Fibrosis, Dordrecht, The Netherlands

Erdheim-Chester disease (ECD) is a non-Langerhans cell histiocytosis characterized by tissue infiltration by foamy $CD68^+$ $CD1a^-$ histiocytes.[1,2] ECD has a putative neoplastic and inflammatory nature. The neoplastic hypothesis is supported by the clonality of the infiltrating histiocytes, which harbor mitogen-activated protein kinase pathway mutations, of which *BRAF*^{V600E} is the most common.[3-5] Immune-mediated mechanisms contribute to histiocytic infiltration through a proinflammatory cytokine–chemokine network.[6,7] Different treatments targeting these pathogenic mechanisms are considered first-line approaches for ECD, namely interferon-α (IFN-α), BRAF^{V600E}, and MEK inhibitors. Their efficacy, however, is variable, depending on underlying mutations and organ involvement, and frequently limited by remarkable toxicity.[8-16]

The mammalian target of rapamycin (mTOR) regulates cell growth, proliferation and apoptosis, and modulates immune responses. mTOR inhibitors (mTORi's) (eg, sirolimus, everolimus) are used to treat several neoplastic and inflammatory conditions and prevent allograft rejection.[17,18] We demonstrated mTOR pathway activation in ECD lesions and provided preliminary evidence of the efficacy of a sirolimus- and prednisone-based regimen in a trial involving 10 patients.[19]

We report here the long-term outcomes of 20 consecutive patients with ECD treated with mTORi's; the study includes an extended follow-up of the 10 patients enrolled in our previous trial[19] and 3 patients reported in a case series,[20] plus 7 new cases. Eligibility criteria are detailed in supplemental Methods (available on the *Blood* Web site).

The main patient characteristics are described in supplemental Table 1. Eighteen patients had a biopsy-proven diagnosis; the remaining 2 (patients 18 and 20) were diagnosed based on typical imaging findings. *BRAF*^{V600E} mutation was found in 8 out of 16 tested patients. Retroperitoneal involvement was detected in 17 patients; 13 of them had hydronephrosis, requiring ureteral stenting or nephrostomy in 4 cases. Three patients had stage 4 chronic kidney disease according to the National Kidney Foundation classification. Large-vessel and bone involvement were detected respectively in 14 and 16 patients, whereas 6 showed central nervous system (CNS) involvement on magnetic resonance imaging (MRI). Cardiac disease was detected in 8 patients (13 were studied using cardiac MRI).[21,22] Interstitial lung disease was radiologically found in 6 patients. Other manifestations (endocrine, skin, and soft-tissue infiltration) were also observed (supplemental Table 1).

Fourteen patients received mTORi's as first-line therapy (supplemental Table 1). Sirolimus was prescribed to 15 patients at a single oral dose of 2 mg/day and subsequently titrated to reach blood levels of 8 to 12 ng/mL (in the 10 patients included in our previous trial,[19] prednisone was combined). The remaining 5 patients received everolimus monotherapy at a dose of 0.75 mg twice daily, titrated to reach blood levels of 8 to 12 ng/mL.

Response to treatment and survival are described in Figure 1. Response was assessed using clinical evaluation, computed tomography (CT), MRI, bone scintigraphy, and positron emission tomography (PET) CT. Radiologic and metabolic responses were defined according to RECIST and PERCIST criteria (supplemental Methods).[23,24] The first assessment of response was performed at months 4 to 6.

The median time on treatment was 21.5 months (interquartile range [IQR], 11.5-71.5); the median follow-up was 30 months (IQR, 12.5-78) in all patients and 54 months (IQR, 13-86) in those who were alive at last follow-up. The median time to best response was 6 months (Figure 1).

Complete response (CR; defined as metabolic or radiologic, ie, either complete disappearance of FDG-uptake on PET or complete lesion regression on CT/MRI) was achieved in 2 patients. Patient 7 had bone, cardiac, large-vessel, and retroperitoneal involvement and achieved metabolic CR at month 41. Patient 8, who had bone, large-vessel, and retroperitoneal involvement, achieved metabolic CR at month 30.

A sustained partial response (PR; defined as either partial improvement of lesions on PET and/or >30% regression at CT/MRI, whichever proved best) was achieved in 11 patients (Figure 2; supplemental Figure 1). Nine of them were still alive

Downloaded from http://ashpublications.net/blood/article-pdf/135/22/1994/1736017/bloodbld2019004478r1.pdf by guest on 11 June 2024

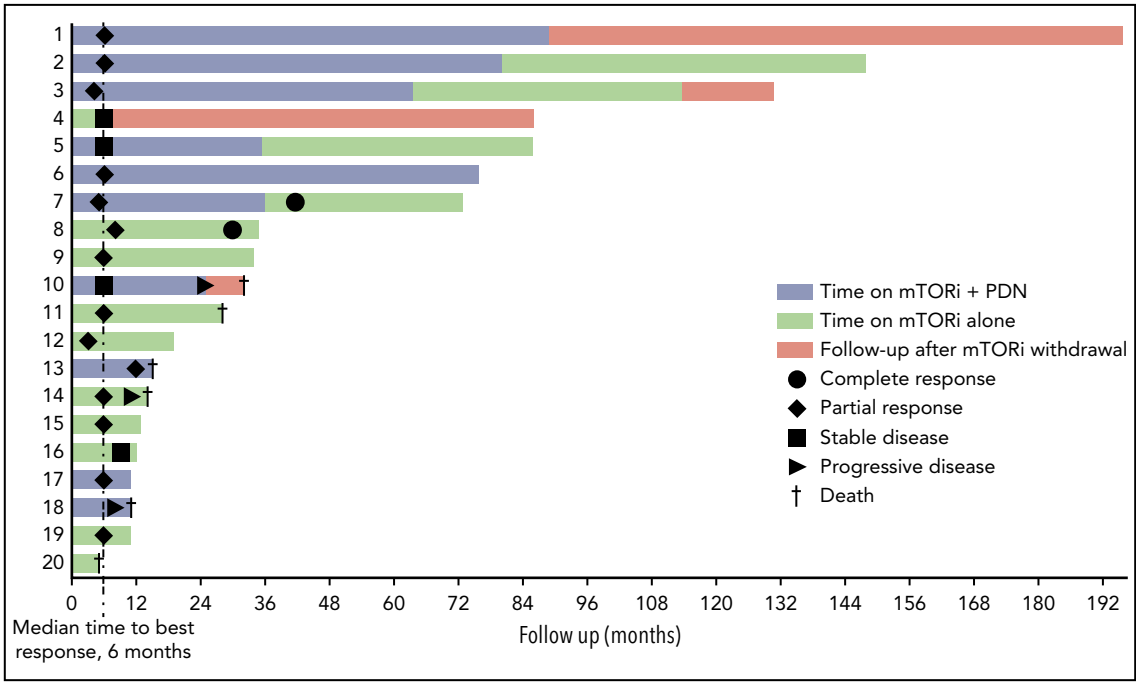

Figure 1. Swimmer plot of response to treatment and survival. Patients 18 and 20 had a nonbiopsy-proven diagnosis. PDN, prednisone.

at last follow-up, whereas 2 (patients 11 and 13) died due to non–ECD-related comorbidities (rhabdomyolysis and small-cell lung cancer). Stable disease was achieved and maintained until last follow-up in 3 patients.

Three patients progressed despite treatment. Patient 14 achieved PR (month 6) but died of progressive pulmonary ECD (month 14). Patient 18 had severe CNS involvement; he refused to take IFN-α, switched to methotrexate but resumed sirolimus 1 month later because of poor methotrexate tolerability, and died at month 11. Patient 10, after initial stabilization, had cardiac and retroperitoneal progression; she switched to vemurafenib (month 25) but died a few months later (month 32). Patient 20 was not assessable for response because he died of ischemic heart disease at month 5. Overall, the median progression-free survival was 26.5 months (IQR, 11.5-82.5) (supplemental Figure 2); progression-free survival rates at 12 and 24 months were 83% and 66%, respectively. The overall survival rate was 88% at 1 year and 54% at 3 and 5 years. The overall mortality was 30% (median follow-up, 30 months).

The best objective responses were observed at the retroperitoneal, cardiac, and large-vessel levels. Retroperitoneal lesions partially or completely regressed in 9 out of 17 patients (53%) and stabilized in 7 patients. Two of the 3 patients who underwent ureteral stenting became stent-free. Cardiac lesions partially regressed on MRI in 6 out of 8 patients (75%). Six patients remained free of pericardial effusion over the entire follow-up, whereas patient 10 progressed. Large-vessel lesions improved in 11 out of 14 patients (79%).

Bone disease remained stable or slightly improved on bone scintigraphy in all patients. CNS lesions partially regressed in 2 out of 6 patients (33%), stabilized in 3 patients, and progressed in 1 patient (#18). Lung involvement improved in 2 out of 6 patients and stabilized in 2 patients; patient 14 died of pulmonary involvement (supplemental Table 2).

Treatment was well tolerated in most cases. The most common adverse events were worsening of diabetes (15%) and dyslipidemia (10%) (supplemental Table 3). Two patients temporarily discontinued treatment due to drug-related toxicity (infectious panniculitis, lymphocytic alveolitis). One of them discontinued sirolimus and relapsed 2 years later with new-onset pleural lesions. Patient 4 discontinued treatment of acute kidney failure of uncertain origin; she later started IFN-α, maintaining disease stabilization.

In this study of 20 patients with ECD, we observed efficacy and good tolerability of mTORi's. Ten patients were included in our sirolimus plus prednisone study,[19] and their extended follow-up is reported herein. Prompted by the encouraging trial results, we treated 10 additional patients with mTORi's; in these cases, glucocorticoids were avoided, because accumulating evidence had questioned their therapeutic role in ECD.[8] The high response rate observed after mTORi monotherapy further supports the view that they are efficacious per se.

Overall, mTORi's induced CT/MRI or metabolic responses in 13 out of 20 patients (65%) and stable disease in 3 patients (15%). Most responses were sustained, and most patients were still on treatment at last visit. The overall mortality was higher than in other series, although our patients suffered from severe comorbidities, and half the deaths were ECD unrelated. Drug-related side effects were limited.

The therapeutic approach to ECD is quite complex. IFN-α is the traditional first-line therapy, but $BRAF^{V600E}$ and MEK inhibitors are candidate first-line options, especially for severe cases.[8-16,25] However, their use is limited by side effects and

Downloaded from http://ashpublications.net/blood/article-pdf/135/22/1994/1736017/bloodbld2019004478r1.pdf by guest on 11 June 2024

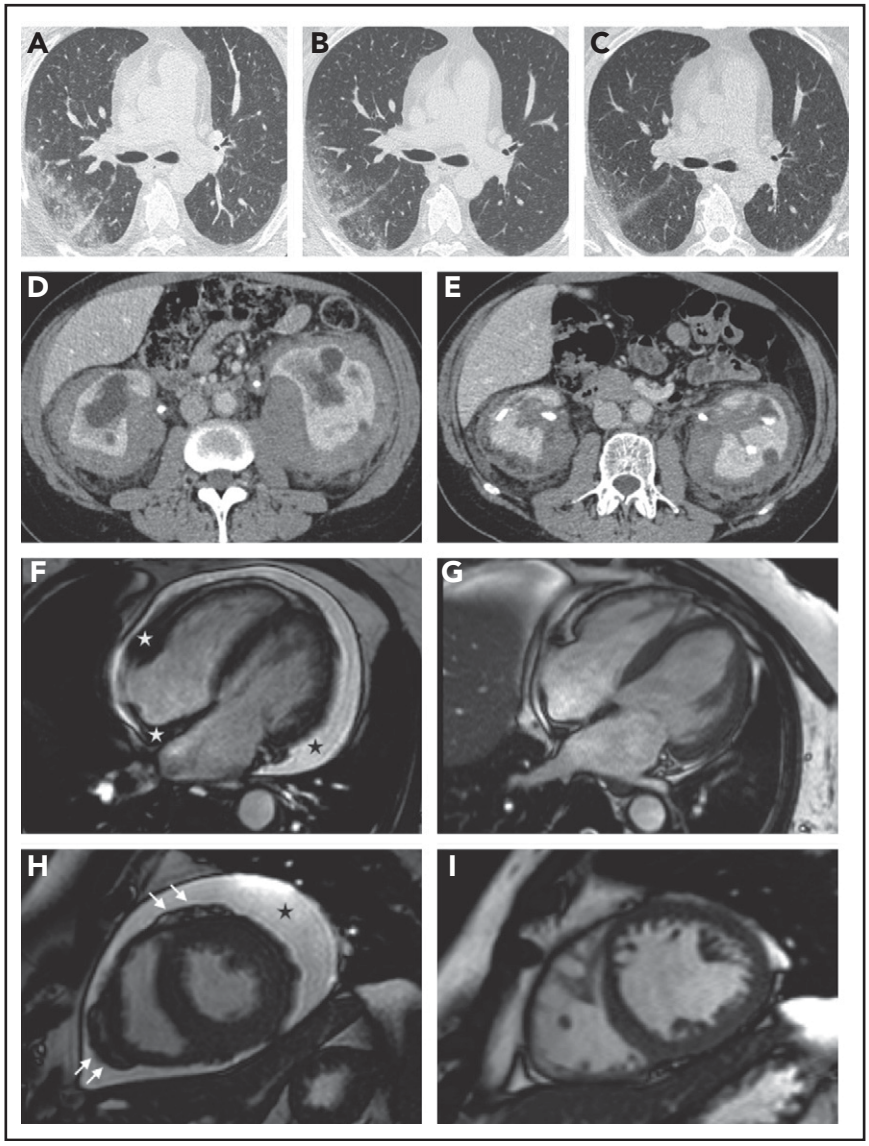

Figure 2. Organ responses. (A-C) Chest high-resolution CT scans in patient 12 show progressive regression of ECD-related lung disease (the scans were taken respectively before treatment and at months 6 and 12 after the beginning of therapy with everolimus) (axial view). (D-E) Contrast-enhanced abdominal CT scans in patient 8 show marked regression of perirenal infiltration with consequent improvement of hydronephrosis and calycectasia (axial view). (F-I) Cardiac magnetic resonance (cine frame from steady-state free precession sequence) in a patient (#19) with cardiac involvement; the scans were taken at baseline (F,H) and after 1 year of treatment (G,I). (F) Circumferential pericardial effusion (black star) and pathologic soft tissue in the right atrioventricular groove and the right side of the interatrial septum (white stars). Arrows (H) indicate nodular thickening of the visceral pericardium. Pericardial effusion and infiltrative lesions almost completely disappeared (G,I; scans after treatment).

high costs. ECD patients that can benefit from mTORi's might include those with nonsevere disease or those who have no access or contraindications to targeted therapies or IFN-α. Since mTORi's induced responses in both *BRAF*^{V600E} and wild-type patients, they could be used irrespective of the *BRAF* status.

In summary, mTORi's, even if used as monotherapy, represent a valid alternative to conventional ECD treatments, as they induce high response rates and are generally well tolerated.

Authorship

Contribution: F. Pegoraro and A.V. designed the study, analyzed the data, and wrote the manuscript; V.M., F. Peyronel, P.J.W., R.M.R., P.R., and E.F.H.v.B. followed the patients and collected the data; E.S. performed tumor sequencing; A.A.P. and T.R.H. reviewed the imaging studies and generated the imaging figures; and all authors reviewed the final version of the manuscript.

Conflict-of-interest disclosure: The authors declare no competing financial interests.

ORCID profiles: F. Pegoraro, 0000-0002-4954-5744; F. Peyronel, 0000-0001-8470-1952; P.J.W., 0000-0002-5509-920X; E.S., 0000-0002-6192-9812; P.R., 0000-0002-1774-8088.

Correspondence: Augusto Vaglio, Dipartimento di Scienze Biomediche, Sperimentali e Cliniche "Mario Serio", Università di Firenze, Viale Pieraccini 6, 50139 Firenze, Italy; e-mail: augusto.vaglio@unifi.it.

Footnotes

*F. Pegoraro and V.M. contributed equally to this study.

The online version of this article contains a data supplement.

REFERENCES

1. Emile JF, Abla O, Fraitag S, et al; Histiocyte Society. Revised classification of histiocytoses and neoplasms of the macrophage-dendritic cell lineages. *Blood*. 2016;127(22):2672-2681.

2. Haroche J, Cohen-Aubart F, Rollins BJ, et al. Histiocytoses: emerging neoplasia behind inflammation. *Lancet Oncol*. 2017;18(2):e113-e125.

3. Hervier B, Haroche J, Arnaud L, et al; French Histiocytoses Study Group. Association of both Langerhans cell histiocytosis and Erdheim-Chester

Downloaded from http://ashpublications.net/blood/article-pdf/135/22/1994/1736017/bloodbld2019004478r1.pdf by guest on 11 June 2024

disease linked to the BRAFV600E mutation. *Blood*. 2014;124(7):1119-1126.

4. Milne P, Bigley V, Bacon CM, et al. Hematopoietic origin of Langerhans cell histiocytosis and Erdheim-Chester disease in adults. *Blood*. 2017;130(2):167-175.

5. Durham BH, Roos-Weil D, Baillou C, et al. Functional evidence for derivation of systemic histiocytic neoplasms from hematopoietic stem/progenitor cells. *Blood*. 2017;130(2):176-180.

6. Stoppacciaro A, Ferrarini M, Salmaggi C, et al. Immunohistochemical evidence of a cytokine and chemokine network in three patients with Erdheim-Chester disease: implications for pathogenesis. *Arthritis Rheum*. 2006;54(12):4018-4022.

7. Arnaud L, Gorochov G, Charlotte F, et al. Systemic perturbation of cytokine and chemokine networks in Erdheim-Chester disease: a single-center series of 37 patients. *Blood*. 2011;117(10):2783-2790.

8. Diamond EL, Dagna L, Hyman DM, et al. Consensus guidelines for the diagnosis and clinical management of Erdheim-Chester disease. *Blood*. 2014;124(4):483-492.

9. Vaglio A, Diamond EL. Erdheim-Chester disease: the "targeted" revolution. *Blood*. 2017;130(11):1282-1284.

10. Arnaud L, Hervier B, Néel A, et al. CNS involvement and treatment with interferon-α are independent prognostic factors in Erdheim-Chester disease: a multicenter survival analysis of 53 patients. *Blood*. 2011;117(10):2778-2782.

11. Cohen Aubart F, Emile JF, Carrat F, et al. Targeted therapies in 54 patients with Erdheim-Chester disease, including follow-up after interruption (the LOVE study). *Blood*. 2017;130(11):1377-1380.

12. Haroche J, Cohen-Aubart F, Emile JF, et al. Dramatic efficacy of vemurafenib in both multisystemic and refractory Erdheim-Chester disease and Langerhans cell histiocytosis harboring the BRAF V600E mutation. *Blood*. 2013;121(9):1495-1500.

13. Diamond EL, Subbiah V, Lockhart AC, et al. Vemurafenib for BRAF V600–mutant Erdheim-Chester disease and Langerhans cell histiocytosis: analysis of data from the histology-independent, phase 2, open-label VE-BASKET study. *JAMA Oncol*. 2018;4(3):384-388.

14. Diamond EL, Durham BH, Ulaner GA, et al. Efficacy of MEK inhibition in patients with histiocytic neoplasms. *Nature*. 2019;567(7749):521-524.

15. Cohen-Aubart F, Maksud P, Saadoun D, et al. Variability in the efficacy of the IL1 receptor antagonist anakinra for treating Erdheim-Chester disease. *Blood*. 2016;127(11):1509-1512.

16. Papo M, Diamond EL, Cohen-Aubart F, et al. High prevalence of myeloid neoplasms in adults with non-Langerhans cell histiocytosis. *Blood*. 2017;130(8):1007-1013.

17. Amato R, Stepankiw M. Evaluation of everolimus in renal cell cancer. *Expert Opin Pharmacother*. 2013;14(9):1229-1240.

18. Ponticelli C. The pros and the cons of mTOR inhibitors in kidney transplantation. *Expert Rev Clin Immunol*. 2014;10(2):295-305.

19. Gianfreda D, Nicastro M, Galetti M, et al. Sirolimus plus prednisone for Erdheim-Chester disease: an open-label trial. *Blood*. 2015;126(10):1163-1171.

20. van Bommel EFH, van der Zijden MA, Smak Gregoor PJH, Hendriksz TR, Ho-Han SH, Westenend PJ. Sirolimus monotherapy for Erdheim-Chester disease. *Acta Oncol*. 2019;58(6):901-905.

21. Gianfreda D, Palumbo AA, Rossi E, et al. Cardiac involvement in Erdheim-Chester disease: an MRI study. *Blood*. 2016;128(20):2468-2471.

22. Vaglio A, Corradi D, Maestri R, Callegari S, Buzio C, Salvarani C. Pericarditis heralding Erdheim-Chester disease. *Circulation*. 2008;118(14):e511-e512.

23. Eisenhauer EA, Therasse P, Bogaerts J, et al. New response evaluation criteria in solid tumours: revised RECIST guideline (version 1.1). *Eur J Cancer*. 2009;45(2):228-247.

24. Wahl RL, Jacene H, Kasamon Y, Lodge MA. From RECIST to PERCIST: Evolving Considerations for PET response criteria in solid tumors. *J Nucl Med*. 2009;50(Suppl 1):122S-150S.

25. Hunt D, Milne P, Fernandes P, Bigley V, Collin M. Targeted treatment of brainstem neurohistiocytosis guided by urinary cell-free DNA. *Neurol Neuroimmunol Neuroinflamm*. 2016;4(1):e299.

DOI 10.1182/blood.2019004478

© 2020 by The American Society of Hematology

TO THE EDITOR:

Initiating adjunct low-dose hydroxyurea therapy for stroke prevention in children with SCA during the COVID-19 pandemic

Michael R. DeBaun

Vanderbilt-Meharry Center of Excellence in Sickle Cell Disease, Vanderbilt University Medical Center, Nashville, TN

The COVID-19 pandemic may soon result in an unprecedented decrease in blood supply in the United States. Not only will there be a decrease in blood donors, but there will likely be a decrease in the number of health care personnel able to collect, process, and deliver the blood donations. Conceivably, clinicians will be compelled to ration the limited resources required for blood transfusion to those at immediate risk for clinical deterioration.

Children with sickle cell anemia (SCA) and a history of strokes will be at greatest risk for recurrent stroke without regular blood transfusion therapy. For children with SCA and prior strokes, regular blood transfusion has been standard therapy for stroke prevention for >30 years. The absence of any treatment for secondary stroke prevention can be catastrophic. In a pooled analysis of 2 studies conducted in low-resource settings, children with SCA and strokes who did not receive regular blood transfusion had an overt stroke recurrence rate of 29 per 100 person years, with ≥50% of children having acute stroke recurrence in 2 years[1] (Figure 1). For some time, pediatricians in Africa have been challenged with obtaining adequate, safe, and routine blood supply for secondary prevention of strokes and are electing to use hydroxyurea as an alternative. In 2013, Legunju and colleagues in Nigeria were among the first pediatricians to report the benefit of hydroxyurea therapy as an alternative to regular blood transfusion therapy for secondary stroke prevention in children with SCA.[2] In a pooled analysis that includes 2 studies conducted in low-income settings, hydroxyurea

Downloaded from http://ashpublications.net/blood/article-pdf/135/22/1994/1736017/bloodbld2019004478r1.pdf by guest on 11 June 2024