blood®
Regular Article



LYMPHOID NEOPLASIA

# Randall-type monoclonal immunoglobulin deposition disease: novel insights from a nationwide cohort study

Florent Joly,[1,2,*] Camille Cohen,[3,4,*] Vincent Javaugue,[1,2,5] Sébastien Bender,[2,6] Mohamed Belmouaz,[1,2] Bertrand Arnulf,[7] Bertrand Knebelmann,[3,4] Mathilde Nouvier,[8] Vincent Audard,[9,10] François Provot,[11] Viviane Gnemmi,[12] Dominique Nochy,[13] Jean Michel Goujon,[2,14] Arnaud Jaccard,[2,15] Guy Touchard,[1,2] Jean Paul Fermand,[7] Christophe Sirac,[2,6] and Frank Bridoux[1,2,5,6]

[1]Department of Nephrology, CHU Poitiers, Poitiers, France; [2]Centre National de Référence Maladies Rares: Amylose AL et Autres Maladies à Dépôts d'Immunoglobulines Monoclonales, Poitiers, France; [3]Department of Nephrology and [4]INSERM U1151 Mechanisms and Therapeutic Strategies of Chronic Kidney Diseases, Necker Hospital, Paris, France; [5]INSERM CIC 1402, Poitiers, France; [6]CNRS UMR 7276-CRIBL, University of Limoges, Limoges, France; [7]Department of Immunology and Hematology, Saint Louis Hospital, Paris, France; [8]Department of Nephrology, Lyon Sud Hospital, Lyon, France; [9]Department of Nephrology, Assistance Publique des Hôpitaux de Paris, Groupe Hospitalier Henri-Mondor/Albert Chenevier, Créteil, France; [10]Equipe 21, INSERM U955, Institut Mondor de Recherche Biomédicale, Créteil, France; [11]Department of Nephrology, Centre Hospitalier Régional Universitaire de Lille, Lille, France; [12]Department of Pathology, Centre Hospitalier Régional Universitaire de Lille, Lille, France; [13]Department of Pathology, Hôpital Européen Georges-Pompidou, Paris, France; [14]Department of Pathology, CHU Poitiers, Poitiers, France; and [15]Department of Hematology, CHU Limoges, Limoges, France

KEY POINTS

- **LCDD often features with symptomatic extrarenal involvement. LC cationic hypervariable regions possibly account for tissue deposition.**
- **Deep serum FLC response, achieved early in the disease course, predicts favorable renal and patient outcomes.**

**Monoclonal immunoglobulin deposition disease (MIDD) is a rare complication of B-cell clonal disorders, defined by Congo red negative–deposits of monoclonal light chain (LCDD), heavy chain (HCDD), or both (LHCDD). MIDD is a systemic disorder with prominent renal involvement, but little attention has been paid to the description of extrarenal manifestations. Moreover, mechanisms of pathogenic immunoglobulin deposition and factors associated with renal and patient survival are ill defined. We retrospectively studied a nationwide cohort of 255 patients, with biopsy-proven LCDD (n = 212) (including pure LCDD [n = 154], LCDD with cast nephropathy (CN) [n = 58]), HCDD (n = 23), or LHCDD (n = 20). Hematological diagnosis was monoclonal gammopathy of renal significance in 64% and symptomatic myeloma in 34%. Renal presentation was acute kidney injury in patients with LCCD and CN, and chronic glomerular disease in the other types, 35% of whom had symptomatic extrarenal (mostly hepatic and cardiac) involvement. Sequencing of 18 pathogenic LC showed high isoelectric point values of variable domain complementarity determining regions, possibly accounting for tissue deposition. Among 169 patients who received chemotherapy (bortezomib-based in 58%), 67% achieved serum free light chain (FLC) response, including very good partial response (VGPR) or above in 52%. Renal response occurred in 62 patients (36%), all of whom had achieved hematological response. FLC response ≥ VGPR and absence of severe interstitial fibrosis were independent predictors of renal response. This study highlights an unexpected frequency of extrarenal manifestations in MIDD. Rapid diagnosis and achievement of deep FLC response are key factors of prognosis. (*Blood*. 2019;133(6):576-587)**

## Introduction

Randall-type monoclonal immunoglobulin deposition disease (MIDD) is a rare complication of clonal B-cell disorders, defined by Congo red–negative nonorganized deposits of monoclonal immunoglobulins, usually light chains (LCDD), and less commonly, heavy chains (HCDD) or both (LHCDD), along the basement membranes of various organs.[1,2] MIDD is a systemic disorder with almost constant renal involvement. The cornerstone of diagnosis is an immunofluorescence (IF) study of the kidney biopsy, showing linear deposits of the involved monoclonal immunoglobulin predominantly along tubular basement membranes (TBM), and usually in the mesangium, along glomerular basement membranes (GBM), or around arteriolar myocytes. Ultrastructurally, deposits display a characteristic powdery punctate appearance. As in light chain amyloidosis (AL amyloidosis), virtually all organs can be involved in MIDD, with potential life-threatening complications. However, little is known on the prevalence and prognostic importance of systemic nonrenal manifestations in MIDD.[3-6]

MIDD most commonly occurs in the context of a plasma cell disorder meeting criteria for multiple myeloma (MM) in nearly 50% of cases and for monoclonal gammopathy of renal significance (MGRS) in the remaining patients.[3,7-9] The concept of MGRS was recently introduced to individualize small B-cell clones lacking criteria for symptomatic disease, but secreting

a pathogenic monoclonal immunoglobulin directly or indirectly responsible for renal disease.[10,11] Renal lesions in MGRS do not depend on the clonal burden, but on physicochemical peculiarities of the monoclonal immunoglobulin.[10] Previous studies suggested an overrepresentation of the Vk4 LC variability subgroup in LCDD,[12] but mechanisms governing immunoglobulin tissue deposition remain unknown.

Treatment strategy in MIDD relies on chemotherapy targeting the underlying clone. Before the era of novel antimyeloma agents, median overall and renal survival was 2 and 4 years, respectively.[3,7] Although recent studies highlighted significant advances with regimens containing bortezomib,[8,13,14] thalidomide, or lenalidomide,[15-17] current management of MIDD is based on small cohorts and expert opinion. Guidelines for renal and hematological responses are lacking,[11] and factors associated with long-term outcomes remain to be defined. We herein report the largest cohort of MIDD to date, aiming to better define clinical, immunopathological, molecular characteristics, and outcomes in this rare disease.

# Methods

Cases were extracted from the database from the French National Reference Center for MGRS. Inclusion criteria were biopsy-proven MIDD, as defined by international criteria,[1] (i) diffuse linear monoclonal immunoglobulin deposits along TBM, GBM, and/or around arteriolar myocytes by IF; (ii) that stained positive for κ or λ LC only (LCDD), heavy chain (HC) only (HCDD), or for both LC and HC (LHCDD); (iii) with punctate powdery electron-dense deposits on TBM or GBM by electron microscopy (EM) when available. The diagnosis of MIDD in other organs required diffuse linear monoclonal immunoglobulin deposits along vascular basement membranes by IF. In the remaining patients, it was assumed in the absence of other identified cause, or because of improvement after chemotherapy. Because cardiomyopathy in MIDD and AL amyloidosis shares similarities,[6] the diagnosis of heart involvement relied on International Society of Amyloidosis (ISA) criteria[18] based on both cardiac biomarkers and echocardiography. Cardiac MIDD was excluded in patients with a past history of hypertension. Diagnosis of peripheral neuropathy was confirmed in all cases by electromyographic studies. Demographics and clinical and biological data were recorded at diagnosis, after completion of treatment and at last follow-up. The diagnosis of MGRS, MM, and Waldenström macroglobulinemia was established according to international criteria.[18-20] In patients with myeloma, hematological response was assessed according to the International Myeloma Working Group.[20] In patients with MIDD-associated MGRS, the ISA criteria[18] based on the difference between the involved and noninvolved LC (dFLC) were used: complete response (CR) was defined by normalization of serum free light chain (FLC) ratio with negative serum or urine immunofixation, very good partial response (VGPR) by the difference between the involved and noninvolved LC (dFLC) <40 mg/L, or ≥90% decrease in dFLC. When serum FLC results were not available, hematological response was based on the monoclonal spike by electrophoresis.[20] In patients with baseline proteinuria ≥0.5 g/d, renal response was defined according to the ISA.[18] Patients with proteinuria <0.5 g/d who achieved 25% improvement in baseline estimated glomerular filtration rate (eGFR) value were considered renal responders.[8,21] In LCDD patients with cast nephropathy (CN) and acute kidney injury (AKI), International Myeloma Working Group criteria for renal response were used.[22]

This study was performed in accordance with the Declaration of Helsinki and received approval by local ethics committees.

## Pathological studies

All kidney biopsy samples were processed for light and IF microscopy, as previously described.[8,23] All pathology reports were analyzed by 2 expert pathologists, and biopsy samples were centrally reviewed when required to confirm the diagnosis of MIDD. In addition, EM studies were centrally performed in 56 patients. Lung, heart, and liver biopsy samples were processed according to local procedures.

## Hematologic and immunologic studies

Bone marrow smears and/or biopsy were performed in all patients. Serum and urine samples were systematically studied by conventional electrophoresis and immunofixation. Immunoblot analysis was performed as previously described.[24] Serum FLC levels were serially monitored in 139 patients (Binding Site, Birmingham, United Kingdom).

## Molecular biology

Bone marrow RNA was collected in 28 patients (LCDD, n = 15; LHCDD, n = 3, HCDD, n = 10), as previously described.[23,25] HC sequences from HCDD patients have been previously published.[23] After reverse transcription (Biosystems) and polymerase chain reaction, complementary DNA sequencing was performed (Biosystems 3130XL). Sequences were analyzed using FinchTV software (PerkinElmer); V domain subgroups and mutations as compared with germline sequences were determined using the IMGT/V-Quest online software.[26] Sequence alignments were performed using the Multalin Web site (http://multalin.toulouse.inra.fr/multalin/). Predicted isoelectric point (pI) of V domains and combined complementarity-determining regions (CDRs) from LC were estimated using the pI calculator.[27]

## Statistical analysis

Data are expressed as medians with interquartiles (IQ25-75) for continuous variables and frequencies with percentages for qualitative variables. Fisher's exact test and Mann-Whitney *U* test were used for the comparison of qualitative and continuous variables, respectively. Survival analysis was performed by the Kaplan-Meier method and compared across groups using the log-rank test. A multivariate Cox model was used to assess factors associated with renal response, renal survival, and overall survival (OS). Statistical significance was assumed at $P < .05$. Analyses were carried out using GraphPad Prism version 5.1 (GraphPad Software, San Diego, CA).

# Results

## Baseline renal and hematological data

Two hundred fifty-five patients (median age 63.7 years, men 52%), diagnosed with LCDD (n = 212), HCDD (n = 23), or LHCDD (n = 20) between 1981 and 2015 in 55 centers in France, were included (Table 1; Figure 1). The diagnosis was established on allograft biopsy in 9 patients. Among 212 LCDD patients, 58 patients had concomitant myeloma CN: all had AKI and 52 required hemodialysis at diagnosis. Patients with pure LCDD

## Table 1. Baseline clinical data

| | All (n = 255) | Pure LCDD (n = 154) | LCDD+CN (n = 58) | HCDD (n = 23) | LHCDD (n = 20) |
|---|---|---|---|---|---|
| Age, y | 64 (53-75) | 63 (55-73) | 67 (57-75) | 59 (55-73) | 57 (49-72) |
| Men/women | 133/122 | 80/74 | 29/29 | 12/11 | 12/8 |
| **Hematological data** | | | | | |
| MGRS, n (%) | 163 (64) | 126 (82) | 0* | 22 (96) | 19 (95) |
| Symptomatic MM, n (%) | 86 (34) | 28 (18.2) | 58 (100%)* | 1 (4)† | 1 (5)† |
| WM, n (%) | 3 (1) | 3 (2) | 0 | 0 | 0 |
| CLL, n (%) | 1 (0.4) | 1 (0.6) | 0 | 0 | 0 |
| B-cell lymphoma, n (%) | 2 (0.8) | 2 (1.3) | 0 | 0 | 0 |
| dFLC | 431 (74-2318) | 1478 (246-4271) | 5405 (2567-15 012)* | 140 (69-458) | 602 (123-1177) |
| κ FLC excess, n (%) | 113/139 (81.3) | 69/84 (82.1) | 22/27 (81.5) | 11/16 (68.8) | 11/12 (91.7) |
| λ FLC excess, n (%) | 26/139 (18.7) | 15/84 (17.9) | 5/27 (18.5) | 5/16 (31.2) | 1/12 (8.3) |
| **Renal manifestations** | | | | | |
| Serum creatinine, μmol/L§ | 269 (169-471) | 247 (169-441) | 494 (300-804)* | 144 (133-167) | 228 (144-400) |
| eGFR (mL/min/1.73 $m^2$) | 24.3 (11.9-42.9) | 21 (11-32) | N/A | 37 (32-40)† | 27 (15-41) |
| CKD ≥4, n (%) | 115 (45) | 99 (64.2) | 0 (0) | 6 (26) | 10 (50) |
| AKI, n (%) | 58 (23) | 0 | 58 (100)* | 0 | 0 |
| Hemodialysis at diagnosis, n (%) | 60 (23) | 3 (3) | 52 (90)* | 1 (4) | 2 (10) |
| 24-h proteinuria, g§ | 1.8 (0.8-4) | 2.4 (1.2-4.5) | 2 (1.2-4.0) | 3.6 (2-5)‡ | 2.9 (1.3-5.2) |
| Serum albumin, g/L§ | 33 (29-40) | 33 (29-40) | 35 (30-40) | 26 (24-30)‡ | 30 (29-37) |
| Nephrotic syndrome, n (%) | 56 (22) | 35 (29) | 0 (0)* | 14 (61)‡ | 7 (35) |
| Hematuria, n (%) | 147 (58) | 70 (59) | 29 (50) | 19 (83)‡ | 15 (75) |
| Hypertension, n (%) | 140 (55) | 61 (51) | 35 (60) | 17 (74)‡ | 11 (55) |
| **Extrarenal manifestations** | | | | | |
| ≥1 site/organ involved, n (%) | 89 (35) | 75 (48.7)‖ | 6 (10.3) | 6 (26.1) | 2 (10) |
| Liver, n (%) | 43 (17) | 34 (22)‖ | 4 (7) | 3 (13) | 2 (10) |
| Heart, n (%) | 31 (12) | 27 (18)‖ | 1 (2) | 2 (9) | 1 (5) |
| Peripheral nerve, n (%) | 24 (9) | 20 (13) | 4 (7) | 0 | 0 |
| Minor salivary gland, n (%) | 17 (7) | 14 (9) | 1 (2) | 2 (9) | 0 |
| Gastrointestinal tract, n (%) | 11 (4) | 9 (6) | 0 | 2 (9) | 0 |
| Skin, n (%) | 9 (4) | 8 (5) | 0 | 0 | 1 (5) |
| Cutis laxa. n (%) | 3 (1) | 0 | 0 | 3 (13) | 0 |

CKD, chronic kidney disease; CLL, chronic lymphocytic leukemia; WM, Waldenström macroglobulinemia.

*$P < .05$, comparison between LCDD+CN and pure LCDD, HCDD, and LHCDD.

†$P < .05$, comparison between HCDD and pure LCDD.

‡$P < .05$, comparison between LHCDD and pure LCDD.

§Results are expressed as median (IQR).

‖$P < .05$, comparison between LCDD and LCDD+CN, HCDD and LHCDD.

**Table 1. (continued)**

| | All (n = 255) | Pure LCDD (n = 154) | LCDD+CN (n = 58) | HCDD (n = 23) | LHCDD (n = 20) |
|---|---|---|---|---|---|
| **Other** | 6 (2) | 6 (4) | 0 | 0 | 0 |
| Lung, n (%) | 6 (2) | 6 (4) | 0 | 0 | 0 |
| Bone marrow, n (%) | 2 (1) | 2 (1) | 0 | 0 | 0 |
| Abdominal fat, n (%) | 2 (1) | 2 (1) | 0 | 0 | 0 |
| Lymph node, n (%) | 2 (1) | 2 (1) | 0 | 0 | 0 |
| Thyroid, n (%) | 1 (0.4) | 0 | 0 | 1 (4) | 0 |
| Vocal cords, n (%) | 1 (0.4) | 1 (1) | 0 | 0 | 0 |

CKD, chronic kidney disease; CLL, chronic lymphocytic leukemia; WM, Waldenström macroglobulinemia.

*$P < .05$, comparison between LCDD+CN and pure LCDD, HCDD, and LHCDD.

†$P < .05$, comparison between HCDD and pure LCDD.

‡$P < .05$, comparison between LHCDD and pure LCDD.

§Results are expressed as median (IQR).

‖$P < .05$, comparison between LCDD and LCDD+CN, HCDD and LHCDD.

presented with chronic glomerular disease with median eGFR of 21 mL/min/1.73 $m^2$ (11-32) and proteinuria of 2.4 g (1.2-4.5). Thirty-five patients had proteinuria <0.5 g/d. Bone marrow plasmacytosis and dFLC level were higher in patients with LCDD and CN (LCDD-CN) than in those with pure LCDD. Renal presentation of LHCDD patients was close to that of pure LCCD patients. Compared with pure LCDD patients, HCDD patients had more frequent hypertension, higher baseline eGFR, lower albuminemia, and higher prevalence of nephrotic syndrome ($P < .001$; Table 1).

Monoclonal gammopathy (immunoglobulin G [IgG], n = 101, 44%; IgA, n = 35, 15%; IgM, n = 16, 7%; IgD, n = 3, 1%; or LC only, n = 74, 32%) was detected in the serum and/or urine from 229 patients (90%). LC isotype was κ in 181 cases (79%). All 139 patients tested for serum FLC (including all HCDD and LHCDD cases) showed abnormal κ/λ ratio, with median dFLC of 431 mg/L (74-2318). Serum immunoblot studies, performed in 15 HCDD patients, revealed a truncated heavy chain ($C_H1$ deletion) in 9 cases (60%). Median plasma cell infiltration was 14% (5-32) and >10% in 137 patients. Hematological diagnosis was MGRS (n = 163, 64%), symptomatic myeloma (n = 86, 34%), Waldenström macroglobulinemia (n = 3), and chronic lymphocytic leukemia (n = 3). Out of 45 patients with available data, 7 (15.6%) had high-risk cytogenetic abnormalities (del17p, n = 3; t(4;14), n = 4, both, n = 1).

## Extrarenal involvement

Eighty-nine patients (35%) had extrarenal manifestations (Table 1; supplemental Table 1, available on the *Blood* Web site), with histologically proven linear monoclonal immunoglobulin deposits matching the circulating monoclonal immunoglobulin in 31 cases. Liver involvement with hepatomegaly and cholestasis (n = 43, 17%) was the most common. Fifteen patients had raised liver enzymes. Bilirubin levels were normal, except in 1 γHCDD patient who presented with fulminant hepatitis.

Thirty-one LCDD patients had heart involvement (12.2%), with raised NT-proBNP and/or troponin T levels, and >12 mm diastolic interventricular septum thickness with diastolic dysfunction by echocardiography, in the absence of severe hypertension. Other involved organs/tissues were peripheral nerve (9.4%), minor salivary gland (6.6%), gastrointestinal tract (4.3%), lung (2.4%), and skin (2.4%).

The prevalence of nonrenal manifestations was higher in pure LCDD (48.7%) compared with other MIDD types (13.9%) ($P < .01$; Table 1).

## Pathological data

Diagnosis was assessed after pathological examination of native kidney (n = 239), transplanted kidney (n = 9), lung (n = 3), liver (n = 2), or heart (n = 2) biopsy (Table 2). Detailed renal pathology results were available in 220 patients. Light microscopy studies showed TBM thickening and nodular glomerulosclerosis in 180 (82%) and 131 (60%) patients, respectively. Nodular glomerulosclerosis was present in all HCDD cases, in 78% of LHCDD or pure LCDD cases, and in none of LCDD-CN cases. Arteriosclerosis was observed in 135 patients (61%) with severe interstitial fibrosis/tubular atrophy in 68 patients (34%). Typical myeloma casts were found in LCDD patients only.

By IF, diffuse linear immunoglobulin deposits were observed along TBM in all cases, with deposits along GBM and mesangium in 183 patients (83.0%). LCDD cases showed an overrepresentation

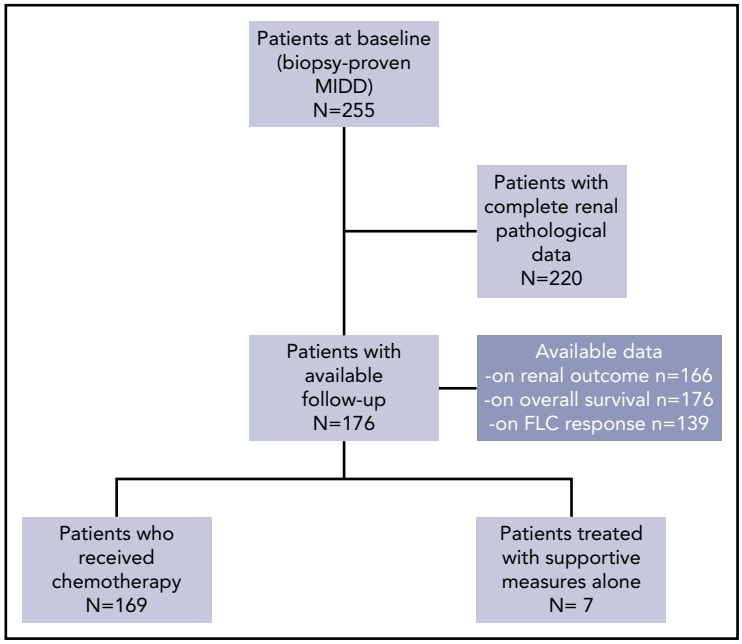


**Figure 1. Study flowchart.**

of monoclonal κ LC deposits (n = 143, 79.4%), whereas HCDD and LHCDD patients displayed mostly γ HC deposits (81.8 and 94.4%, respectively), with an overrepresentation of the γ1 HC subclass. EM studies showed electron dense powdery punctate deposits along the outer aspect of TBM (n = 39) and/or the inner aspect of GBM (n = 34) and/or in the mesangium (n = 25) (Figure 2). Four LCDD patients had associated glomerular AL amyloid deposits with similar LC isotype restriction. In 13 patients with liver involvement (LCDD, n = 11; HCDD, n = 2), linear monotypic deposits were seen in Disse spaces and in biliary duct basement membranes. Endomyocardial (n = 5), lung (n = 5), and peripheral nerve biopsies (n = 4) showed linear

## Table 2. Renal pathological data

| | All (n = 220) | LCDD (n = 180) | HCDD (n = 22) | LHCDD (n = 18) |
|---|---|---|---|---|
| **Light microscopy, n (%)** | | | | |
| Nodular glomerulosclerosis | 131 (60) | 95 (53) | 22 (100)* | 14 (78)† |
| TBM thickening | 180 (82) | 151 (84) | 15 (68) | 14 (78) |
| Tubular atrophy and interstitial fibrosis | | | | |
| Mild/moderate | 126 (57) | 101 (56) | 13 (59) | 12 (67) |
| Severe | 68 (31) | 59 (33) | 4 (18) | 5 (28) |
| Arteriosclerosis | | | | |
| Mild/moderate | 103 (47) | 82 (46) | 11 (50) | 7 (39) |
| Severe | 32 (15) | 26 (14.4) | 3 (13.6) | 3 (16.7) |
| CN | 58 (26) | 58 (32) | 0* | 0† |
| Amyloidosis | 4 (2) | 4 (2) | 0 | 0 |
| **IF, n (%)** | | | | |
| Linear TBM deposits | 220 (100) | 180 (100) | 22 (100) | 18 (100) |
| Linear GBM deposits | 180 (82) | 143 (79) | 20 (90) | 17 (94) |
| Light chain isotype (κ/λ) | 157/41 | 143/37 | 0/0 | 14/4 |
| Heavy chain isotype (γ/α/μ) | 35/4/1 | 0/0/0 | 18/4/0 | 17/0/1 |
| γ HC subtypes (γ1/γ3/γ4)‡ | — | — | 14/1/3 | 5/0/1 |
| **EM, n (%)** | 56 (25.5) | 38 (21.1) | 11 (50) | 7 (38.9) |
| GBM deposits | 34 (61) | 19 (50) | 11 (100)* | 4 (57) |
| TBM deposits | 39 (69) | 28 (74) | 11 (100) | 2 (29) |
| Mesangium | 25 (45) | 15 (39) | 9 (82)* | 1 (14) |
| Vascular | 10 (18) | 7 (18) | 3 (27) | 0 |

*$P < .05$, comparison between LCDD and HCDD.

†$P < .05$, comparison between LCDD and LHCDD.

‡Data available in only 6 LHCDD patients.

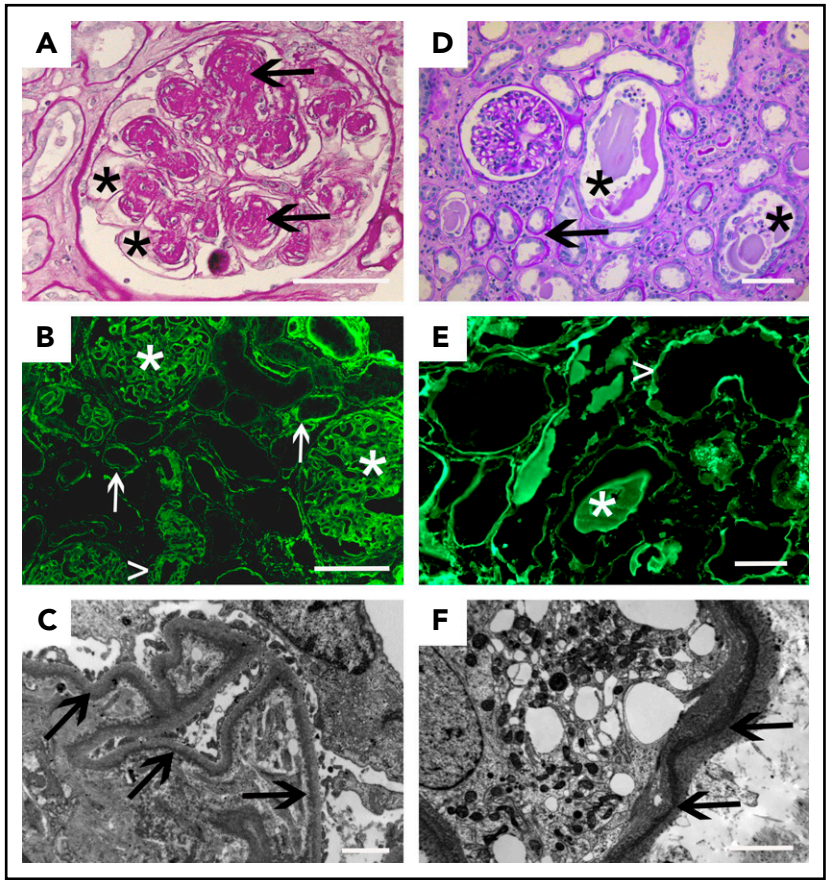


**Figure 2. Renal pathological findings.** (A-C) Pure LCDD. (A) Light microscopy (Periodic acid–Schiff staining, original magnification ×400). Section of renal cortex showing nodular glomerulosclerosis with nodular mesangial deposits (arrows) and aneurysmal dilatation of the capillary lumens (asterisks). Bar = 50 μm. (B) IF microscopy (anti-κ fluorescein isothiocyanate conjugate, original magnification ×200). Linear deposits along glomerular (asterisks) and tubular (arrows) basement membranes, and around vascular myocytes (arrowhead). Bar = 50 μm. (C) EM (original magnification ×12 000). Linear electron dense deposits predominating in the inner aspect of the GBM. Bar = 1 μm. (D-F) LCDD with CN. (D) Light microscopy (Periodic acid–Schiff staining, original magnification ×200). Section of renal cortex showing TBMs thickening (arrow) and typical fractured casts in distal tubules with giant cells and tubulorrhexis (asterisks). Note the roughly normal appearance of the glomerulus. Bar = 50 μm. (E) IF microscopy (anti-λ fluorescein isothiocyanate conjugate, original magnification ×200). Linear deposits along TBMs (arrowhead) and casts within distal tubule lumens (asterisks). (F) Enlarged multilayered TBM with electron-dense (arrows) powdery punctuate deposits predominating in the outer aspect (EM, original magnification ×15 000). Bar = 1 μm.

monotypic LC deposits, around myocytes and in cardiac vascular walls, in bronchiolar and arteriolar basement membranes, in endoneurial microvessels, and around myelin sheaths, respectively (Figure 3).

## Molecular biology data

LC sequences were obtained in 18 patients with LCDD or LHCDD. Mutations possibly affecting LC structure, charge, or hydrophobicity are recapitulated in supplemental Figure 1. We confirmed the overrepresentation of the $V_k4$ (n = 5) variability subgroup. Appearance of *N*-glycosylation sites was observed in the FR3 regions of 4 sequences (patients 5, 7, 15, and 17) due to the same D>N mutation in position 86. Another de novo *N*-glycosylation was seen in the CDR3 of patient 10. LC sequencing also revealed a biased usage of $V_k$ subgroups with long CDR1 like $V_k4$ (12 nucleotides, n = 6), $V_k2$-28 (11 nucleotides, n = 3), and $V_k3$-20 (7 nucleotides, n = 2) instead of the canonical 6-nucleotides-long CDR1. Because a high pI was previously suspected to be involved in the deposition of LC in negatively charged basement membranes, we calculated the theorical pI of entire V regions and of combined CDRs of the LCs.[28] Results were compared with a set of other unpublished LC sequences from patients with AL amyloidosis or LC-Fanconi syndrome. In contrast with previously published HCDD HCs sequences,[23] we did not find any differences in the pIs of complete V regions. However, we observed a striking elevation of pI values in the combined CDRs of LCDD LCs compared with controls (8.20 ± 0.46 vs 4.37 ± 0.38, mean ± standard error of the mean) (Figure 4).

## Chemotherapy regimens

Data on treatment were available for 176 patients (supplemental Table 2). Among these, 169 patients received chemotherapy. Ninety-five patients (56.3%) were given 1 line of treatment, whereas 36 received 2 lines (21.4%) and 37 required 3 or more (21.9%). Chemotherapy consisted of bortezomib- (n = 98, 58%), alkylator- (n = 28, 17%), thalidomide/lenalidomide- (n = 17, 10%), adriamycin- (n = 16, 9.5%), rituximab-based therapy (n = 4, 2.4%) or steroids alone (n = 1, 0.6%). Patients received a median of 4 cycles (3-6). High-dose melphalan and autologous stem cell transplantation (HDM/ASCT) was performed in 38 patients, including 31 with myeloma, after a median time of 5 (5.9-9.2) months from diagnosis. Median age at HDM/ASCT was 53 years (46-60); median eGFR was 41 mL/min/1.73 $m^2$, and 4 patients were on chronic hemodialysis.

Treatment-related toxicity was reported in 68 patients (40%), 30 of whom experienced serious adverse events (supplemental Table 3). Among 98 patients who received bortezomib, adverse events were recorded in 34 (37%), most commonly peripheral neuropathy (n = 30, 32%), leading to premature discontinuation in 4 patients. Eight of the 16 patients treated with adriamycin experienced cardiac toxicity. One patient who underwent HDM/ASCT on chronic dialysis died of cerebral hemorrhage 10 days after the procedure.

## Response and outcomes

Among 169 treated patients, hematological response rate was 67%, with CR and VGPR rates of 28% (n = 50) and 24% (n = 43),

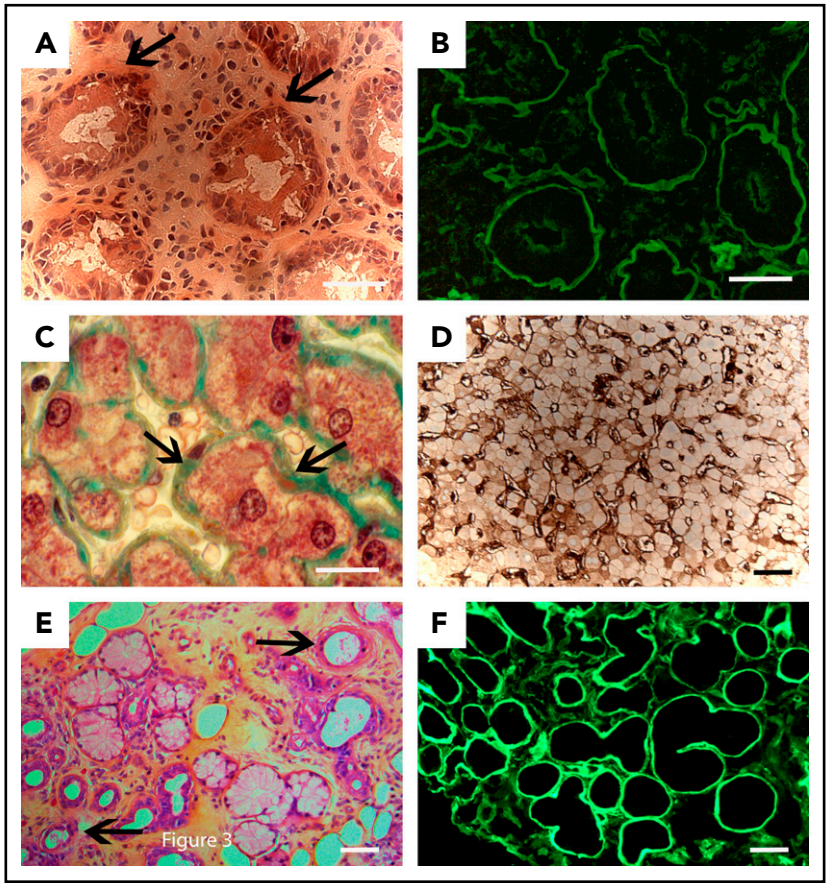


**Figure 3. Extrarenal pathological findings.** (A-B) Duodenal biopsy. (A) Light microscopy (hematoxylin and eosin staining, original magnification ×400). Crypt atrophy and deposits (arrows) within the basement membranes of the mucosa. (B) IF microscopy (anti-κ fluorescein isothiocyanate conjugate, original magnification ×400). Linear deposits along the basement membranes of the mucosa and around vascular myocytes. (C-D) Liver biopsy. (C) Light microscopy (Masson's trichrome staining, original magnification ×400). Deposits along sinusoids within Disse spaces. (D) Immunohistochemistry (anti-κ antibody, original magnification ×200). Diffuse linear deposits in Disse spaces. (E-F) Minor salivary gland biopsy. (E) Light microscopy (hematoxylin and eosin staining, original magnification ×200). Deposits along glandular basement membranes and around vascular myocytes (arrows). (F) IF microscopy (anti-κ fluorescein isothiocyanate conjugate, original magnification ×200). Linear deposits along glandular basement membranes. Bars = 50 μm.

respectively. Response rate was similar among MIDD subtypes and among patients with symptomatic myeloma (63.0%) or MGRS (73.7%) ($P = .18$; supplemental Table 4). VGPR or CR was achieved in 47.9% of patients with myeloma, and in 58.9% of patients with MGRS ($P = .16$). By univariate analysis, factors associated with hematological response were age (62 vs 68 years in nonresponders, $P = .003$), bortezomib-based therapy ($P < .0001$), HDM/ASCT ($P < .0001$), and diagnosis after 2004 (67% vs 26%, $P < .0001$). VGPR/CR rate was higher in patients treated with first-line bortezomib (60 vs 25%, $P < .0001$; supplemental Table 5).

Renal response occurred in 62 patients (36%), all of whom had achieved hematological response (Table 3). In renal responders, proteinuria decreased by 89% and eGFR improved from 22.9 mL/min/1.73 m$^2$ (12.6-36.2) at baseline to 42.6 mL/min/1.73 m$^2$ at last follow-up. Patients who achieved renal response had higher baseline eGFR (22.9 [12.6-36.3] vs 14.40 [7.0-29.6] mL/min/1.73 m$^2$, respectively, $P = .004$). In univariate analysis, factors associated with renal response were hematological response ≥ VGPR (odds ratio [OR] 5.58; 95% confidence interval [CI] 2.77-11.24; $P < .0001$), bortezomib-based therapy (OR 3.23 95% CI 1.57-6.65; $P = .0005$), dialysis at diagnosis (OR 0.17, 95% CI 0.06-0.51, $P = .0006$), diagnosis after 2004 (OR 4.35, 95% CI 1.85-10, $P = .0007$), absence of severe interstitial fibrosis and tubular atrophy (IFTA) (OR 2.78, 95% CI 1.37-5.56, $P = .004$), absence of severe arteriosclerosis (OR 3.84, 95% CI 1.08-14.3, $P = .04$). In multivariate analysis, predictive factors of renal response were hematological response ≥ VGPR (OR 4.14 95% CI 1.75-9.83), absence of severe IFTA (OR 3.45, 95% CI 1.45-8.33), and diagnosis after 2004 (OR 3.70, 95% CI 1.25-11.1).

After median follow-up of 27.3 months (10-70), 58 patients had progressed to ESRD (supplemental Figure 2A). Renal survival was associated with the quality of hematological response (VGPR/CR), and with renal response (Table 4; Figure 5A). Renal survival at 36 months was 86% in patients with and without VGPR/CR, respectively, and 91% vs 63% in renal responders vs nonresponders ($P < .0001$; Figure 5B). Median renal survival was 88 months vs 209 months in patients with baseline eGFR <30 mL/min/1.73 m$^2$ compared with those with eGFR ≥30 mL/min/1.73 m$^2$ ($P = .005$; Figure 4C). In patients with LCDD-CN, median renal survival was 81.6 months vs unreached ($P = .06$) in patients with pure LCDD (Figure 4D). Renal survival was significantly lower in patients with myeloma (97 vs 215 months, $P = .02$; supplemental Figure 3A). Several factors were selected for multivariate analysis: baseline eGFR <30 mL/min/1.73 m$^2$, AKI at diagnosis, symptomatic myeloma, hematological response, HDM/ASCT, renal response, IFTA. Only baseline eGFR <30 mL/min/1.73 m$^2$ (relative risk [RR] 6.62, 95% CI 2.04-21.49, $P = .0017$), AKI (RR 3.53, 95% CI 1.91-6.50, $P < .0001$), and renal response (RR 0.13, 95% CI 0.06-0.32, $P < .0001$) were independently associated with renal survival (Figure 5). In patients with MGRS, response ≥ VGPR was associated with higher renal survival (supplemental Figure 4A).

At the time of censoring, 71 patients had died after a median of 14 (13-48) months from diagnosis (supplemental Figure 2B).

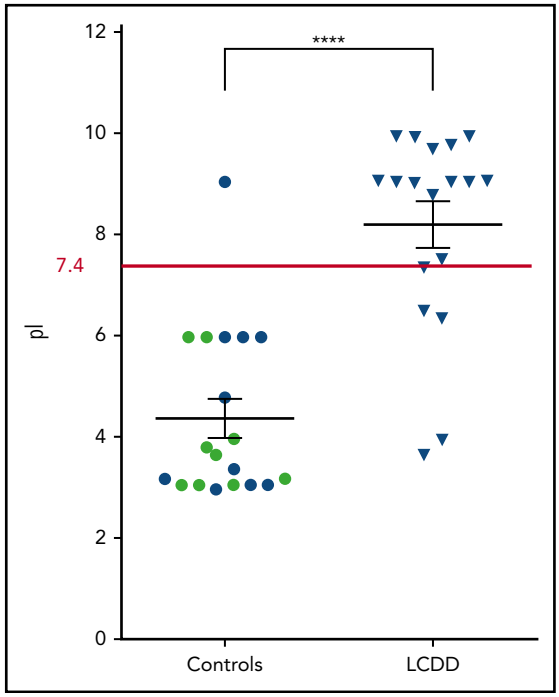


**Figure 4. Calculated pI of combined CDRs (CDR1⁺CDR2⁺CDR3) in κ LCs from LCDD or control patients.** Blood pH is indicated by the red line. Control LCs were from patients with AL amyloidosis (green dots) and Fanconi syndrome (blue dots). There was no difference between the 2 control groups (not shown). ****$P < .0001$ (Mann-Whitney *U* test).

Causes of death were myeloma progression (n = 26, 14.8%), sepsis (n = 16, 9.1%), cardiovascular event (n = 8, 4.5%), other neoplasia (n = 5, 2.8%), hemorrhage (n = 2, 1.2%), and unknown (n = 14, 8%). OS at 36 months was 88% vs 44% in patients who achieved or not VGPR/CR, respectively ($P = .001$), and 87% vs 60% in patients with or without renal response ($P < .0001$; Figure 6A-B). Median OS was 65.4 months in patients with baseline eGFR <30 mL/min/1.73 m² vs unreached in those with higher eGFR ($P = .0015$; Figure 6C). Median OS was shorter in LCDD-CN compared with pure LCDD (28 vs 140 months, $P = .006$; Figure 6D; supplemental Figure 3B). In multivariate analysis, factors associated with mortality were hematological response ≥ VGPR (OR 0.32, 95% CI 0.17-0.60, $P < .0001$), renal response (OR 0.28, 95% CI 0.14-0.56; $P < .0001$), associated CN (OR 1.91, 95% CI 1.15-3.17; $P = .0008$), age >75 (OR 4.14, 95% CI 2.40-7.12, $P < .0001$). Use of bortezomib resulted in higher renal and patient survival (supplemental Figure 5). In patients with MGRS, OS was also associated with hematological response (supplemental Figure 4B).

Twenty-three patients (LCDD, n = 20; LHCDD, n = 2; HCDD, n = 1) received a kidney transplant from a cadaveric donor. In 9 patients, MIDD was diagnosed after recurrence on the allograft, after a median time of 32 months (23-42) after transplantation. Seven received chemotherapy, and graft loss occurred in 4, within a median of 46 (40-52.5) months and 12 (9-24) months from transplantation and diagnosis of MIDD, respectively. In the remaining 14 patients, renal transplantation was performed after a median of 54 months (31-98) following diagnosis of MIDD on native kidneys. All had achieved hematological response prior to transplantation. Disease recurrence occurred in 4 cases after a median of 38 (32.5-42) months. All received chemotherapy, and only 1 patient experienced graft failure after 60 months. After median follow-up of 89 months (35-163), among 23 transplanted patients, 3 had died (2 with a functional graft), and 5 had graft failure because of recurrence (including 4 patients diagnosed with MIDD after transplantation). Sixteen patients had functional renal allograft with median eGFR of 46 mL/min/1.73 m² (42-58).

## Discussion

The present large series provides novel insights into the clinicopathological characteristics and prognosis of MIDD. First, it highlights that renal disease is heterogeneous, depending on the nature of deposited monoclonal immunoglobulin and underlying hematological disorder. Pure LCDD is the most frequent type, typically associated with MGRS and presenting with chronic glomerular disease. Rarely, it manifests with slowly progressive CKD without significant proteinuria, leading to delayed diagnosis. In this setting, glomerulosclerosis is uncommon, and deposits predominate in the renal vascular and tubular compartments.[8,21] In contrast, LCDD occurring in the setting of symptomatic myeloma frequently coexists with CN. The high frequency of this association in our series might be biased, because in routine practice, the severity of AKI usually dictates the indication of kidney biopsy in myeloma patients. LCDD-CN has similar presenting features and outcomes as pure CN and differs from pure MIDD by significantly higher dFLC levels, a condition required for the formation of LC casts.[7,29,30] Histologically, nodular glomerulosclerosis is absent, and the diagnosis relies on IF showing linear LC deposits along basement membranes, a finding referred to as LCDD "by IF only."[7] HCDD is a homogeneous entity, almost invariably related to MGRS, and characterized by frequent hypertension, heavy proteinuria, nephrotic syndrome, progressive CKD, and constant nodular glomerulosclerosis, the pathological hallmark of the disease.[23] LHCDD displays clinicopathological features resembling pure LCDD. These results suggest that the diagnosis of MIDD should be considered even in the absence of typical glomerular symptoms and reinforce the diagnostic value of kidney biopsy in patients with monoclonal gammopathy-associated renal disease.

The systemic nature of MIDD is likely to have been underrecognized. Extrarenal manifestations, mostly liver and heart disease, were reported in ~4% of patients from previous series.[13,14] In our cohort, 35% of patients had symptomatic extrarenal involvement, histologically confirmed in 12%, with a wide range of affected organs. Liver, heart, and peripheral nerve manifestations were the most common, with a higher prevalence in pure LCDD. In a recent series of 69 LCDD patients, 85% of whom with MM, cardiac involvement was confirmed by endomyocardial biopsy in 33%.[6] In our cohort, symptomatic cardiac disease was observed mostly in patients with pure LCDD and MGRS, suggesting that the pattern of organ involvement is determined by molecular characteristics of the pathogenic monoclonal immunoglobulin, rather than by tumor mass. Only 7 patients (2.8%) had prominent extrarenal involvement with hepatic, cardiac, and pulmonary symptoms. This differs from systemic AL amyloidosis where the prevalence of heart and liver involvement is ~60% and 30%, respectively.[18] As in AL amyloidosis, cardiac disease manifests with hypertrophic cardiomyopathy, diastolic dysfunction, conduction blocks, and arrhythmia.[31] This highlights the importance of careful clinical workup in MIDD, including systematic Doppler

**Table 3. Characteristics of renal responders**

| | Renal responders (n = 62) | Nonresponder (n = 104) | *P* |
|---|---|---|---|
| Age, y (range) | 62.4 (50.7-73.6) | 64.5 (57.3-74.5) | ns |
| Diagnosis before 2004, n (%) | 8 (12.9) | 44 (42.3) | <.0001 |
| MIDD type, n (%) | LCDD (n = 51)<br>LHCDD (n = 3)<br>HCDD (n = 8) | LCDD (n = 86)<br>LHCDD (n = 8)<br>HCDD (n = 10) | ns |
| eGFR at diagnosis, mL/min/1.73 m$^2$ (range) | 23.0 (12.6-36.3) | 14.4 (7.0-29.6) | .004 |
| RRT requirement at diagnosis, n (%) | 4 (6.5) | 30 (28.8) | .0006 |
| 24-h proteinuria (g) | 2.0 (0.9-4.9) | 1.5 (0.7-3.5) | ns |
| Symptomatic myeloma, n (%) | 22 (35.5) | 47 (45.2) | ns |
| dFLC at diagnosis, mg/L (range) | 1478 (146-4768) | 875 (141-2990) | ns |
| VGPR/CR, n (%) | 47 (75.8) | 42 (40.4) | <.0001 |
| **Data at last follow-up** | | | |
| eGFR, mL/min/1.73 m$^2$ (range) | 42.6 (26.6-58.9) | 27.2 (20.4-33.6) | .005 |
| ESRD, n (%) | 8 (12.9) | 63 (60.6) | <.0001 |
| Death, n (%) | 12 (19.4) | 58 (55.8) | <.0001 |
| **Treatment received** | | | |
| Bortezomib-based regimen, n (%) | 51 (82.3) | 55 (52.9) | .0001 |
| No treatment, n (%) | 0 | 5 (4.8) | ns |

eGFR, estimated glomerular filtration rate; ESRD, end-stage renal disease; ns, not significant; RRT, renal replacement therapy.

echocardiography and measurement of NT-proBNP and troponin levels.[6] Cardiac involvement was not associated with adverse prognosis in our patients, suggesting a potentially less severe course of LCDD-related cardiomyopathy compared with AL amyloidosis. However, the small sample size is a limitation, and heart disease in LCDD was recently reported to increase mortality after HDM/ASCT.[6]

One patient had isolated lung involvement, with cystic pneumopathy, emphysematous bronchial dilatation, and chronic obstructive pulmonary disease. Primary cystic lung LCDD, mostly observed in young adults, is a localized process, that derives from locally infiltrating clonal B cells characterized by the expression of IGHV4-34 and Vkappa 1 subgroup corresponding to MALT lymphoma.[5,32] Lung transplantation may allow acceptable survival without disease recurrence.[33] Although thyroid, lung, skin, esophagus, and liver involvement has been reported, symptomatic extrarenal disease appears uncommon in HCDD.[23] We confirmed a peculiar association with cutis laxa, present in 3 out of 18 γHCDD patients. Cutis laxa is a rare disorder characterized by loss of skin elasticity, secondary to elastic tissue destruction through release of elastase following complement activation induced by monoclonal HC deposition.[34]

The present work provides novel data on LC molecular characteristics in LCDD that bear striking homologies including

**Table 4. Factors associated with renal survival**

| | Univariate analysis RR (95% CI) | *P* | Multivariate analysis RR (95% CI) | *P* |
|---|---|---|---|---|
| eGFR <30 mL/min/1.73 m$^2$ | 9.56 (2.98-30.73) | .0002 | 6.62 (2.04-21.49) | .002 |
| LCDD + CN | 2.73 (1.58-4.72) | .0003 | | |
| Severe IFTA | 2.13 (1.09-4.16) | .0277 | | |
| AKI at diagnosis | 3.14 (1.83-5.40) | <.0001 | 3.53 (1.91-6.50) | <.0001 |
| VGPR or CR | 0.45 (0.26-0.78) | .0047 | | |
| HDM/ASCT | 0.26 (0.10-0.67) | .0053 | | |
| Renal response | 0.15 (0.07-0.36) | <.0001 | 0.13 (0.06-0.32) | <.0001 |

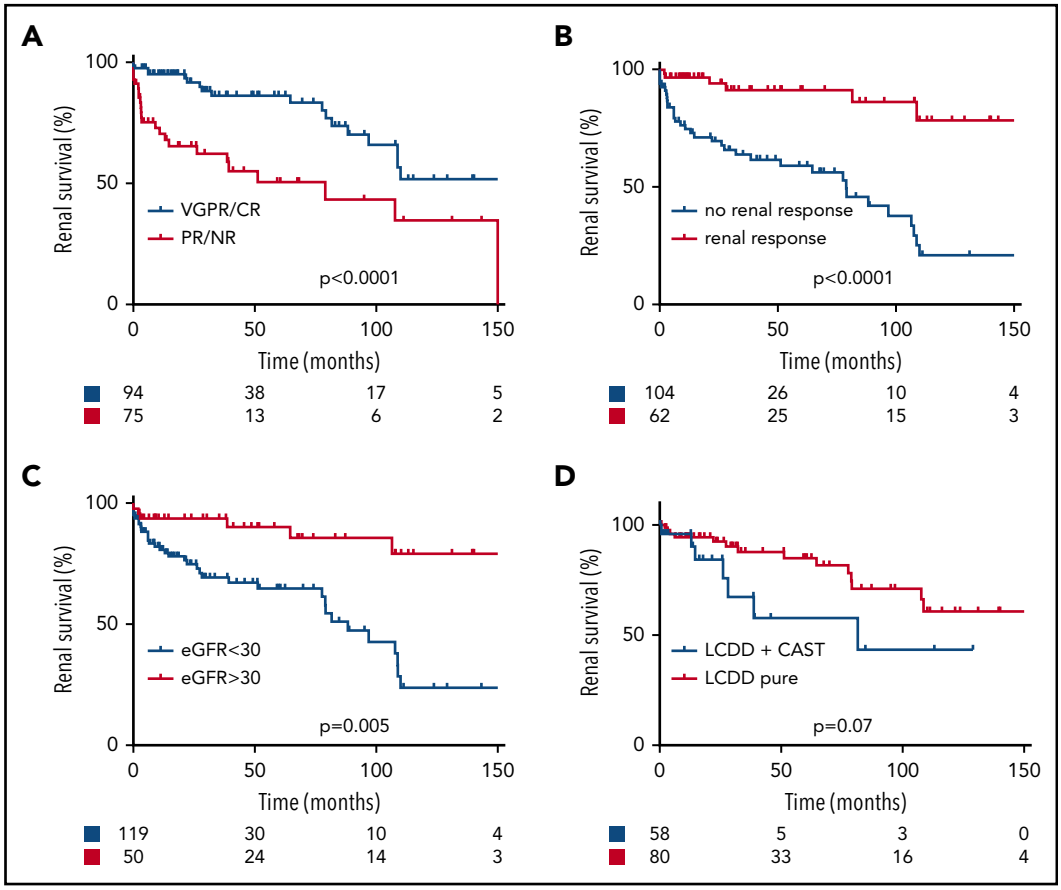


**Figure 5. Renal survival.** Kaplan-Meier curves of renal survival according to (A) hematological response (n = 169), (B) renal response (n = 166), (C) baseline eGFR (n = 169), (D) LCDD with or without associated CN (n = 138). Time to event was calculated from the day of the diagnosis of MIDD (D0). Renal survival proportions at 12, 36, and 60 months were 95%, 86%, 86% vs 70%, 62%, 51% in patients with and without VGPR/CR, respectively, and 97%, 91%, 91% vs 74%, 63%, 59% in renal responders vs nonresponders ($P < .0001$). NR, no response; PR, partial response.

cationic combined CDRs potentially involved in their propensity to deposit on negatively charged basement membranes, a long CDR1 with a bias for Vκ4 usage and the frequent appearance of *N*-glycosylation sites, which may favor LC aggregation. These features deserve to be explored in experimental models to better understand the process of LC deposition.

Hematological response appears as the main prognostic factor in MIDD. We found that FLC levels, which were abnormal in all types of MIDD, including HCDD, are reliable markers of treatment efficacy. Achievement of VGPR and the absence of severe fibrosis on diagnostic renal biopsy were independent predictors of renal response. Despite the limitations of a retrospective study, early diagnosis, introduction of clone-targeted chemotherapy, and evaluation of treatment efficacy based on FLC monitoring appear as the cornerstones of management. Treatment of patients with LCDD-CN is similar to that of symptomatic myeloma. In patients with MGRS-associated MIDD, VGPR defined as dFLC <40 mg/L should be the goal of chemotherapy, more likely to be achieved with bortezomib-based regimens. Indeed, renal and patient outcomes dramatically improved in patients diagnosed after 2004, when both FLC measurement and bortezomib became available. Bortezomib which does not require dose adaptation to GFR level was well tolerated, despite mostly used through an IV route. Systematic subcutaneous administration will probably result in improved tolerance profile.[35] Hematological response rate was 67% (including VGPR or above in 52%), close to that observed with bortezomib-based chemotherapy in systemic AL amyloidosis or MM.[36-39] In a transgenic mouse HCDD model, we showed that bortezomib induced a strong decrease of renal deposits, and that the presence of the isolated truncated HC sensitized plasma cells to bortezomib through an elevated unfolded protein response.[40] HDM/ASCT also provided high hematological and renal response rates. However, the procedure is associated with increased morbidity and mortality in patients with eGFR <30 mL/min/1.73 $m^2$.[41] Because of the efficacy of novel antimyeloma agents with sustained hematological responses, the current place of HDM/ASCT in the therapeutic strategy of MGRS-associated MIDD is questionable. It remains to be evaluated in young patients, with refractory or rapidly relapsing disease.

Finally, our study provides novel data on long-term outcomes after kidney transplantation in MIDD. As previously reported, graft survival was very poor in patients who did not receive chemotherapy before transplantation, or in those diagnosed with MIDD after recurrence on the allograft.[42] However, patients transplanted after stable hematological response showed acceptable graft and OS. Thus, as in AL amyloidosis, renal transplantation appears as a valuable option in selected patients with sustained VGPR or CR prior to the procedure.

In conclusion, the present series highlights the clinical heterogeneity of MIDD depending on both the nature of the involved monoclonal immunoglobulin and the characteristics of the underlying hematological disease, with an underestimated frequency

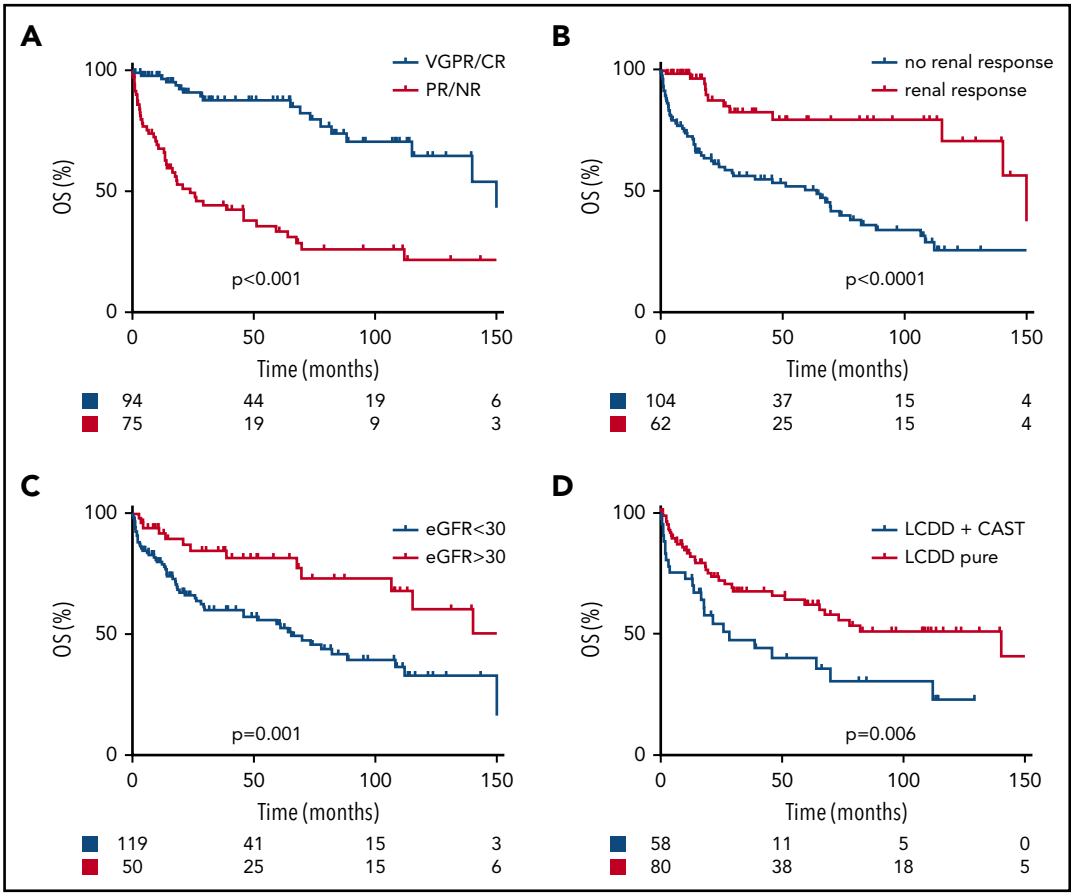


**Figure 6. Overall survival.** Kaplan-Meier curves of OS according to (A) hematological response (n = 169), (B) renal response (n = 166), (C) baseline eGFR (n = 169), (D) LCDD with or without associated CN (n = 138). Time to event was calculated from the day of the diagnosis of MIDD (D0). OS proportions at 12, 36, and 60 months were 96%, 88%, 88%, vs 68%, 44%, 33% in patients who achieved VGPR/CR or not, respectively ($P = .001$), and 98%, 87%, 79% vs 73%, 60%, 50% in patients with or without renal response, respectively ($P < .0001$)

of extrarenal involvement. Thanks to the use of novel antimyeloma agents and reliable monitoring of hematological response, the prognosis of MIDD has been transformed over the last 15 years. Early diagnosis remains a necessary condition for prolonged renal and patient survival.

## Acknowledgment

The authors thank the physicians who provided data.

## Authorship

Contribution: F.J. and C.C. collected data; F.J., C.C., V.J., C.S., and F.B. designed the study and wrote the manuscript; S.B. and C.S. performed the experiment from Figure 4; B.A., B.K., M.B., M.N., V.A., A.J., F.P., and J.P.F. actively corrected the manuscript and provided data; and D.N., V.G., J.M.G., and G.T. provided pathological data.

Conflict-of-interest disclosure: The authors declare no competing financial interests.

Correspondence: Frank Bridoux, Deparment of Nephrology, 2, rue de la Milétrie, Poitiers, 86021 France; e-mail: frank.bridoux@chu-poitiers.fr.

## Footnotes

Submitted 17 September 2018; accepted 15 December 2018. Prepublished online as *Blood* First Edition paper, 21 December 2018; DOI 10.1182/blood-2018-09-872028.

*F.J. and C.C. contributed equally to this study.

The online version of this article contains a data supplement.

The publication costs of this article were defrayed in part by page charge payment. Therefore, and solely to indicate this fact, this article is hereby marked "advertisement" in accordance with 18 USC section 1734.

## REFERENCES

1. Bridoux F, Leung N, Hutchison CA, et al; International Kidney and Monoclonal Gammopathy Research Group. Diagnosis of monoclonal gammopathy of renal significance. *Kidney Int.* 2015;87(4):698-711.

2. Preud'homme JL, Aucouturier P, Touchard G, et al. Monoclonal immunoglobulin deposition disease (Randall type). Relationship with structural abnormalities of immunoglobulin chains. *Kidney Int.* 1994;46(4):965-972.

3. Pozzi C, D'Amico M, Fogazzi GB, et al. Light chain deposition disease with renal involvement: clinical characteristics and prognostic factors. *Am J Kidney Dis.* 2003;42(6):1154-1163.

4. Samanez C, Domingo A, Cibeira MT, Miquel R, Soler M, Bladé J. Development of rapidly progressive liver light chain deposition under VAD chemotherapy in multiple myeloma. *Eur J Haematol.* 2006;76(1):83-85.

5. Colombat M, Mal H, Copie-Bergman C, et al. Primary cystic lung light chain deposition disease: a clinicopathologic entity derived from unmutated B cells with a stereotyped IGHV4-34/IGKV1 receptor. *Blood.* 2008;112(5):2004-2012.

6. Mohan M, Buros A, Mathur P, et al. Clinical characteristics and prognostic factors in multiple myeloma patients with light chain deposition disease. *Am J Hematol*. 2017;92(8):739-745.

7. Lin J, Markowitz GS, Valeri AM, et al. Renal monoclonal immunoglobulin deposition disease: the disease spectrum. *J Am Soc Nephrol*. 2001;12(7):1482-1492.

8. Cohen C, Royer B, Javaugue V, et al. Bortezomib produces high hematological response rates with prolonged renal survival in monoclonal immunoglobulin deposition disease. *Kidney Int*. 2015;88(5):1135-1143.

9. Nasr SH, Valeri AM, Cornell LD, et al. Renal monoclonal immunoglobulin deposition disease: a report of 64 patients from a single institution. *Clin J Am Soc Nephrol*. 2012;7(2):231-239.

10. Leung N, Bridoux F, Hutchison CA, et al; International Kidney and Monoclonal Gammopathy Research Group. Monoclonal gammopathy of renal significance: when MGUS is no longer undetermined or insignificant. *Blood*. 2012;120(22):4292-4295.

11. Fermand J-P, Bridoux F, Kyle RA, et al; International Kidney and Monoclonal Gammopathy Research Group. How I treat monoclonal gammopathy of renal significance (MGRS). *Blood*. 2013;122(22):3583-3590.

12. Denoroy L, Déret S, Aucouturier P. Overrepresentation of the V kappa IV subgroup in light chain deposition disease. *Immunol Lett*. 1994;42(1-2):63-66.

13. Sayed RH, Wechalekar AD, Gilbertson JA, et al. Natural history and outcome of light chain deposition disease. *Blood*. 2015;126(26):2805-2810.

14. Kourelis TV, Nasr SH, Dispenzieri A, et al. Outcomes of patients with renal monoclonal immunoglobulin deposition disease. *Am J Hematol*. 2016;91(11):1123-1128.

15. Gkotzamanidou M, Terpos E, Kastritis E, Dimopoulos MA. Hematologic response and stabilization of renal function in a patient with light chain deposition disease after lenalidomide treatment: a novel therapeutic approach? *Clin Lymphoma Myeloma Leuk*. 2014;14(5):e179-e181.

16. Fujita H, Hishizawa M, Sakamoto S, et al. Durable hematological response and improvement of nephrotic syndrome on thalidomide therapy in a patient with refractory light chain deposition disease. *Int J Hematol*. 2011;93(5):673-676.

17. Adamu B, Al-Ghamdi M, Ahmad M, Alsaad KO. Treatment of light chain deposition disease using bortezomib-based regimen followed by thalidomide-based regimen in a Saudi male. *Case Rep Nephrol*. 2016;2016:7485695.

18. Palladini G, Dispenzieri A, Gertz MA, et al. New criteria for response to treatment in immunoglobulin light chain amyloidosis based on free light chain measurement and cardiac biomarkers: impact on survival outcomes. *J Clin Oncol*. 2012;30(36):4541-4549.

19. Owen RG, Treon SP, Al-Katib A, et al. Clinicopathological definition of Waldenstrom's macroglobulinemia: consensus panel recommendations from the Second International Workshop on Waldenstrom's Macroglobulinemia. *Semin Oncol*. 2003;30(2):110-115.

20. International Myeloma Working Group. Criteria for the classification of monoclonal gammopathies, multiple myeloma and related disorders: a report of the International Myeloma Working Group. *Br J Haematol*. 2003;121(5):749-757.

21. Sicard A, Karras A, Goujon J-M, et al. Light chain deposition disease without glomerular proteinuria: a diagnostic challenge for the nephrologist. *Nephrol Dial Transplant*. 2014;29(10):1894-1902.

22. Dimopoulos MA, Terpos E, Chanan-Khan A, et al. Renal impairment in patients with multiple myeloma: a consensus statement on behalf of the International Myeloma Working Group. *J Clin Oncol*. 2010;28(33):4976-4984.

23. Bridoux F, Javaugue V, Bender S, et al. Unravelling the immunopathological mechanisms of heavy chain deposition disease with implications for clinical management. *Kidney Int*. 2017;91(2):423-434.

24. Beaume A, Brizard A, Dreyfus B, Preud'homme JL. High incidence of serum monoclonal Igs detected by a sensitive immunoblotting technique in B-cell chronic lymphocytic leukemia. *Blood*. 1994;84(4):1216-1219.

25. Bridoux F, Sirac C, Hugue V, et al. Fanconi's syndrome induced by a monoclonal Vkappa3 light chain in Waldenstrom's macroglobulinemia. *Am J Kidney Dis*. 2005;45(4):749-757.

26. Brochet X, Lefranc M-P, Giudicelli V. IMGT/V-QUEST: the highly customized and integrated system for IG and TR standardized V-J and V-D-J sequence analysis. Nucleic Acids Res. 2008;36(Web Server issue):W503-508.

27. Kozlowski LP. IPC - isoelectric point calculator. *Biol Direct*. 2016;11(1):55.

28. Oruc Z, Oblet C, Boumediene A, et al. IgA structure variations associate with immune stimulations and IgA mesangial deposition. *J Am Soc Nephrol*. 2016;27(9):2748-2761.

29. Zand L, Nasr SH, Gertz MA, et al. Clinical and prognostic differences among patients with light chain deposition disease, myeloma cast nephropathy and both. *Leuk Lymphoma*. 2015;56(12):3357-3364.

30. Hutchison CA, Batuman V, Behrens J, et al; International Kidney and Monoclonal Gammopathy Research Group. The pathogenesis and diagnosis of acute kidney injury in multiple myeloma. *Nat Rev Nephrol*. 2011;8(1):43-51.

31. Falk RH, Alexander KM, Liao R, Dorbala S. AL (light-chain) cardiac amyloidosis: a review of diagnosis and therapy. *J Am Coll Cardiol*. 2016;68(12):1323-1341.

32. Colombat M, Stern M, Groussard O, et al. Pulmonary cystic disorder related to light chain deposition disease. *Am J Respir Crit Care Med*. 2006;173(7):777-780.

33. Hirschi S, Colombat M, Kessler R, et al. Lung transplantation for advanced cystic lung disease due to nonamyloid kappa light chain deposits. *Ann Am Thorac Soc*. 2014;11(7):1025-1031.

34. O'Malley JT, D'Agati VD, Sherman WH, Grossman ME. Acquired cutis laxa associated with heavy chain deposition disease involving dermal elastic fibers. *JAMA Dermatol*. 2014;150(11):1192-1196.

35. Moreau P, Pylypenko H, Grosicki S, et al. Subcutaneous versus intravenous administration of bortezomib in patients with relapsed multiple myeloma: a randomised, phase 3, non-inferiority study. *Lancet Oncol*. 2011;12(5):431-440.

36. Venner CP, Lane T, Foard D, et al. Cyclophosphamide, bortezomib, and dexamethasone therapy in AL amyloidosis is associated with high clonal response rates and prolonged progression-free survival. *Blood*. 2012;119(19):4387-4390.

37. Palladini G, Sachchithanantham S, Milani P, et al. A European collaborative study of cyclophosphamide, bortezomib, and dexamethasone in upfront treatment of systemic AL amyloidosis. *Blood*. 2015;126(5):612-615.

38. Khan ML, Reeder CB, Kumar SK, et al. A comparison of lenalidomide/dexamethasone versus cyclophosphamide/lenalidomide/dexamethasone versus cyclophosphamide/bortezomib/dexamethasone in newly diagnosed multiple myeloma. *Br J Haematol*. 2012;156(3):326-333.

39. Cavo M, Pantani L, Pezzi A, et al. Bortezomib-thalidomide-dexamethasone (VTD) is superior to bortezomib-cyclophosphamide-dexamethasone (VCD) as induction therapy prior to autologous stem cell transplantation in multiple myeloma. *Leukemia*. 2015;29(12):2429-2431.

40. Bonaud A, Bender S, Touchard G, et al. A mouse model recapitulating human monoclonal heavy chain deposition disease evidences the relevance of proteasome inhibitor therapy. *Blood*. 2015;126(6):757-765.

41. Badros A, Barlogie B, Siegel E, et al. Results of autologous stem cell transplant in multiple myeloma patients with renal failure. *Br J Haematol*. 2001;114(4):822-829.

42. Leung N, Lager DJ, Gertz MA, Wilson K, Kanakiriya S, Fervenza FC. Long-term outcome of renal transplantation in light-chain deposition disease. *Am J Kidney Dis*. 2004;43(1):147-153.