

addressed. For example, VWF is essential for formation of storage organelles called Weibel-Palade bodies (WPBs), which also store Ang-2; loss of VWF has been shown to cause a tissue-specific increase of Ang-2 release and, intriguingly, synthesis *in vitro* and *in vivo*.^{3,8} This study, conversely, shows that ADAMTS13 deficiency results in decreased Ang-2 synthesis.¹ How does ADAMTS13 regulate Ang-2 expression, given that its effect on VWF is not known to affect WPB formation? These findings suggest that VWF may regulate Ang-2 levels not only through an intracellular WPB-dependent pathway, but also through extracellular signals that depend on the presence of HMW VWF multimers. This would open an entirely new chapter on the relationship between extracellular VWF and the function of the vascular endothelium. Also, regulation of Ang-2 by VWF appears to be context-specific, active in the heart but not in the lung⁸; does the same apply to ADAMTS13? This may have important implications for the possible therapeutic potential suggested by the authors, which will have to be addressed in specific disease settings.

Conflict-of-interest disclosure: The author declares no competing financial interests. ■

REFERENCES

- Xu H, Cao Y, Yang X, et al. ADAMTS13 controls vascular remodeling by modifying VWF reactivity during stroke recovery. *Blood*. 2017;130(1):11-22.
- Crawley JT, de Groot R, Xiang Y, Luken BM, Lane DA. Unraveling the scissile bond: how ADAMTS13 recognizes and cleaves von Willebrand factor. *Blood*. 2011;118(12):3212-3221.
- Starke RD, Ferraro F, Paschalaki KE, et al. Endothelial von Willebrand factor regulates angiogenesis. *Blood*. 2011;117(3):1071-1080.
- Lee M, Keener J, Xiao J, Long Zheng X, Rodgers GM. ADAMTS13 and its variants promote angiogenesis via upregulation of VEGF and VEGFR2. *Cell Mol Life Sci*. 2015;72(2):349-356.
- Schepke L, Murphy EA, Zarpellon A, et al. Notch promotes vascular maturation by inducing integrin-mediated smooth muscle cell adhesion to the endothelial basement membrane. *Blood*. 2012;119(9):2149-2158.
- Randi AM. Endothelial dysfunction in von Willebrand disease: angiogenesis and angiodysplasia. *Thromb Res*. 2016;141(2 suppl 2):S55-S58.
- Lenting PJ, Casari C, Christophe OD, Denis CV. von Willebrand factor: the old, the new and the unknown. *J Thromb Haemost*. 2012;10(12):2428-2437.
- Yuan L, Chan GC, Beeler D, et al. A role of stochastic phenotype switching in generating mosaic endothelial cell heterogeneity. *Nat Commun*. 2016;7:10160.

DOI 10.1182/blood-2017-05-781260

© 2017 by The American Society of Hematology

● ● ● CLINICAL TRIALS AND OBSERVATIONS

Comment on Rasche et al, page 30

Toward a GEP-based PET in myeloma

Elena Zamagni and Michele Cavo BOLOGNA UNIVERSITY SCHOOL OF MEDICINE

In this issue of *Blood*, Rasche et al provide the first evidence of the biological basis underlying the occurrence of false-negative scans with use of ¹⁸F-fluorodeoxyglucose (FDG) positron emission tomography (PET)/computed tomography (CT) in newly diagnosed transplant-eligible multiple myeloma (MM) patients.¹

According to the updated diagnostic criteria for MM,² the novel imaging techniques, including whole-body low-dose CT, magnetic resonance imaging (MRI), and PET/CT, are now considered a valuable tool for the diagnostic workup of MM because of their higher sensitivity and ability to detect bone damage at an earlier phase than whole-body radiograph. Several studies have demonstrated the usefulness of FDG-PET/CT at diagnosis, reporting a sensitivity and specificity for detection of bone lesions in

the range between 80% and 100%. Moreover, functional imaging techniques, such as PET and MRI, are able to distinguish between metabolically active and inactive sites of clonal proliferating plasma cells (PCs), thus allowing us to evaluate metabolic response to therapy.

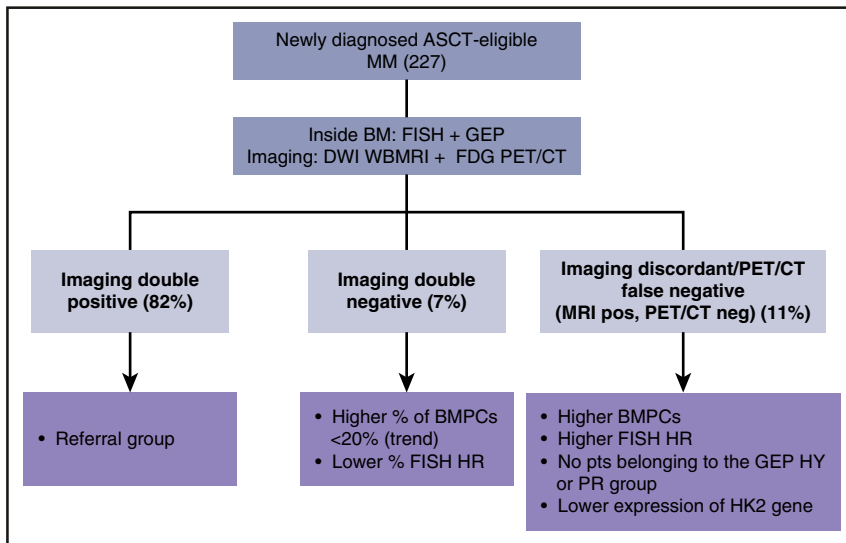
The unprecedented rates of high-quality responses afforded by more effective classes of novel agents and the association between the depth of response and long-term outcomes³ have recently led to refinement of the response criteria by using more sensitive techniques for

assessment of minimal residual disease (MRD), both inside and outside the bone marrow (BM).⁴ More specifically, owing to the patchy pattern of bone marrow plasma cell (BMPC) infiltration and the existence of extramedullary sites of clonal PCs, a new response category of imaging-MRD negativity has been identified, based on the disappearance of every area of increased tumor metabolism assessed with functional imaging techniques.

Almost 10 years ago, the Little Rock group first evaluated the role of FDG PET/CT in the context of the Total Therapy 3, demonstrating that PET-positive lesions at diagnosis and during/after the completion of therapy were predictive of prognosis.⁵ Several other independent studies confirmed the improved outcomes of patients achieving PET negativity after transplant, including those in conventionally defined complete remission.⁶ On the basis of these results, FDG PET/CT is actually considered the preferred imaging technique for evaluating and monitoring metabolic response to therapy.⁷ However, it is important to emphasize that both false-negative and false-positive results may occur with use of FDG PET/CT. In particular, false-negative scans can be related to hyperglycemia or recent administration of high-dose steroids, leading to a transient metabolic suppression. Moreover, it has been reported that, in a variable though not yet well-defined rate of patients, PCs may not be FDG avid.

In addition to FDG, new PET/CT tracers targeting different metabolic pathways or receptors expressed by MM cells, and acting as molecular imaging biomarkers, potentially more sensitive, have been preliminarily investigated in limited series of MM patients; however, their lower availability, the lack of direct comparisons with FDG, and the interpatient tumor heterogeneity regarding specific targets prevent any definite conclusion from being drawn.^{8,9}

Initial experience with functional MRI approaches, such as diffusion weighted imaging (DWI), enabling quantitative assessment of disease burden by quantifying the molecular diffusion of body water and the microcirculation of blood in the capillary network, showed a high sensitivity of the technique, in particular for detection of diffuse BMPC infiltration, a higher correlation with BM trephine samples in comparison with PET/CT, and the capability to identify



Assessment of newly diagnosed MM inside and outside the BM. ASCT, autologous stem cell transplantation; FISH, fluorescence in situ hybridization; HK2, hexokinase-2, HR, high risk; HY, hyperdiploid; neg, negative; pos, positive; PR, proliferative; pts, patients; WBMRI, whole-body magnetic resonance imaging.

significant changes in patients in remission after therapy.¹⁰ However, published studies were based on a limited number of heterogeneous patients, and no standardization in the interpretation of the results is currently available.

In the study by Rasche et al, 227 newly diagnosed, transplant-eligible, MM patients were prospectively and simultaneously studied at baseline with DWI whole-body MRI and FDG PET, along with fluorescence in situ hybridization and gene expression profiling (GEP). The study was aimed at identifying tumor-intrinsic features associated with PET false negativity and a DWI MRI-positive pattern. They found that the majority of the patients were positive for both imaging techniques (81%), 7% were double negative, and 11% belonged to the PET false-negative/DWI MRI-positive subgroup (see figure). None of these latter patients belonged to the GEP-defined HY or PR molecular subgroup. Most importantly, among 21 differentially expressed genes in comparison with the double-positive imaging group, the top gene was the one coding for HK2, with significantly lower expression in the PET false-negative group, along with deregulation of the other 5 genes involved in metabolism. HK2 is involved in the first step of glycolysis, necessary

for the phosphorylation of both normal glucose and FDG; a lower activity of this enzyme results in lower levels of metabolically trapped tracer in tumor cells. Therefore, a mechanistic explanation for PET false negativity was provided for the first time by this study. Unfortunately, the mechanism underlying differential HK2 expression remains elusive. Another caveat is that 15% of the patients in the PET false-negative group showed FDG avid disease at the time of relapse, a finding not yet clarified.

The use of GEP to identify those MM patients for whom PET/CT is not an appropriate tool for assessment of bone disease and/or for evaluation of metabolic response to therapy is an important step toward a more “personalized” and appropriate use of diagnostic and prognostic resources. Which should be the next steps? First of all, homogeneous and prospective comparison of DWI MRI with PET/CT, both prior and after treatment, is needed to optimize the use of imaging for prognosis and for evaluation of metabolic response to therapy. Second, PET/CT interpretation criteria were not homogeneous in different studies; similarly, no consensus exists for DWI MRI. Attempts to standardize FDG PET/CT interpretation criteria are ongoing. Regarding MRD

evaluation, it will be important to establish the relationship between complete metabolic response and MRD negativity at the BM level, as well as to define the impact of MRD assessment on treatment strategies. Upcoming prospective trials, extensively applying novel techniques evaluating MRD both inside and outside the BM, will help to address these issues and define the role of these promising tools in clinical practice.

Conflict-of-interest disclosure: The authors declare no competing financial interests. ■

REFERENCES

- Rasche L, Angtuaco E, McDonald JE, et al. Low expression of hexokinase-2 is associated with false-negative FDG-positron emission tomography in multiple myeloma. *Blood*. 2017;130(1):30-34.
- Rajkumar SV, Dimopoulos MA, Palumbo A, et al. International Myeloma Working Group updated criteria for the diagnosis of multiple myeloma. *Lancet Oncol*. 2014;15(12):e538-e548.
- Munshi NC, Avet-Loiseau H, Rawstron AC, et al. Association of minimal residual disease with superior survival outcomes in patients with multiple myeloma: a meta-analysis. *JAMA Oncol*. 2017;3(1):28-35.
- Kumar S, Paiva B, Anderson KC, et al. International Myeloma Working Group consensus criteria for response and minimal residual disease assessment in multiple myeloma. *Lancet Oncol*. 2016;17(8):e328-e346.
- Bartel TB, Haessler J, Brown TLY, et al. F18-fluorodeoxyglucose positron emission tomography in the context of other imaging techniques and prognostic factors in multiple myeloma. *Blood*. 2009;114(10):2068-2076.
- Zamagni E, Nanni C, Mancuso K, et al. PET/CT improves the definition of complete response and allows to detect otherwise unidentifiable skeletal progression in multiple myeloma. *Clin Cancer Res*. 2015;21(19):4384-4390.
- Cavo M, Terpos E, Nanni C, et al. Role of ¹⁸F-FDG PET/CT in the diagnosis and management of multiple myeloma and other plasma cell disorders: a consensus statement by the International Myeloma Working Group. *Lancet Oncol*. 2017;18(4):e206-e217.
- Lapa C, Knop S, Schreder M, et al. ¹¹C-methionine-PET in multiple myeloma: correlation with clinical parameters and bone marrow involvement. *Theranostics*. 2016;6(2):254-261.
- Cassou-Mounat T, Balogova S, Nataf V, et al. ¹⁸F-fluorocholine versus ¹⁸F-fluorodeoxyglucose for PET/CT imaging in patients with suspected relapsing or progressive multiple myeloma: a pilot study. *Eur J Nucl Med Mol Imaging*. 2016;43(11):1995-2004.
- Messiou C, Giles S, Collins DJ, et al. Assessing response of myeloma bone disease with diffusion-weighted MRI. *Br J Radiol*. 2012;85(1020):e1198-e1203.

DOI 10.1182/blood-2017-05-781278

© 2017 by The American Society of Hematology