

inside **blood** commentary

23 MARCH 2017 | VOLUME 129, NUMBER 12

● ● ● CLINICAL TRIALS AND OBSERVATIONS

Comment on Fajgenbaum et al, page 1646

Multicentric Castleman disease: consensus at last?

Jonathan Said DAVID GEFKEN SCHOOL OF MEDICINE

In this issue of *Blood*, Fajgenbaum et al propose much needed consensus criteria for the diagnosis of idiopathic multicentric Castleman disease (iMCD).¹

In collaboration with an international cohort of clinicians and pathologists who reviewed more than 240 cases, the authors concurred on a set of evidence-based criteria, thereby paving the way for

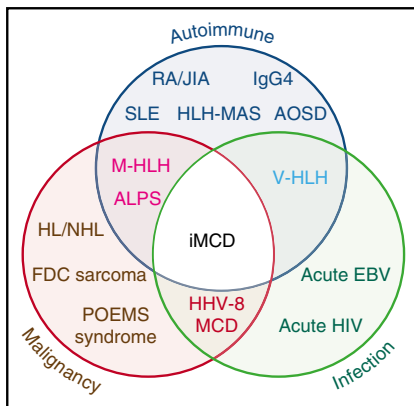
a uniform approach to managing this enigmatic condition. In 1956, Castleman et al² described clinicopathologic features of 13 asymptomatic patients who presented with a mediastinal mass. This form of unicentric CD is a distinct entity, readily diagnosed on pathologic examination and, in most cases, treated effectively by excision of the mass.

The multicentric form has been more problematic in terms of both its clinical definition and its pathology; this form has been described as plasma cell, plasmablastic, hyaline vascular, transitional, or mixed. Variants of MCD such as TAFRO syndrome (which includes a constellation of features such as thrombocytopenia, anasarca/ascites, reticulin fibrosis in bone marrow, renal dysfunction, and organomegaly) have also been reported.³ The multicentric form of CD is associated with constitutional symptoms, largely related to increased cytokines, particularly interleukin-6 (IL-6), laboratory abnormalities, multifocal lymphadenopathy and, in some cases, hepatosplenomegaly. With the identification of human herpesvirus 8 (HHV-8), it became clear that a subset of cases of MCD were caused by HHV-8, which produces a viral IL-6 similar to its human counterpart. These cases occur most commonly but not exclusively in HIV-positive individuals and can readily be

identified in paraffin sections with commercial antibodies to HHV-8 latency-associated nuclear antigen encoded by ORF73.

Unfortunately, the criteria for pathologic and clinical diagnosis of the significant number of patients with HHV-8-negative or iMCD are ill defined, and there is considerable overlap with many autoimmune, neoplastic, and infectious diseases (see figure). Pathologic features are commonly those of a nonspecific polytypic plasmacytosis admixed with variably prominent hypervascular or regressed germinal centers, with or without prominent dendritic histiocytes. For consensus, in addition to Major Criteria for the diagnosis (characteristic pathology and multicentric lymphadenopathy), at least 2 of 11 Minor Criteria with at least 1 laboratory abnormality are required. Most importantly, the article emphasizes the need to exclude infectious, neoplastic, and autoimmune diseases that mimic iMCD.

The Minor Criteria, whether clinical such as constitutional symptoms or laboratory such as elevated C-reactive protein and anemia, are nonspecific and must be applied in the context of the pathologic findings. It is expected that the list may be refined in the next phase of the study, during which the criteria will be analyzed and validated through the international registry, which the Castleman Disease Collaborative Network and University of Pennsylvania launched in 2016. Although not all may agree with the criteria proposed or their weight in reaching a diagnosis, this proposal, based on review of a large number of cases by an international panel of experts, provides a platform for more uniform consensus diagnosis. Accurate and timely diagnosis of patients with iMCD is increasingly critical now that there are effective targeted therapies, such as the chimeric anti-IL-6 antibody siltuximab.⁴



Venn diagram showing overlap between iMCD and other entities with similar clinical and pathologic presentations which must be excluded before making the diagnosis ALPS, autoimmune lymphoproliferative syndrome; AOSD, adult-onset Still disease; EBV, Epstein-Barr virus; FDC, follicular dendritic cell; HL, Hodgkin lymphoma; HLH-MAS, hemophagocytic lymphohistiocytosis-macrophage activation syndrome; IgG4, IgG4-related disease; JIA, juvenile idiopathic arthritis; M-HLH, malignancy-associated hemophagocytic lymphohistiocytosis; NHL, non-Hodgkin lymphoma; POEMS, polyneuropathy, organomegaly, endocrinopathy, monoclonal paraprotein, skin changes; RA, rheumatoid arthritis; SLE, systemic lupus erythematosus; V-HLH, viral hemophagocytic lymphohistiocytosis. See Figure 1 in the article by Fajgenbaum et al that begins on page 1646.

Downloaded from http://ashpublications.net/blood/article-pdf/129/12/1569/1399493/blood763482.pdf by guest on 05 June 2024

Conflict-of-interest disclosure: The author declares no competing financial interests. ■

REFERENCES

1. Fajgenbaum DC, Uldrick TS, Bagg A, et al. International, evidence-based consensus diagnostic criteria for HHV-8-negative/idiopathic multicentric Castlemans disease. *Blood*. 2017;129(12):1646-1657.
2. Castleman B, Iverson L, Menendez VP. Localized mediastinal lymphnode hyperplasia resembling thymoma. *Cancer*. 1956;9(4):822-830.

3. Iwaki N, Fajgenbaum DC, Nabel CS, et al. Clinicopathologic analysis of TAFRO syndrome demonstrates a distinct subtype of HHV-8-negative multicentric Castlemans disease. *Am J Hematol*. 2016;91(2):220-226.
4. van Rhee F, Wong RS, Munshi N, Rossi JF, Ke XY, Fossa A, et al. Siltuximab for multicentric Castlemans disease: a randomised, double-blind, placebo-controlled trial. *Lancet Oncol*. 2014;15(9):966-974.

DOI 10.1182/blood-2017-01-763482

© 2017 by The American Society of Hematology

CLINICAL TRIALS AND OBSERVATIONS

Comment on Yu et al, page 1658

Unraveling Castleman: progress in a complex process

Kieron Dunleavy NATIONAL CANCER INSTITUTE

In this issue of *Blood*, Yu et al report on the clinical and pathologic features, as well as the treatment outcomes of a large patient population with Castleman disease (CD), negative for HIV and human herpesvirus 8 (HHV-8).¹

CD was very first described by Benjamin Castleman more than 60 years ago.² It is a rarely encountered, poorly understood, lymphoproliferative disorder that really comprises a broad spectrum of clinicopathologic entities and has widely variable therapeutic outcomes.³ Unicentric and multicentric variants have been described. Unicentric CD (UCD) is confined to one lymph node region and is usually treated by lymph node excision; inflammatory symptoms are mild and typically abate with lymph node removal. Multicentric CD (MCD) on the other hand, is clinically aggressive and is characterized by very significant cytokine over-activity that may lead to systemic organ dysfunction and failure. A high proportion of multicentric cases are driven by HHV-8, which drives cytokine hyperactivity and may cause lymphoid proliferations and lymphoma; these cases usually occur in HIV-infected individuals.⁴ HHV-8 and HIV-negative MCD cases (the so called idiopathic MCD [iMCD]) because there is no known viral etiology) are also encountered.⁵ Interleukin-6 (IL-6) is the most commonly elevated cytokine in MCD, and although the release of cytokines is thought to be HHV-8 driven in HHV-8-positive cases, the cause of cytokine release in

iMCD is poorly understood and may result from etiologic mechanisms such as somatic mutations or other viruses.⁶ iMCD cases may in particular present a clinicopathologic diagnostic challenge and to that end, recently published international consensus diagnostic criteria are welcomed.⁷

Considering the paucity of data and prospective studies to inform on how to approach the diagnosis and treatment of patients with this complex and heterogeneous disease, this study by Yu et al is helpful, particularly with regards to iMCD. There is little consensus on how iMCD should be managed and most published experience on this is in the form of case reports or mini series. Approaches such as rituximab and chemotherapy have been somewhat useful and recently, antibodies that target the IL-6 signaling cascade, such as siltuximab, have demonstrated good efficacy but require long-term administration.⁸ Herein, the authors analyzed clinicopathologic features and therapeutic outcome in a large series of HIV/HHV-8-negative CD (UCD and iMCD). There were several interesting findings. Lymph node immunophenotyping demonstrated significant differences in T- and B-cell populations between UCD and iMCD cases, suggesting distinct pathophysiologies and likely disparate

mechanisms of cytokine deregulation. In addition, more than one-third of cases of iMCD had a history of an autoimmune disease, suggesting either a role of or strong association with autoimmunity. This raises the question of whether or not these cases occurring in a milieu of autoimmunity are biologically and pathogenetically distinct, and prognostically different from cases not associated with autoimmune disease? In this series, the authors observed a very high response rate with siltuximab, and in iMCD this was significantly more effective than rituximab and chemotherapy approaches.

CD, particularly iMCD, remains a challenge on several levels due to its rarity, heterogeneity, and thus far, poorly understood pathogenesis. Moving forward, the most expedient ways to make progress will likely come from international collaborations that focus on developing optimal shared tissue repositories and other clinicopathologic data, to better understand the biology of iMCD in order to pave the way for novel clinical trial development and ultimately improved outcomes.

Conflict-of-interest disclosure: The author declares no competing financial interests. ■

REFERENCES

1. Yu L, Tu M, Cortes J, et al. Clinical and pathological characteristics of HIV- and HHV-8-negative Castlemans disease. *Blood*. 2017;129(12):1658-1668.
2. Castleman B, Towne VW. Case records of the Massachusetts General Hospital; weekly clinicopathological exercises; founded by Richard C. Cabot. *N Engl J Med*. 1954;251(10):396-400.
3. Wang HW, Pittaluga S, Jaffe ES. Multicentric Castlemans disease: where are we now? *Semin Diagn Pathol*. 2016;33(5):294-306.
4. Dupin N, Diss TL, Kellam P, et al. HHV-8 is associated with a plasmablastic variant of Castlemans disease that is linked to HHV-8-positive plasmablastic lymphoma. *Blood*. 2000;95(4):1406-1412.
5. Fajgenbaum DC, van Rhee F, Nabel CS. HHV-8-negative, idiopathic multicentric Castlemans disease: novel insights into biology, pathogenesis, and therapy. *Blood*. 2014;123(19):2924-2933.
6. Nishimoto N, Kanakura Y, Aozasa K, et al. Humanized anti-interleukin-6 receptor antibody treatment of multicentric Castlemans disease. *Blood*. 2005;106(8):2627-2632.
7. Fajgenbaum DC, Uldrick TS, Bagg A, et al. International, evidence-based consensus diagnostic criteria for HHV-8-negative/idiopathic multicentric Castlemans disease. *Blood*. 2017;129(12):1646-1657.
8. van Rhee F, Wong RS, Munshi N, et al. Siltuximab for multicentric Castlemans disease: a randomised, double-blind, placebo-controlled trial. *Lancet Oncol*. 2014;15(9):966-974.

DOI 10.1182/blood-2017-02-764654