blood® work
IMAGES IN HEMATOLOGY

Circulating reactive plasma cells in the setting of peripheral T-cell lymphoma mimicking plasma cell leukemia

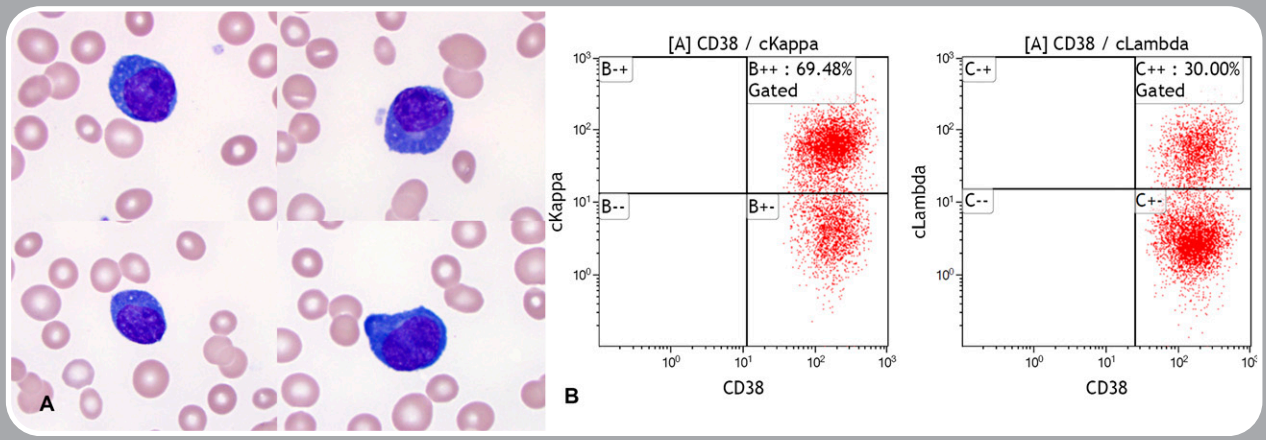

Joo Y. Song and Leslie Popplewell, City of Hope National Medical Center

A 57-year-old man presented with a history of peripheral T-cell lymphoma that was diagnosed 2 years previously and that recurred 1 year later after 6 cycles of combination therapy with cyclophosphamide, daunorubicin, vincristine, and prednisone. A complete blood count showed an elevated white blood cell count ($1.53 \times 10^3/\mu L$), normocytic anemia, and thrombocytopenia. A comprehensive metabolic panel showed an increase in total protein (9.7 g/dL) and decreased albumin level (3.3 g/dL). Serum immunoglobulin G level was elevated as well (5310 mg/dL). A peripheral blood smear was reviewed, which showed prominent rouleau formation with circulating plasma cells and plasmacytoid lymphocytes (>20% of the white blood cells). These findings were indicative of a plasma cell leukemia (panel A). However, flow cytometry analysis showed the plasma cells were positive for CD38 (bright) and CD138 and were polytypic with cytoplasmic κ and λ (ratio 2.3:1) (panel B).

Polytypic plasmacytosis in the peripheral blood has been seen in patients with sepsis, viral infections, autoimmune conditions, and, less commonly, peripheral T-cell lymphomas such as angioimmunoblastic T-cell lymphoma. The latter may be caused by increased cytokine release, such as interleukin-6. This phenomenon is uncommon but can mimic plasma cell leukemia with rouleau formation.

DOI 10.1182/blood-2015-05-648311