

Comment on Quintanilla-Martinez et al, page 3101

Cutaneous EBV-associated lymphoma?

Miguel A. Piris¹ and Carlos Barrionuevo Cornejo² ¹HOSPITAL UNIVERSITARIO MARQUES DE VALDECILLA; ²INSTITUTO NACIONAL DE ENFERMEDADES NEOPLÁSICAS

In this issue of *Blood*, Quintanilla-Martinez and colleagues describe a series of Hydroa vacciniforme-like lymphoma (HVLL) and find that this is an Epstein-Barr virus (EBV)-associated lymphoproliferative disorder with a diverse ($\alpha\beta$ -, $\gamma\delta$ -, or NK-cell) phenotype and a broad clinical spectrum, in most cases showing a prolonged clinical course, but with a distinct risk for progression to systemic disease.¹

HVLL is an uncommon lymphoproliferative disorder mainly involving children living in Latin America and East Asia. Thus, different studies from both sides of the Pacific Ocean seem to describe a common condition, characterized by a recurrent cutaneous eruption with Hydroa vacciniforme features that eventually may evolve to a systemic lymphoproliferative disorder with a high mortality.²⁻⁷ Monoclonal EBV-positive atypical T cells with cytotoxic or natural killer (NK) phenotype have been consistently found in these lesions.

Now, Quintanilla-Martinez and colleagues,¹ from Mexico and Germany, study a series of cases and propose that

HVLL is a chronic lymphoproliferative disorder that may in the initial phase respond favorably to conservative therapy using immunomodulators and/or immunosuppressive agents.

Although this is not a clinical trial, the results are consistent with other reported observations. This allows them to recommend less aggressive therapy for the initial stages of the disease.

HVLL is a fascinating disorder that teaches us about a specific model of development of a systemic lymphoproliferative disorder. Thus, the data are consistent with the interpretation that, after an initial EBV exposure, patients with a particular genetic background

develop a disorder characterized by the presence of persistent T-cell clones with a cytotoxic or NK phenotype. In response to different inflammatory stimuli, such as mosquito bites or sunburns, the patients develop local inflammatory sites that recruit the monoclonal T cells. This may evolve as a self-limited disorder that may recur after additional local insults. Additional genetic or environmental events may eventually trigger a more aggressive disorder in a fraction of these patients (see figure).

These observations give additional support to the thesis that inflammatory sites may play a role in the pathogenesis of the early steps of different lymphoproliferative disorders. Circulating monoclonal T or B cells may then populate these inflammatory sites, but this finding does not necessarily reflect tumoral progression.

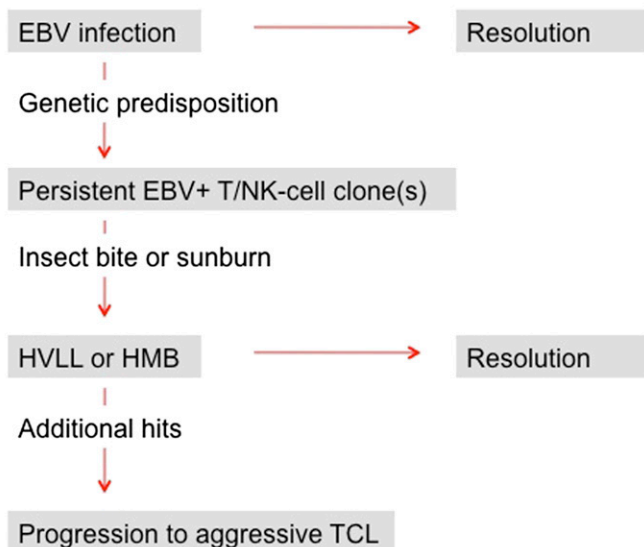
Consistently with observations and reflections performed in other areas of the pathology, the authors propose not to label these lesions as lymphoma, restricting the use of this term to the aggressive steps of the disorder requiring cytotoxic therapy.

Conflict-of-interest disclosure: The authors declare no competing financial interests. ■

REFERENCES

1. Quintanilla-Martinez L, Ridaura C, Nagl F, et al. Hydroa vacciniforme-like lymphoma: a chronic EBV+ lymphoproliferative disorder with risk to develop a systemic lymphoma. *Blood*. 2013;122(18):3101-3110.
2. Ruiz-Maldonado R, Parrilla FM, Orozco-Covarrubias ML, Ridaura C, Tamayo Sanchez L, Duran McKinster C. Edematous, scarring vasculitic panniculitis: a new multisystemic disease with malignant potential. *J Am Acad Dermatol*. 1995;32(1):37-44.
3. Rodríguez-Pinilla SM, Barrionuevo C, García J, et al. Epstein-Barr virus-positive systemic NK/T-cell lymphomas in children: report of six cases. *Histopathology*. 2011;59(6):1183-1193.
4. Kimura H, Ito Y, Kawabe S, et al. EBV-associated T/NK-cell lymphoproliferative diseases in nonimmunocompromised hosts: prospective analysis of 108 cases. *Blood*. 2012;119(3):673-686.
5. Rodríguez-Pinilla SM, Barrionuevo C, García J, et al. EBV-associated cutaneous NK/T-cell lymphoma: review of a series of 14 cases from Peru in children and young adults. *Am J Surg Pathol*. 2010;34(12):1773-1782.
6. Barrionuevo C, Anderson VM, Zevallos-Giampietri E, et al. Hydroa-like cutaneous T-cell lymphoma: a clinicopathologic and molecular genetic study of 16 pediatric cases from Peru. *Appl Immunohistochem Mol Morphol*. 2002;10(1):7-14.
7. Cohen JI, Kimura H, Nakamura S, Ko YH, Jaffe ES. Epstein-Barr virus-associated lymphoproliferative disease in non-immunocompromised hosts: a status report and summary of an international meeting, 8-9 September 2008. *Ann Oncol*. 2009;20(9):1472-1482.

Theoretical sequence of events in chronic EBV+ lymphoproliferative disorder



Sequential steps in the development of cutaneous EBV-positive lymphoproliferative disorder. HMB, hypersensitivity to mosquito bites; TCL, T-cell lymphoma.

© 2013 by The American Society of Hematology