

How I treat

How I treat adult T-cell leukemia/lymphoma

Ali Bazarbachi,¹ Felipe Suarez,² Paul Fields,³ and Olivier Hermine²

¹Department of Internal Medicine, American University of Beirut, Beirut, Lebanon; ²Centre Nationale de Recherche Scientifique Unité Mixte de Recherche 8147 and Department of Hematology, Necker Hospital, Paris Descartes University, Paris, France; and ³Department of Haematology, Guys and St Thomas Hospital, Kings Health Partners, London, United Kingdom

Adult T-cell leukemia/lymphoma (ATL) is an aggressive malignancy of mature activated T cells caused by human T-cell lymphotropic virus type I. ATL carries a bad prognosis because of intrinsic chemoresistance and severe immunosuppression. In acute ATL, Japanese trials demonstrated that although combinations of chemotherapy improved response rate, they failed to achieve a significant impact on survival. Patients with chronic and smoldering ATL have a better prognosis, but long-term survival is poor when these

patients are managed with a watchful-waiting policy or with chemotherapy. Recently, a worldwide meta-analysis revealed that the combination of zidovudine and IFN- α is highly effective in the leukemic subtypes of ATL and should be considered as standard first-line therapy in that setting. This combination has changed the natural history of the disease through achievement of significantly improved long-term survival in patients with smoldering and chronic ATL as well as a subset of patients with acute

ATL. ATL lymphoma patients still benefit from chemotherapy induction with concurrent or sequential antiretroviral therapy with zidovudine/IFN. To prevent relapse, clinical trials assessing consolidative targeted therapies such as arsenic/IFN combination or novel monoclonal antibodies are needed. Finally, allogeneic BM transplantation should be considered in suitable patients. (*Blood*. 2011;118(7): 1736-1745)

Introduction

Adult T-cell leukemia-lymphoma (ATL) is an aggressive lymphoid proliferation associated with the human lymphotropic virus type I (HTLV-I).^{1,2} ATL usually occurs in people from HTLV-I–endemic regions, such as southern Japan, the Caribbean, Central and South America, intertropical Africa, Romania, and northern Iran.³⁻⁶ HTLV-I causes transformation and clonal expansion of T cells, resulting in ATL in approximately 1%-4% of the estimated 10-20 million infected hosts, with a mean latency period of > 50 years.^{3,5,7}

Pathogenesis

The serum of patients with ATL contains antibodies to HTLV-I, and the HTLV-I provirus is clonally integrated in most of the cases in the CD4⁺ CD25⁺-activated T lymphocytes, which are the leukemic flower cells characteristic of ATL. The exact mechanism of HTLV-I–induced leukemogenesis is not fully elucidated, although HTLV-I infection appears to represent the first event of a multistep oncogenic process.⁸

Oligoclonal expansions of HTLV-I–infected T cells result from expression of the viral transactivator protein Tax, which activates the viral promoter and various cellular genes, and also creates an autocrine loop involving IL-2, IL-15, and their cognate receptors.⁹⁻¹² Tax changes many cellular pathways, including activation of cAMP response element binding protein or cAMP-dependent transcription factor, adaptor-related protein complex 1, and NF- κ B; up-regulation of antiapoptotic proteins; repression of p53, DNA polymerase β , proliferating cell nuclear antigen, and the mitotic spindle-assembly checkpoint protein MAD1; and disruption of several cell-cycle regulators, including cyclins and inhibitors of cyclin-dependent kinases.^{8,13-21}

Recent findings indicate that Tax posttranslational modifications, namely ubiquitylation and SUMOylation, are critical for the intracellular localization of Tax and for the constitutive activation of the NF- κ B pathway.²²⁻²⁵ Finally, Tax also affects the microenvironment by inducing angiogenesis and gap junctions–mediated communication between infected cells and endothelial cells, hence facilitating the extravasation and invasiveness of ATL cells^{26,27} as well as the synthesis of TGF β and inhibition of TGF β signal transduction in infected cells.²⁸

On the basis of these multiple effects, Tax was proposed to be an oncogene in ATL, but the fact that Tax protein expression is undetectable in circulating ATL cells has led to significant controversies.²⁹ Indeed, freshly isolated ATL cells express a low level of HTLV-I antigens and transcripts,³⁰⁻³² but a few hours after in vitro culture, in most cases viral mRNA and viral proteins begin to be detected. This lack of HTLV-I expression in vivo may be because of the existence of a viral reservoir outside the blood compartment or to a transient or low-level expression of the Tax protein undetectable by Western blot. Another possibility is the rapid destruction by the immune system of cells expressing HTLV-I proteins at the cell surface.

Secondary events after HTLV-I infection are probably more involved in the leukemia progression than in the leukemogenesis itself. These include multiple and nonspecific chromosomal abnormalities,³³ as well as the mutation or deletion of tumor suppressor genes, such as p53 or p15^{INK4B}/p16^{INK4A}, which are found in 30%-50% of ATL cases and associated with clinical subtypes and prognosis.³⁴ In addition, end-to-end chromosomal fusions and shortened telomeres frequently are detected in ATL cells, which might be the result of a decrease in human telomerase expression in the early stages of transformation.^{35,36}

Submitted March 30, 2011; accepted June 1, 2011. Prepublished online as *Blood* First Edition paper, June 14, 2011; DOI 10.1182/blood-2011-03-345702.

© 2011 by The American Society of Hematology

Importantly, recently authors have shown that Tax expression in the T cells of transgenic mice or in human CD34⁺ stem cells induces leukemia with striking ATL-like features,³⁷⁻³⁹ formally demonstrating that Tax initiates ATL. Whether continuous Tax expression is required for the maintenance of the transformed phenotype is still not known. Nevertheless, fresh ATL cells display exactly the same morphologic and biochemical phenotype as Tax-expressing cells. It could be hypothesized that ATL cells may display a latent, transient, and/or low level of Tax expression in preferential sites involved by tumor cells such as skin, gastrointestinal tract, and/or other lymphoid organs. This hypothesis is supported by the presence of anti-Tax cytotoxic lymphocytes in ATL patients⁴⁰ and the recent findings that leukemic cells in ATL patients are dividing outside the bloodstream (O.H. et al, unpublished observations, July 1, 2010).

Alternatively, after a set of mutations that mimic Tax activity, cells may escape the immune surveillance by deleting Tax. This subset of mutations may define the different behavior of transformed cells (eg, chronic vs acute subtype; leukemia vs lymphoma subtypes). Recently, the expression of the *HTLV-1 bZIP* factor gene (*HBZ*), an antisense mRNA transcribed from the 3' LTR, has been shown to be consistently present in ATL cells.⁴¹ Thus, *HBZ* might have a role in cellular transformation and leukemogenesis. Indeed, *HBZ* expression correlates with provirus load, and the *HBZ* gene has growth-promoting activity in vivo and in vitro, demonstrating that this gene is critical for ATL cells even at the late stage of leukemogenesis.⁴²

Clinical presentation and classification

The most recent World Health Organization lymphoma classification lists ATL as a peripheral T-cell lymphoma.⁴³ The diversity in clinical features and prognosis of patients with ATL has led to its subclassification into the following 4 subtypes according to the Shimoyama classification: smoldering, chronic and acute leukemic forms and ATL lymphoma.⁴⁴ A borderline state between healthy carriers of HTLV-I and ATL patients has been described and named pre-ATL.⁹ This phase is asymptomatic and characterized by the presence of abnormal peripheral blood lymphocytes demonstrating the morphology of ATL cells. Pre-ATL can either disappear spontaneously or progress to 1 of the 4 clinical forms of the disease.

“Aggressive ATL”: acute and lymphoma subtypes

When ATL presents aggressively, it is either caused by a leukemic presentation referred to as “acute ATL” (60% of all cases) or in patients who present with lymph node enlargement in the absence of peripheral blood involvement (< 1% of leukemic cells in the peripheral blood) and referred to as “lymphomatous” ATL (20% of all cases).⁴⁵ These 2 forms are characterized by massive lymphadenopathy, which generally spares the mediastinum, hepatosplenomegaly, lytic bone lesions, and multiple visceral lesions with skin, gastrointestinal, and lung infiltration.⁴⁵ Signs and symptoms related to hypercalcemia, such as renal dysfunction or neuropsychiatric disturbances, may be prominent among the presenting clinical features. In the acute variant, approximately 70% of patients will develop hypercalcemia at some point, and the extent of hypercalcemia is frequently severe.⁴⁶ ATL patients are functionally immunocompromised and may develop a variety of opportunistic infections, including cytomegalovirus or *Pneumocystis carinii* pneumonias, malignant strongyloidiasis, disseminated cryptococco-

sis or toxoplasmosis, disseminated fungal infections, as well as bacterial abscesses and sepsis.^{45,47,48}

Smoldering and chronic subtypes

Smoldering ATL is characterized by skin or lung infiltration without any other visceral involvement, a low number of leukemic cells (1%-5% abnormal peripheral blood lymphocytes), and a normal leukocyte count. In chronic ATL, a high leukocyte count is observed that is associated with a tumor syndrome (lymphadenopathy and hepatosplenomegaly). However, there is no associated hypercalcemia or infiltration of the CNS, gastrointestinal tract, or bones, and the lactate dehydrogenase level is normal or only slightly increased (less than twice the upper limit of normal). The chronic form is subgrouped into favorable and unfavorable, the latter is defined by low serum concentration of albumin, high level of lactate dehydrogenase, or high serum urea concentration, as well as high expression of Ki-67 antigen.^{49,50} Diagnosis of smoldering and chronic ATL is typically made after several months of follow-up without treatment.⁴⁴

Pitfalls from the Shimoyama classification

This classification has been extremely useful for the standardization and comparison of the outcome of Japanese patients with those in the other countries, although there are no prospective studies in which authors address this issue. However, 2 important pitfalls remain to be addressed. First, lymphoma subtype is defined by the presence of < 1% circulating abnormal lymphocytes, leading to the classification of patients with aggressive presentation and > 1% circulating abnormal lymphocytes as acute ATL, even when the patients have bulky lymph nodes or visceral disease. Recent findings suggest that these patients behave as if they have ATL lymphoma rather than acute ATL because they do not respond to antiviral therapy alone (see “Antiviral therapy”), which may suggest that the incidence of ATL lymphoma may be greater. Second, confusion persists whether patients with isolated circulating abnormal lymphocytes (> 5%) should be classified as smoldering ATL because recent data from the United Kingdom suggest that these patients have an excellent long-term survival,⁵¹ contrary to smoldering ATL patients with skin or lung infiltration.⁵²

Diagnostic workup

The diagnosis of ATL is determined by a combination of the characteristic clinical presentation, morphologic and immunophenotypic features of the malignant cells, along with confirmation of HTLV-I infection.⁵³ There are no pathognomonic clinical features that clearly distinguish ATL from other diseases.

Tumor cells characteristics

ATL tumor cells are detected in peripheral blood in cases of acute, chronic, or smoldering type with leukemic manifestations or from biopsy of involved organs in ATL lymphoma. An excisional-biopsy is recommended in ATL lymphoma. The histologic features of lymph nodes in ATL may be indistinguishable from those of other peripheral T-cell lymphomas.^{54,55} At least 5% of circulating abnormal T lymphocytes is required to diagnose ATL in patients without histologically proven tumor lesions.⁴⁴ These tumor cells, also termed “flower cells” or “clover leaf” and considered pathognomonic of ATL, may display 5 common morphologic subtypes:

malignant-activated lymphocytes with convoluted nuclei, condensed chromatin, small or absent nucleoli, and basophilic cytoplasm.⁴⁵

Many other cytologic variants (large cells, immunoblastic and anaplastic cells, Sézary-like cells) may also be observed. These cells express the surface T-cell lymphocytic markers CD2, CD4 and CD5, CD45RO, CD29, T-cell receptor $\alpha\beta$, and are usually negative for the CD7, CD8, and CD26 and show reduced CD3 expression. The lymphocytic activation markers HLA-DP, DQ, DR, and IL-2R α (CD25) are always present,⁴⁵ whereas terminal deoxynucleotidyl transferase is typically absent. Rare immunophenotypic variants (CD4⁻, CD8⁺, double-positive or double-negative variants) were reported.⁵⁶⁻⁵⁸ Overall, the minimal required panel for ATL diagnosis includes CD3, CD4, CD7, CD8, and CD25. No specific chromosomal abnormalities have been associated with ATL. Typically, the karyotype of ATL cells usually demonstrates multiple nonspecific abnormalities, including trisomy 3 or trisomy 7, involvement of chromosomes 6 and 14, and loss of chromosome X.³³ These karyotypic abnormalities are more common and complex in the acute and lymphoma types compared with the chronic type.

HTLV-I infection

HTLV-I serology is always positive, although some seronegative typical ATL cases have been described. Confirmation of ATL diagnosis relies on Southern blot analysis or inverse PCR, which show clonal integration of the HTLV-I provirus within tumor cells (peripheral leukemic cells or involved organ biopsies).⁵⁹ As stated previously, the differential diagnosis is sometimes difficult between smoldering ATL with no tumor syndrome and asymptomatic healthy carriers of HTLV-I. In both cases, abnormal lymphocytes (flower cells) can be observed on the blood smear, but clonal integration of HTLV-I by Southern blot can only be demonstrated in ATL.

Staging

The BM aspiration may show infiltration by lymphocytes with the same morphologic features to those in the blood; the trephine biopsy may show the same with variable degrees of involvement. Staging of ATL requires computed tomography scans of neck, chest, abdomen, and pelvis to detect nodal and extranodal lesions and potential opportunistic infections. Upper gastrointestinal tract endoscopy is frequently performed because the gastrointestinal tract is frequently involved in aggressive ATL.⁶⁰ Similarly, CNS evaluation by radiologic imaging and/or lumbar puncture should be considered in patients with aggressive ATL to detect cerebral or meningeal infiltration by ATL cells or opportunistic infection.

Response criteria

Uniform response criteria are mandatory to ensure interpretation of clinical trials, particularly because of the heterogeneous clinical presentation of ATL. Complete remission (CR) is defined as a normalization of the complete blood count associated with a disappearance of all measurable tumors. The effect has to last for at least 1 month. However, patients with a persistence of < 5% of atypical lymphocytes are considered in CR because this situation may be observed in healthy carriers of HTLV-I. Patients who achieve CR with persistence of > 5% of atypical lymphocytes are considered in very good partial response. Partial response is defined as a decrease of > 50% in the number of leukemic cells and in the size of all measurable tumors. The effect has to last for at

least 1 month. No response is defined as < 50% decrease in the number of leukemic cells or in the size of any measurable tumor or as disease progression. Patients who meet the CR or partial-response criteria but with the effect lasting < 1 month are classified as nonresponders.⁵³

Treatment options

The treatment of ATL is usually dependent on the ATL subtype. Patients with aggressive forms (acute and lymphoma) have a very poor prognosis because of intrinsic chemoresistance, a large tumor burden, hypercalcemia, and/or frequent infectious complications because of profound immune deficiency.^{2,44,61-63} In multiple Japanese trials in aggressive ATL, Japanese investigators clearly demonstrated that although combinations of chemotherapy, in particular those designed for treatment of aggressive non-Hodgkin lymphomas or acute lymphoblastic leukemia, have improved the response rates, particularly in ATL lymphoma, they failed to achieve a significant impact on long-term survival. Patients with indolent ATL (chronic or smoldering subtypes) have a better prognosis. However, recent data from Japanese showed poor long-term results when these patients are managed with a watchful-waiting policy until progression or with chemotherapy.⁵²

Conventional chemotherapy

The different clinical trials performed in Japan between 1978 and 1983 (protocols LSG1-VEPA and LSG2) demonstrated that first-generation polychemotherapy containing doxorubicin (CHOP type, ie, cyclophosphamide, hydroxydaunorubicin, oncovin (vincristine), and prednisone has little impact in ATL, especially in the acute type. Only a 16%-36% CR rate was achieved. The second-generation Japanese protocols (LSG4) consisting of alternating treatment with 3 different combinations of polychemotherapies (VEPA-B/M-FEPA/VEPP-B), obtained an important increase in the CR rate (up to 42%) compared with CHOP-like regimens. However, early relapses still occur, and 4-year overall survival still remains < 10%. The rate of CR was significantly greater in the lymphoma type than in the acute ATL, but long-term survival was identical. This poor prognosis has also been reported in studies originating from outside Japan, with resistance to or early relapse after intensive polychemotherapy.⁶⁴ However, these studies supported the notion that CR rate and disease-free survival were relatively dependent on dose intensity.

Taguchi et al⁶⁵ reported the results of intensive induction therapy supported by G-CSF in 81 ATL patients (44 acute form and 37 lymphoma type). The CR and response rates were 35.8% and 74.1%, respectively, but most patients relapsed and eventually died after a median survival of 8.5 months. In another phase 2 Japanese trial,⁵⁰ 96 previously untreated ATL patients (58 acute type, 28 lymphoma type, and 10 chronic type) received intensive multiagent chemotherapy induction supported by G-CSF. The CR rate was 35.5% and the median survival was 13 months. However, the CR rate was directly dependent on the ATL type (19.6% for the acute form, 66.7% for the lymphoma type, and 40% for chronic form) and accordingly, patients with lymphoma survived longer.⁵⁰ New-generation cytotoxic agents such as deoxycoformycin, a nucleoside analog,⁶⁶⁻⁶⁸ irinotecan hydrochloride (CPT-11), an inhibitor of topoisomerase I,⁶⁹ and MST-16, an inhibitor of topoisomerase II,⁷⁰ have also been tested in pilot phase 2 studies in refractory or relapsed ATL patients, but results have been uniformly disappointing.

More recently, a phase 3 study in Japan demonstrated that the LSG15 regimen consisting of VCAP (vincristine, cyclophosphamide, doxorubicin, prednisolone), AMP (doxorubicin, ranimustine, prednisolone), and VECP (vindesine, etoposide, carboplatin, prednisolone) is superior to biweekly CHOP in newly diagnosed acute, lymphoma, or unfavorable chronic ATL. The CR rate and 3-year overall survival were greater in the intensive arm (40% vs 25%) and (24% vs 13%), respectively, but the median survival of 13 months remains disappointing.

The poor prognosis of ATL after chemotherapy is probably the consequence of several factors. The cellular immune deficiency observed at early stages of the disease may be exacerbated by chemotherapy, leading to a high frequency of opportunistic infections. Overexpression of the multidrug resistant gene^{71,72} and p53 gene mutations^{34,73} is a feature of ATL cells and results in intrinsic resistance to chemotherapy drug.

Monoclonal antibodies

Monoclonal antibodies against IL-2 receptor have been used, particularly in patients with relapsed or refractory ATL, and the achievement of a good response is rare.^{74,75} The use of monoclonal antibody against CD52 (alemtuzumab) has demonstrated good results, but the experience is scanty and limited to case reports.^{76,77} Interestingly, some responders to alemtuzumab had mutated p53 (as observed in CLL) and were resistant to antiretroviral therapy.^{76,77} However, response duration was quite limited, and this therapy is associated with a significant risk of opportunistic infections, particularly CMV reactivation. Interestingly, cells from patients with acute ATL have greater expression of the transferrin receptor than patients with chronic forms and also elicit a better response to a monoclonal antibody (A24) directed against this receptor.^{78,79} CC chemokine receptor 4 (CCR4) is a chemokine receptor expressed on T-helper type 2 and regulatory T cells. KW-0761, a next-generation humanized anti-CCR4 mAb, was recently reported to be tolerable with potential efficacy against relapsed CCR4-positive ATL.⁸⁰ Finally, promising results were reported with siplizumab (MEDI-507 anti CD2 monoclonal antibody) in a preclinical murine model of ATL.⁸¹ Overall, monoclonal antibodies may be used as single agents in the chronic and smoldering forms, and trials are needed to define their role in combination therapies with chemotherapy in the lymphoma form or with antiretroviral therapy in the acute form.

HSC transplantation

Reported series about HSCT originate from one geographic location, that is, Japan. High-dose chemotherapy and autologous HSCT has been reported in only a few ATL patients.^{82,83} All patients relapsed or died from transplantation-related mortality, and this treatment strategy is not generally recommended.

The initial case reports on the use of allogeneic HSCT in the treatment of ATL suggested potential efficacy but revealed a high toxicity and transplantation-related mortality up to 40% in these immunocompromised patients. The authors of several retrospective studies have confirmed that allogeneic HSCT with the use of either myeloablative conditioning⁸⁴⁻⁸⁶ or reduced-intensity conditioning⁸⁷ conditioning as a promising treatment option for ATL patients. In a recent large nationwide Japanese retrospective report, investigators compared outcomes of 386 patients with ATL who underwent allogeneic HSCT.⁸⁸ After a median follow-up of 41 months, 3-year overall survival for entire cohort was 33%. Among patients who

underwent related transplantations, donor HTLV-I seropositivity adversely affected disease-associated mortality.

The number of ATL patients eligible for allogeneic transplantation is quite limited because of older age at presentation (> 60 years), the poor performance status, the severe immunosuppression, and the low rate of CR, especially in the acute form. In addition, the limited numbers of ethnic minorities donors in BM transplantation registries limit access to this procedure. In addition, the reduced functional immunologic competence in these patients needs to be borne in mind in selection for allogeneic procedures.

Antiviral therapy

An important advance in the treatment of ATL was initially reported in 2 preliminary phase 2 studies with the combination of an antiretroviral agent zidovudine (AZT) and IFN- α .⁸⁹⁻⁹¹ In these 2 studies, a high response rate was observed, particularly in patients with previously untreated acute ATL. However, lower response rates were then described in the United States when a AZT/IFN combination was used in heavily pretreated patients.⁹² However, the efficacy of this combination was confirmed in a French trial in which the authors used AZT/IFN in 19 newly diagnosed ATL patients,⁹³ and in a clinical trial in the United Kingdom in which the authors used AZT/IFN in 15 ATL patients.⁹⁴ In a recent prospective phase 2 study in the United States, 19 patients with ATL received infusional chemotherapy (EPOCH regimen, ie, etoposide-vincristine-doxorubicin-cyclophosphamide-prednisone) until maximal response, followed by antiviral therapy with daily AZT, lamivudine, and IFN.⁹⁵ However, because of disease progression, only 6 patients received antiviral therapy.⁹⁵ Finally, a retrospective analysis in Martinique revealed a significant increase in ATL survival after 1995, when antiviral therapy was introduced.⁹⁶

To assess the global impact of this innovative treatment strategy on long-term survival of ATL patients and its role in routine clinical practice, we recently performed a worldwide meta-analysis on ATL survival since 1995. In this study, we compared different treatment strategies for ATL, namely antiviral therapy alone, chemotherapy alone, and chemotherapy followed by maintenance antiviral therapy in 254 ATL patients treated in the United States, the United Kingdom, Martinique, and continental France (116 acute ATL, 18 chronic ATL, 11 smoldering ATL, and 100 ATL lymphoma). Five-year overall survival rates were 46% for 75 patients who received first-line antiviral therapy, 20% for 77 patients who received first-line chemotherapy, and 12% for 55 patients who received first-line chemotherapy followed by antiviral therapy.⁹⁷

Patients with acute, chronic, and smoldering ATL significantly benefited from first-line antiviral therapy, whereas patients with ATL lymphoma had a better outcome with chemotherapy. In acute ATL, first-line antiviral therapy alone resulted in a significant survival advantage (5-year overall survival [OS] of 28%) compared with first-line chemotherapy with or without maintenance antiviral therapy (5-year OS of 10%). Achievement of CR with antiviral therapy resulted in 82% 5-year survival. In chronic and smoldering ATL, antiviral therapy resulted in 100% 5-year survival. In ATL lymphoma, first-line antiviral therapy resulted in a significant survival disadvantage (median and 5-year OS of 7 months and 0%, respectively) compared with first-line chemotherapy with or without maintenance antiviral therapy (median and 5-year OS of 16 months and 18%, respectively).⁹⁷ Finally, a multivariate analysis confirmed that first-line antiviral therapy significantly improves overall survival of ATL patients (hazard ratio 0.47; 95% confidence

interval 0.27-0.83; $P = .021$). Published literature on antiviral therapy for ATL is summarized in Table 1.^{89,90,92-94,96-101}

Watch-and-wait policy for indolent ATL

As reported previously, patients with smoldering or chronic ATL subtypes have a better prognosis than those with aggressive variants of ATL.⁴⁴ Therefore, these 2 ATL subtypes were considered indolent and were usually managed with a watchful-waiting policy until disease progression or with chemotherapy when poor prognostic factors were identified.⁵³ However, a recent Brazilian study in which patients with ATL were followed on an expectant policy for 14 years, the reported median survival of chronic and smoldering types was only 18 months and 58 months, respectively, and the OS rates were $< 20\%$ at 5 years in both types.¹⁰² In another recent Japanese study with longer follow-up period, the authors confirmed that that indolent ATL had a poor prognosis: patients with smoldering ATL had an estimated 15-year survival rate of 12.7% with a median survival of 2.9 years, whereas patients with chronic ATL had an estimated 15-year survival rate of 14.7% with a median survival of 5.3 years.⁵² Importantly, in this study, patients who received chemotherapy had a significantly lower survival compared with patients treated on a watch-and-wait policy.⁵²

Arsenic trioxide

We have demonstrated that arsenic trioxide synergizes with IFN to induce cell-cycle arrest and apoptosis in HTLV-I-infected and freshly isolated leukemia cells from ATL patients¹⁰³ through rapid shut-off of the NF- κ B pathway and a delayed shut-off of cell-cycle-associated genes, secondary to Tax degradation by the proteasome.¹⁰⁴⁻¹⁰⁶ In a phase 2 trial of arsenic/IFN combination in 7 patients with relapsed/refractory ATL,⁹⁸ authors demonstrated 1 complete remission and 3 partial remissions, and 1 patient is still alive and disease free at 7 years⁹⁸ (O.H., unpublished observations, July 1, 2010). In a recent prospective phase 2 study, we investigated the efficacy and safety of the combination of arsenic, IFN, and AZT in 10 newly diagnosed chronic ATL patients.⁹⁹ An impressive 100% response rate was observed, including 7 CR, 2 CR but with $> 5\%$ circulating atypical lymphocytes, and 1 partial response. Side effects were moderate and mostly hematologic. Finally, we recently demonstrated that arsenic and IFN cooperate to cure murine ATL derived from *Tax* transgenics¹⁰⁷ through selective eradication of leukemia-initiating cell (LIC) activity. This finding strongly suggests that LIC activity is dependent on continuous Tax oncogene expression. Hence, the addition of arsenic to AZT/IFN, through elimination of LIC activity, may result in long-term disease eradication and potential cure. In that sense, although patients treated with arsenic/IFN/AZT combination received a suboptimal 5-days-per-week treatment, 3 of 6 patients remained in continuous complete remission for 7-18 months after discontinuation of maintenance therapy, whereas 5 patients with chronic ATL previously treated with IFN/AZT alone all relapsed, on average before 5 months.¹⁰⁷ Similarly, in an ongoing trial of ATL lymphoma patients, ie, maintenance therapy with arsenic/IFN after complete remission with chemotherapy, resulted in all assessable patients remaining in complete remission for 23-44 months, a distinctly uncommon finding in these diseases (F.S., unpublished data, March 2011). Although preliminary, these observations nevertheless suggest that also in ATL patients arsenic/IFN efficiently targets ATL LIC activity and may be useful as a consolidation therapy for those patients achieving a satisfactory response to induction therapy.

How I treat ATL

Chronic and smoldering ATL

Although patients with chronic and smoldering ATL have a better prognosis compared with patients with acute ATL and ATL lymphoma, long-term survival is dismal when these patients are managed with a watchful-waiting policy until their disease progresses.⁵² Moreover, patients who received chemotherapy alone had even a poorer outcome, indicating that this may be detrimental in these subtypes. So far, no clear prognostic factors have been able to define those in the chronic/smoldering group at high risk of transformation to the aggressive forms of the disease and who would benefit from more aggressive or alternative treatment strategies earlier.

Therefore, all patients with chronic and smoldering ATL should be treated, but not with chemotherapy. In the recent worldwide meta-analysis on ATL survival since 1995, patients with chronic/smoldering ATL who received first-line antiviral therapy only had an excellent survival (100% OS beyond 5 years). Thus, outside the context of clinical trials, the current standard therapy of chronic and smoldering ATL is combination therapy with AZT and IFN (Figure 1). However, this requires continuous therapy because relapse always occurs when treatment is stopped. The recommended starting dose is AZT 900 mg/d (in 3 divided doses) and IFN- α (5-6 million IU/m²/d). Usually, after 1 month, AZT dose can be titrated down to 600 mg/d in 2 divided doses, and the IFN dose can be reduced to 3-5 million IU/d or alternatively 1.5 μ g/kg of pegylated IFN weekly. The addition of other antiretroviral agents, such as 3TC (lamivudine) or zalcitabine, has been tested by several centers. However, no clinical evidence of added benefit was demonstrated. On the basis of the preclinical data,^{103,104,106,107} investigators from clinical trials are testing the effect of adding arsenic to the AZT/IFN combination as a consolidation therapy with the aim of then stopping therapy and achieving cure by potential elimination of leukemia-initiating cells.

ATL lymphoma

First-line antiviral therapy is less effective than first-line chemotherapy in ATL lymphoma.⁹⁷ Thus, chemotherapy should be the preferred option for patients with ATL lymphoma. However, recent unpublished results from the United Kingdom report that the combination of antiviral therapy with CHOP chemotherapy is superior to CHOP alone in patients with ATL lymphoma, suggesting that the combination of chemotherapy and AZT/IFN should be the preferred front-line therapy in ATL lymphoma patients.¹⁰⁸

On the basis of Japanese studies, state-of-the-art chemotherapy for ATL lymphoma (Figure 1) seems to be the LSG15 protocol if patients have adequate accessibility to a clinic for weekly intravenous chemotherapy for 6-8 months supported by daily G-CSF.⁵⁰ When treated with this LSG15 protocol, ATL lymphoma patients achieved a better CR rate (66.7%) than acute type (19.6%) or chronic type (40.0%) patients.⁵⁰ It does appear that dose intensification effect does exist as increased overall response rates are observed in ATL lymphoma patients, although the effect on long-term survival is less encouraging. However, this observation of increased response rate is important because other ways of achieving this, such as the addition of AZT/IFN or other novel therapies to chemotherapy, also may achieve this and provide an adequate initial disease response for subsequent consolidative treatment approaches.

Table 1. Studies using antiviral therapy in treating ATL

| Country of origin | Therapy | No. of patients | ATL subtype | Disease status | Response to antiviral therapy | Survival | Reference |
|---------------------------|---|-----------------|---|--|---|---|--------------------------------------|
| United Kingdom | IFN- α zidovudine | 19 | Acute: 17 Lymph: 2 | All had disseminated disease; 7 refractory or relapsed after chemo | 11 had major/partial response; 8 had minor/no response | Median survival: 3 mo | Gill et al, 1995 ⁸⁹ |
| France | IFN- α zidovudine | 5 | Acute: 4 Smold: 1 | Newly diagnosed | 2 had CR, 2 had 75% response, 1 had 50% response | Median survival: 10 mo | Hermine et al, 1995 ⁹⁰ |
| United Kingdom | CHOP, IFN- α zidovudine | 15 | Acute: 4 Lymph: 2 Smold: 2 | 4 PD, 8 PR/CR, 3 untreated with active disease | 67% PR; 26% NR | Median survival: 18 mo; 8 died 3-41 mon from diagnosis | Matutes et al, 2001 ⁹⁴ |
| United States | IFN- α zidovudine | 18 | Acute: 11 Chronic: 2 Lymph: 5 | 3 previously untreated; 15 relapsed or refractory | 1 CR, 2 PR, 5 SD, 4 PD, 6 NE | Median survival: 6 mo | White et al, 2001 ⁹² |
| France | \pm CHOP, IFN- α zidovudine | 19 | Acute: 15 Lymph: 4 | 13 newly diagnosed; 6 had previous chemotherapy | 47% CR, 21% PR, 21% NR, 11% NE | Median survival: 11 mo | Hermine et al, 2002 ⁹³ |
| French West Indies | CHOP, \pm IFN- α , zidovudine \pm dC + oral etoposide | 29 | Acute: 16 Chronic: 3 Lymph: 10 | Newly diagnosed | | Median survival: 8 mo (3 mo for CHOP vs 17 mo for CHOP + antiviral therapy) | Besson et al, 2002 ⁹⁵ |
| Iran | IFN- α zidovudine | 9 | Acute: 3 Chronic: 4 Lymph: 2 | 8 previously untreated; 1 in relapse | 4 CR, 3 PR, 2 PD | Median follow-up: 12 mo | Kchour et al, 2007 ¹⁰¹ |
| United States + Caribbean | IFN- α + zidovudine | 28 | Acute: 15 Chronic: 3 Lymph: 4 | 21 previously untreated | 22 evaluable (5 CR, 4 PR, 13 NR) | Median follow-up: 5.3 mo | Ramos et al, 2007 ¹⁰⁰ |
| United States | EPOCH followed by IFN- α + zidovudine | 6 | All acute | Post-EPOCH: 1 in CR, 5 in PR | 4 PD, 2 NE | | Ratner et al, 2009 ⁹⁵ |
| Iran | Arsenic trioxide, IFN- α + zidovudine | 10 | All chronic | Newly diagnosed | 7 CR, 2 VGPR, 1 PR | Median follow-up: 8 mo | Kchour et al, 2009 ⁹⁹ |
| Worldwide meta-analysis | First group: First-line antiviral therapy only (IFN- α + zidovudine); 2nd group: chemotherapy (CHOP) \pm antiviral therapy | 129 | Acute: 73 Chronic/smold: 19 Lymph: 37 | Newly diagnosed | First-line antiviral therapy only: 35% CR, 31% PR, 34% NR | First group: 5-year OS of 46%; second group: 5-year OS of 12%. | Bazarbachi et al, 2010 ⁹⁷ |

CHOP indicates cyclophosphamide, hydroxydaunorubicin, oncovin (vincristine), and prednisone; CR indicates complete response; dC, zalcitabine; EPOCH, etoposide-vincristine-doxorubicin-cyclophosphamide-prednisone; lymph, ATL lymphoma; NE, not evaluated; NR, no response; PD, progressive disease; smold, smoldering; and VGPR, very good partial response.

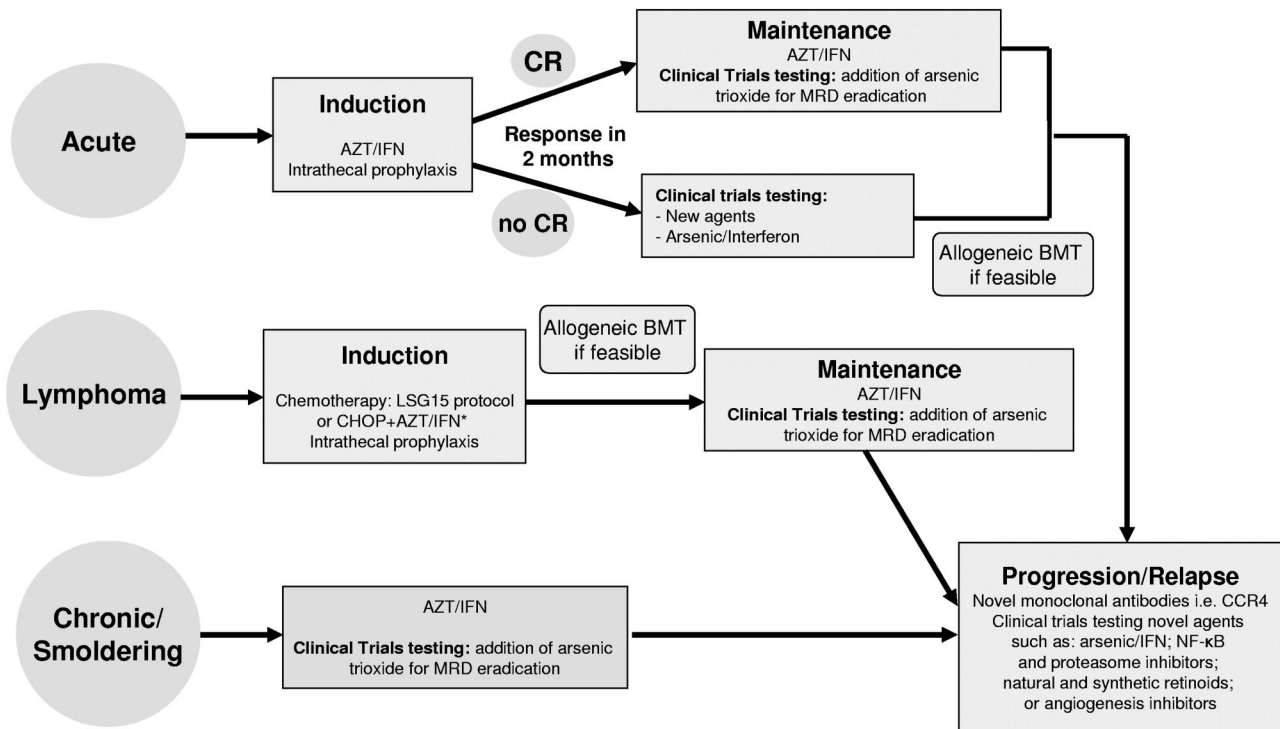


Figure 1. Recommended treatment strategy for patients with acute, lymphoma, or chronic/smoldering ATL. MRD indicates minimal residual disease. Unpublished preliminary results.

After recent encouraging results mainly from Japan, allogeneic HSCT is recommended for young patients with ATL lymphoma and matched donor. Finally, on the basis of preclinical data,^{103,104,106,107} ongoing clinical trials are testing the efficacy of 2 cycles of arsenic/IFN maintenance as a consolidation procedure after achievement of CR with encouraging preliminary results (F.S., O.H., unpublished data, March 2011).

Acute ATL

Combination chemotherapy regimens have little effect in acute ATL.^{2,61-63,109} Even with the most promising regimen (LSG-15), on which acute ATL patients survived 10.9 months, it is difficult to judge whether this approach should be adopted, when it is known that renal dysfunction was an exclusion criterion and no patients with severe hypercalcemia were included.⁵⁰ Monoclonal antibodies, which might be useful as single agents in the chronic and smoldering forms of ATL, are still untested clinically in the acute form and have yet to be tested in combination therapy treatment strategies ie combined with chemotherapy.

In the recently published meta-analysis on antiviral therapy for ATL, the treatment of acute ATL patients with AZT and IFN resulted in greater response rates and significantly prolonged survival.⁹⁷ Thus, outside the context of clinical trials, the current standard therapy of acute ATL is combination therapy with AZT and IFN (Figure 1), but it should be noted that only achievement of a CR is associated with a long-term response. It would be helpful to predict which patients in the acute setting will benefit from this approach. Preliminary results indicate that patients with wild-type *p53* are the patients who do.¹¹⁰ We therefore recommend testing for this while treatment is initiated. However, long-term disease control requires continuous therapy because relapse is always noted when treatment is stopped. The recommended starting dose is AZT 900 mg/d (in 3 divided doses) and IFN- α (5-6 million

IU/m²/d). Usually, after 1 or 2 months, AZT dose can be reduced to 600 mg/d in 2 divided doses, and IFN dose can be reduced to 3-5 million IU/d.

However, despite a significant survival advantage of the AZT/IFN combination, most patients with acute ATL eventually relapse and die. In patients who do not achieve CR, salvage chemotherapy is not effective, and hence, additional novel targeted therapies are warranted. Identification of predictive factors for CR and prolonged survival with first-line antiviral therapy is therefore critical to optimize the use of this treatment modality. Preliminary data indicate that patients with *p53* mutation¹¹⁰ and/or *IRF4* overexpression¹⁰⁰ have a lower response rate to AZT/IFN. These findings need confirmation in larger studies. After recent encouraging results, allogeneic HSCT is recommended for young patients with acute ATL and matched donor. Finally, on the basis of preclinical data,^{103,104,106,107} ongoing clinical trials are testing the efficacy of arsenic/IFN maintenance after the achievement of CR with encouraging preliminary results (F.S., O.H., unpublished data, March 2011).

Supportive therapy in ATL

Hypercalcemia associated with aggressive ATL should be managed with treatment of the disease, hydration, and bisphosphonate therapy. Trimethoprim-sulfamethoxazole, valacyclovir, and antifungal agents are recommended for the prophylaxis of *Pneumocystis jiroveci* pneumonia, viral, and fungal infections, respectively, in the Japanese trials.¹¹¹ Prophylaxis with anti-*Strongyloides* agents, such as ivermectin or albendazole, should be considered to avoid systemic infection in patients with a history of past and/or present exposure to the parasite. Intrathecal prophylaxis should be considered for patients with aggressive ATL, even in the absence of clinical symptoms because more than half of relapses at new site after chemotherapy are in the central nervous system.

32. Gessain A, Louie A, Gout O, Gallo RC, Franchini G. Human T-cell leukemia-lymphoma virus type I (HTLV-I) expression in fresh peripheral blood mononuclear cells from patients with tropical spastic paraparesis/HTLV-I-associated myelopathy. *J Virol*. 1991;65(3):1628-1633.
33. Maruyama K, Fukushima T, Kawamura K, Mochizuki S. Chromosome and gene rearrangements in immortalized human lymphocytes infected with human T-lymphotropic virus type I. *Cancer Res*. 1990;50(suppl 17):5697S-5702S.
34. Sakashita A, Hattori T, Miller CW, et al. Mutations of the p53 gene in adult T-cell leukemia. *Blood*. 1992;79(2):477-480.
35. Gabet AS, Mortreux F, Charneau P, et al. Inactivation of hTERT transcription by Tax. *Oncogene*. 2003;22(24):3734-3741.
36. Bellon M, Datta A, Brown M, et al. Increased expression of telomere length regulating factors TRF1, TRF2 and TIN2 in patients with adult T-cell leukemia. *Int J Cancer*. 2006;119(9):2090-2097.
37. Hasegawa H, Sawa H, Lewis MJ, et al. Thymus-derived leukemia-lymphoma in mice transgenic for the Tax gene of human T-lymphotropic virus type I. *Nat Med*. 2006;12(4):466-472.
38. Portis T, Harding JC, Ratner L. The contribution of NF-kappa B activity to spontaneous proliferation and resistance to apoptosis in human T-cell leukemia virus type 1 Tax-induced tumors. *Blood*. 2001;98(4):1200-1208.
39. Banerjee P, Rochford R, Antel J, et al. Proinflammatory cytokine gene induction by human T-cell leukemia virus type 1 (HTLV-1) and HTLV-2 Tax in primary human glial cells. *J Virol*. 2007;81(4):1690-1700.
40. Arnulf B, Thorel M, Poirot Y, et al. Loss of the *ex vivo* but not the reinducible CD8⁺ T-cell response to Tax in human T-cell leukemia virus type 1-infected patients with adult T-cell leukemia/lymphoma. *Leukemia*. 2004;18(1):126-132.
41. Satou Y, Yasunaga J, Yoshida M, Matsuoka M. HTLV-1 basic leucine zipper factor gene mRNA supports proliferation of adult T cell leukemia cells. *Proc Natl Acad Sci U S A*. 2006;103(3):720-725.
42. Matsuoka M, Green PL. The HBZ gene, a key player in HTLV-1 pathogenesis. *Retrovirology*. 2009;6:71.
43. Swerdlow SH, Campo E, Harris NL, et al. *World Health Organization Classification of Tumours of Haematopoietic and Lymphoid Tissues*. Lyon: IARC Press; 2008.
44. Shimoyama M. Diagnostic criteria and classification of clinical subtypes of adult T-cell leukaemia-lymphoma. A report from the Lymphoma Study Group (1984-87). *Br J Haematol*. 1991;79(3):428-437.
45. Takatsuki F, Yamaguchi K, Hattori T. Adult T-cell leukemia/lymphoma. In: Gallo RC, Wong-Staal F, eds. *Retrovirus Biology and Human Disease*. New York: Marcel Dekker; 1990:147-159.
46. Kiyokawa T, Yamaguchi K, Takeya M, et al. Hypercalcemia and osteoclast proliferation in adult T-cell leukemia. *Cancer*. 1987;59(6):1187-1191.
47. Bunn PA Jr, Schechter GP, Jaffe E, et al. Clinical course of retrovirus-associated adult T-cell lymphoma in the United States. *N Engl J Med*. 1983;309(5):257-264.
48. Verdonck K, Gonzalez E, Van Dooren S, Vandamme AM, Vanham G, Gotuzzo E. Human T-lymphotropic virus 1: recent knowledge about an ancient infection. *Lancet Infect Dis*. 2007;7(4):266-281.
49. Shirono K, Hattori T, Takatsuki K. A new classification of clinical stages of adult T-cell leukemia based on prognosis of the disease. *Leukemia*. 1994;8(11):1834-1837.
50. Yamada Y, Tomonaga M, Fukuda H, et al. A new G-CSF-supported combination chemotherapy, LSG15, for adult T-cell leukaemia-lymphoma: Japan Clinical Oncology Group Study 9303. *Br J Haematol*. 2001;113(2):375-382.
51. Hodson A, Bain B, Fields P, Talyor G. Smouldering adult T-cell leukaemia/lymphoma (ATLL) Is not associated with an increased risk of aggressive ATLL in HTLV-1 positive patients. Presented at the 52nd Annual Meeting of the American Society of Hematology; December 4-7, 2010; Orlando, FL.
52. Takasaki Y, Iwanaga M, Imaizumi Y, et al. Long-term study of indolent adult T-cell leukemia-lymphoma. *Blood*. 2010;115(22):4337-4343.
53. Tsukasaki K, Hermine O, Bazarbachi A, et al. Definition, prognostic factors, treatment, and response criteria of adult T-cell leukemia-lymphoma: a proposal from an international consensus meeting. *J Clin Oncol*. 2009;27(3):453-459.
54. Lennert K, Kikuchi M, Sato E, et al. HTLV-positive and -negative T-cell lymphomas. Morphological and immunohistochemical differences between European and HTLV-positive Japanese T-cell lymphomas. *Int J Cancer*. 1985;35(1):65-72.
55. Ohshima K, Suzumiya J, Sato K, et al. Nodal T-cell lymphoma in an HTLV-I endemic area: proviral HTLV-I DNA, histological classification and clinical evaluation. *Br J Haematol*. 1998;101(4):703-711.
56. Amagasaki T, Tomonaga Y, Yamada Y, et al. Adult T-cell leukemia with an unusual phenotype, Leu-2a positive and Leu-3a negative. *Blut*. 1985;50(4):209-211.
57. Takemoto S, Matsuoka M, Yamaguchi K, Takatsuki K. A novel diagnostic method of adult T-cell leukemia: monoclonal integration of human T-cell lymphotropic virus type I provirus DNA detected by inverse polymerase chain reaction. *Blood*. 1994;84(9):3080-3085.
58. Lorand-Metze I, Pombo-de-Oliveira MS. Adult T-cell leukemia (ATL) with an unusual immunophenotype and a high cellular proliferation rate. *Leuk Lymphoma*. 1996;22(5-6):523-526.
59. Tsukasaki K, Tsushima H, Yamamura M, et al. Integration patterns of HTLV-I provirus in relation to the clinical course of ATL: frequent clonal change at crisis from indolent disease. *Blood*. 1997;89(3):948-956.
60. Utsunomiya A, Hanada S, Terada A, et al. Adult T-cell leukemia with leukemia cell infiltration into the gastrointestinal tract. *Cancer*. 1988;61(4):824-828.
61. Hermine O, Wattel E, Gessain A, Bazarbachi A. Adult T cell leukaemia: a review of established and new treatments. *BioDrugs*. 1998;10(6):447-462.
62. Bazarbachi A, Hermine O. Treatment of adult T-cell leukaemia/lymphoma: current strategy and future perspectives. *Virus Res*. 2001;78(1-2):79-92.
63. Tobinai K. Current management of adult T-cell leukemia/lymphoma. *Oncology (Williston Park)*. 2009;23(14):1250-1256.
64. Rio B, Louvet C, Gessain A, et al. Adult T-cell leukemia and non-malignant adenopathies associated with HTLV I virus. Apropos of 17 patients born in the Caribbean region and Africa [in French]. *Presse Med*. 1990;19(16):746-751.
65. Taguchi H, Kinoshita KI, Takatsuki K, et al. An intensive chemotherapy of adult T-cell leukemia/lymphoma: CHOP followed by etoposide, vindesine, ranimustine, and mitoxantrone with granulocyte colony-stimulating factor support. *J Acquir Immune Defic Syndr Hum Retrovirol*. 1996;12(2):182-186.
66. Dearden C, Matutes E, Catovsky D. Deoxycoformycin in the treatment of mature T-cell leukaemias. *Br J Cancer*. 1991;64(5):903-906.
67. Tobinai K, Shimoyama M, Inoue S, et al. Phase I study of YK-176 (2'-deoxycoformycin) in patients with adult T-cell leukemia-lymphoma. The DCF Study Group. *Jpn J Clin Oncol*. 1992;22(3):164-171.
68. Tsukasaki K, Tobinai K, Shimoyama M, et al. Deoxycoformycin-containing combination chemotherapy for adult T-cell leukemia-lymphoma: Japan Clinical Oncology Group Study (JCOG9109). *Int J Hematol*. 2003;77(2):164-170.
69. Tsuda H, Takatsuki K, Ohno R, et al. Treatment of adult T-cell leukaemia-lymphoma with irinotecan hydrochloride (CPT-11). CPT-11 Study Group on Hematological Malignancy. *Br J Cancer*. 1994;70(4):771-774.
70. Tanabe K, Ikegami Y, Ishida R, Andoh T. Inhibition of topoisomerase II by antitumor agents bis(2,6-dioxopiperazine) derivatives. *Cancer Res*. 1991;51(18):4903-4908.
71. Kuwazuru Y, Hanada S, Furukawa T, et al. Expression of P-glycoprotein in adult T-cell leukemia cells. *Blood*. 1990;76(10):2065-2071.
72. Lau A, Nightingale S, Taylor GP, Gant TW, Cann AJ. Enhanced MDR1 gene expression in human T-cell leukemia virus-I-infected patients offers new prospects for therapy. *Blood*. 1998;91(7):2467-2474.
73. Gartenhaus RB, Wang P, Hoffmann P. Induction of the WAF1/CIP1 protein and apoptosis in human T-cell lymphoma virus type I-transformed lymphocytes after treatment with adriamycin by using a p53-independent pathway. *Proc Natl Acad Sci U S A*. 1996;93(1):265-268.
74. Waldmann TA, White JD, Goldman CK, et al. The interleukin-2 receptor: a target for monoclonal antibody treatment of human T-cell lymphotropic virus I-induced adult T-cell leukemia. *Blood*. 1993;82(6):1701-1712.
75. Waldmann TA, White JD, Carrasquillo JA, et al. Radioimmunotherapy of interleukin-2R alpha-expressing adult T-cell leukemia with Yttrium-90-labeled anti-Tac. *Blood*. 1995;86(11):4063-4075.
76. Ravandi F, Faderl S. Complete response in a patient with adult T-cell leukemia (ATL) treated with combination of alemtuzumab and pentostatin. *Leuk Res*. 2006;30(1):103-105.
77. Mone A, Puhalla S, Whitman S, et al. Durable hematologic complete response and suppression of HTLV-1 viral load following alemtuzumab in zidovudine/IFN- α -refractory adult T-cell leukemia. *Blood*. 2005;106(10):3380-3382.
78. Moura IC, Lepelletier Y, Arnulf B, et al. A neutralizing monoclonal antibody (mAb A24) directed against the transferrin receptor induces apoptosis of tumor T lymphocytes from ATL patients. *Blood*. 2004;103(5):1838-1845.
79. Callens C, Moura IC, Lepelletier Y, et al. Recent advances in adult T-cell leukemia therapy: focus on a new anti-transferrin receptor monoclonal antibody. *Leukemia*. 2008;22(1):42-48.
80. Yamamoto K, Utsunomiya A, Tobinai K, et al. Phase I study of KW-0761, a defucosylated humanized anti-CCR4 antibody, in relapsed patients with adult T-cell leukemia-lymphoma and peripheral T-cell lymphoma. *J Clin Oncol*. 2010;28(9):1591-1598.
81. Zhang Z, Zhang M, Ravetch JV, Goldman C, Waldmann TA. Effective therapy for a murine model of adult T-cell leukemia with the humanized anti-CD2 monoclonal antibody, MEDI-507. *Blood*. 2003;102(1):284-288.
82. Tsukasaki K, Maeda T, Arimura K, et al. Poor outcome of autologous stem cell transplantation for adult T cell leukemia/lymphoma: a case report and review of the literature. *Bone Marrow Transplant*. 1999;23(1):87-89.
83. Phillips AA, William RD, Savage DG, et al. A multi-institutional experience of autologous stem cell transplantation in North American patients with human T-cell lymphotropic virus type-1 adult T-cell leukemia/lymphoma suggests ineffective salvage of relapsed patients. *Leuk Lymphoma*. 2009;50(6):1039-1042.
84. Utsunomiya A, Miyazaki Y, Takatsuka Y, et al. Improved outcome of adult T cell leukemia/lymphoma with allogeneic hematopoietic stem

- cell transplantation. *Bone Marrow Transplant.* 2001;27(1):15-20.
85. Kami M, Hamaki T, Miyakoshi S, et al. Allogeneic haematopoietic stem cell transplantation for the treatment of adult T-cell leukaemia/lymphoma. *Br J Haematol.* 2003;120(2):304-309.
 86. Fukushima T, Miyazaki Y, Honda S, et al. Allogeneic hematopoietic stem cell transplantation provides sustained long-term survival for patients with adult T-cell leukemia/lymphoma. *Leukemia.* 2005;19(5):829-834.
 87. Okamura J, Utsunomiya A, Tanosaki R, et al. Allogeneic stem-cell transplantation with reduced conditioning intensity as a novel immunotherapy and antiviral therapy for adult T-cell leukemia/lymphoma. *Blood.* 2005;105(10):4143-4145.
 88. Hishizawa M, Kanda J, Utsunomiya A, et al. Transplantation of allogeneic hematopoietic stem cells for adult T-cell leukemia: a nationwide retrospective study. *Blood.* 2010;116(8):1369-1376.
 89. Gill PS, Harrington W Jr, Kaplan MH, et al. Treatment of adult T-cell leukemia-lymphoma with a combination of interferon alfa and zidovudine. *N Engl J Med.* 1995;332(26):1744-1748.
 90. Hermine O, Bouscary D, Gessain A, et al. Brief report: treatment of adult T-cell leukemia-lymphoma with zidovudine and interferon alfa. *N Engl J Med.* 1995;332(26):1749-1751.
 91. Bazarbachi A, Hermine O. Treatment with a combination of zidovudine and alpha-interferon in naive and pretreated adult T-cell leukemia/lymphoma patients. *J Acquir Immune Defic Syndr Hum Retrovirol.* 1996;(13 suppl 1):S186-190.
 92. White JD, Wharfe G, Stewart DM, et al. The combination of zidovudine and interferon alpha-2B in the treatment of adult T-cell leukemia/lymphoma. *Leuk Lymphoma.* 2001;40(3-4):287-294.
 93. Hermine O, Allard I, Levy V, Arnulf B, Gessain A, Bazarbachi A. A prospective phase II clinical trial with the use of zidovudine and interferon-alpha in the acute and lymphoma forms of adult T-cell leukemia/lymphoma. *Hematol J.* 2002;3(6):276-282.
 94. Matutes E, Taylor GP, Cavenagh J, et al. Interferon alpha and zidovudine therapy in adult T-cell leukaemia lymphoma: response and outcome in 15 patients. *Br J Haematol.* 2001;113(3):779-784.
 95. Rather L, Harrington W, Feng X, et al. Human T cell leukemia virus reactivation with progression of adult T-cell leukemia-lymphoma. *PLoS ONE.* 2009;4(2):e4420.
 96. Besson C, Panelatti G, Delaunay C, et al. Treatment of adult T-cell leukemia-lymphoma by CHOP followed by therapy with antinucleosides, alpha interferon and oral etoposide. *Leuk Lymphoma.* 2002;43(12):2275-2279.
 97. Bazarbachi A, Plumelle Y, Carlos Ramos J, et al. Meta-analysis on the use of zidovudine and interferon-alfa in adult T-cell leukemia/lymphoma showing improved survival in the leukemic subtypes. *J Clin Oncol.* 2010;28(27):4177-4183.
 98. Hermine O, Dombret H, Poupon J, et al. Phase II trial of arsenic trioxide and alpha interferon in patients with relapsed/refractory adult T-cell leukemia/lymphoma. *Hematol J.* 2004;5(2):130-134.
 99. Kchour G, Tarhini M, Kooshyar MM, et al. Phase 2 study of the efficacy and safety of the combination of arsenic trioxide, interferon alpha, and zidovudine in newly diagnosed chronic adult T-cell leukemia/lymphoma (ATL). *Blood.* 2009;113(26):6528-6532.
 100. Ramos JC, Ruiz P Jr, Ratner L, et al. IRF-4 and c-Rel expression in antiviral-resistant adult T-cell leukemia/lymphoma. *Blood.* 2007;109(7):3060-3068.
 101. Kchour G, Makhoul NJ, Mahmoudi M, et al. Zidovudine and interferon-alpha treatment induces a high response rate and reduces HTLV-1 proviral load and VEGF plasma levels in patients with adult T-cell leukemia from North East Iran. *Leuk Lymphoma.* 2007;48(2):330-336.
 102. Bittencourt AL, da Gracas Vieira M, Brites CR, Farre L, Barbosa HS. Adult T-cell leukemia/lymphoma in Bahia, Brazil: analysis of prognostic factors in a group of 70 patients. *Am J Clin Pathol.* 2007;128(5):875-882.
 103. Bazarbachi A, El-Sabban ME, Nasr R, et al. Arsenic trioxide and interferon-alpha synergize to induce cell cycle arrest and apoptosis in human T-cell lymphotropic virus type I-transformed cells. *Blood.* 1999;93(1):278-283.
 104. El-Sabban ME, Nasr R, Dbaibo G, et al. Arsenic-interferon-alpha-triggered apoptosis in HTLV-I-transformed cells is associated with tax down-regulation and reversal of NF-kappa B activation. *Blood.* 2000;96(8):2849-2855.
 105. Mahieux R, Pise-Masison C, Gessain A, et al. Arsenic trioxide induces apoptosis in human T-cell leukemia virus type 1- and type 2-infected cells by a caspase-3-dependent mechanism involving Bcl-2 cleavage. *Blood.* 2001;98(13):3762-3769.
 106. Nasr R, Rosenwald A, El-Sabban ME, et al. Arsenic/interferon specifically reverses 2 distinct gene networks critical for the survival of HTLV-1-infected leukemic cells. *Blood.* 2003;101(11):4576-4582.
 107. El Hajj H, El-Sabban M, Hasegawa H, et al. Therapy-induced selective loss of leukemia-initiating activity in murine adult T cell leukemia. *J Exp Med.* 2010;207(13):2785-2792.
 108. Hodson A, Montoto S, Mir N, et al. Addition of anti-viral therapy to chemotherapy improves overall survival in acute and lymphomatous adult t-cell leukemia/lymphoma (ATLL). American Society of Hematology. Florida, USA; 2010.
 109. Shimoyama M. Treatment of patients with adult T-cell leukemia/lymphoma: an overview. In: Takatsuki K, Hinuma Y, Yoshida M, eds. *Advances in Adult T-Cell Leukemia and HTLV-I Research.* Vol. 39. Tokyo: Japan Scientific Societies Press; 1992;43-56.
 110. Datta A, Bellon M, Sinha-Datta U, et al. Persistent inhibition of telomerase reprograms adult T-cell leukemia to p53-dependent senescence. *Blood.* 2006;108(3):1021-1029.
 111. Tsukasaki K, Utsunomiya A, Fukuda H, et al. VCAP-AMP-VECP compared with biweekly CHOP for adult T-cell leukemia-lymphoma: Japan Clinical Oncology Group Study JCOG9801. *J Clin Oncol.* 2007;25(34):5458-5464.