

## How I treat

# How I treat patients with advanced systemic mastocytosis

Peter Valent,<sup>1</sup> Wolfgang R. Sperr,<sup>1</sup> and Cem Akin<sup>2</sup>

<sup>1</sup>Department of Internal Medicine I, Division of Hematology and Hemostaseology, Medical University of Vienna, Vienna, Austria; and <sup>2</sup>Harvard Medical School, Brigham and Women's Hospital, Division of Rheumatology, Immunology, and Allergy, Boston, MA

**Advanced systemic mastocytosis (SM) is a rare myeloid neoplasm characterized by uncontrolled accumulation of neoplastic mast cells (MCs) in various organs with consecutive impairment of organ function, drug resistance, and a poor prognosis. Advanced SM may present as smoldering or slowly progressing neoplasm but may also present as rapidly progressing aggressive SM or even as MC leukemia. Approximately half of the patients have an associated**

**hematologic non-MC-lineage disease (SM-AHNMD) or develop an AHNMD over time. Drug resistance may not only result from the KIT mutant D816V that is found in most patients, but also from KIT-independent pro-oncogenic signaling pathways that play a role in disease evolution. In patients with slow progression, advanced SM can often be kept under control for months with interferon- $\alpha$  or 2CdA. By contrast, in rapidly progressing aggressive SM and MC leu-**

**kemia, even polychemotherapy and hematopoietic stem cell transplantation may fail, which points to the need to develop new drugs and treatment concepts for these patients. In SM-AHNMD, separate treatment plans should be established for the SM component and the AHNMD component of the disease, with recognition that the AHNMD often has to be managed and treated as a secondary and thus a high-risk neoplasm. (*Blood*. 2010;116(26):5812-5817)**

## Introduction

Systemic mastocytosis (SM) is a clonal hematologic disease involving precommitted and mast cell (MC) committed hematopoietic progenitor cells.<sup>1-3</sup> The disease is characterized by abnormal growth and accumulation of MCs in one or more visceral organs.<sup>1-5</sup> The bone marrow (BM) is affected in almost all cases.<sup>4,5</sup> In more than 80% of all patients, the *KIT* mutation D816V is detectable in the BM. The mutant is found in all categories of SM.<sup>6-10</sup> Nevertheless, clinical features and courses in SM vary greatly and range from completely indolent with normal life expectancy to highly aggressive with short survival times.<sup>1-3,11-13</sup> Thus, *KIT* D816V may be an important “transforming” oncoprotein in SM, but with regard to progression to advanced disease including MC leukemia (MCL), other as yet undefined pro-oncogenic molecules and signaling pathways may play a more decisive role.

The World Health Organization (WHO) classification has defined the following categories of SM: indolent SM (ISM), SM with an associated hematologic non-MC-lineage disease (SM-AHNMD), aggressive SM (ASM), and MCL.<sup>14-16</sup> Smoldering SM (SSM), previously listed as a subcategory of ISM, is a new variant characterized by a high burden of MC, signs of dysplasia, and/or myeloproliferation in the BM (not fulfilling criteria of AHNMD), organomegaly, and multilineage involvement.<sup>14-17</sup> Patients may stay in a smoldering state for decades. However, in some of these patients, transformation to SM-AHNMD, ASM, or MCL is seen.<sup>17</sup> In ISM, disease progression to ASM may also occur, but it is an extremely rare event.

Patients with ISM and stable SSM are treated symptomatically with mediator-targeting drugs, including histamine receptor antagonists, but in general should not be treated with cytoreductive agents, interferon- $\alpha$  (IFN- $\alpha$ ), *KIT* tyrosine kinase

inhibitors, cladribine (2CdA), or other targeted (anticancer) drugs (Table 1).<sup>14,15,18</sup> Bisphosphonates are prescribed in case of marked osteopenia (T score < -2) or frank osteoporosis (Table 1).<sup>18</sup> In several patients with indolent SM, a coexisting allergy may be detected. In these patients, manifestation of allergic symptoms may be more severe (often life-threatening) than in patients without mastocytosis. When allergen-specific immunoglobulin E is detectable, specific immunotherapy may be considered depending on symptoms, patient characteristics, and type of allergen (Table 1).<sup>18</sup>

Mediator-associated problems occur quite frequently in ISM but are also seen in patients with advanced SM. However, in the latter group of patients, the predominant clinical problem is usually not related to mediator-associated symptoms but to the proliferation and often aggressive growth of MCs in diverse organs leading to organomegaly and organopathy, or even organ failure, also referred to as C-findings.<sup>19-21</sup> In ASM and MCL, organ systems typically involved with C-findings are the BM (marked cytopenia), liver (hepatomegaly, ascites, increased liver enzymes), bones (osteolysis, pathologic fractures), and the gastrointestinal tract (malabsorption, weight loss; Table 2).<sup>4,19-21</sup> An important aspect of ASM is that the disease can present as slowly progressing ASM (similar to SSM but with C-findings) or rapidly progressing ASM.<sup>17-19</sup> The latter may behave like MCL and can progress to frank MCL within a short time.<sup>22</sup> Another important aspect is that, during progression of ASM and MCL, the *KIT* mutant D816V may disappear,<sup>23</sup> which is best explained by selection and transformation of more malignant subclones derived from a more primitive neoplastic stem cell compartment where *KIT* D816V is not expressed.

Submitted August 3, 2010; accepted September 10, 2010. Prepublished online as *Blood* First Edition paper, September 20, 2010; DOI 10.1182/blood-2010-08-292144.

© 2010 by The American Society of Hematology

**Table 1. Commonly used basic supportive therapy and emergency therapy strategies for patients with SM**

Drug/therapy	Recommended indication	Schedule
HR1 antagonists*	Mediator-related symptoms	Continuous orally
HR2 antagonists*	Gastrointestinal tract symptoms	Continuous orally
Proton pump inhibitors	Gastrointestinal tract symptoms	As needed orally
Cromolyn sodium or other MC stabilizers	Gastrointestinal tract symptoms	As needed orally
Glucocorticosteroids	Mediator-related symptoms and anaphylaxis not responsive to HR1/HR2 antagonists and MC-stabilizing agents	Short courses orally or intravenously
Bisphosphonates*	T score < -2, osteolyses	Continuous orally or intravenously
Allergen immunotherapy†	Allergy (IgE <sup>+</sup> )†	Lifelong for venom
Epinephrine pen	Anaphylactic shock	Emergency, subcutaneously

HR indicates histamine receptor; and IgE, immunoglobulin E.

\*These drugs are also prescribed as prophylactic therapy in patients with SM. Examples of commonly used HR1 and HR2 antagonists include: long-acting HR1 antagonists fexofenadine, cetirizine, or loratadine, which may be supplemented with short-acting drugs, such as diphenhydramine or hydroxyzine (the latter have sedating effects); HR2 antagonists commonly used include ranitidine, famotidine, or cimetidine.

†Most commonly recommended for patients with hymenoptera venom allergy.

### How we diagnose and classify patients with advanced SM

The diagnosis of SM is established using SM criteria provided by the WHO.<sup>14-16</sup> At least one major and one minor or at least 3 minor SM criteria have to be fulfilled to establish the diagnosis of SM.<sup>14-16</sup> After having diagnosed SM, the first 2 questions to be answered are: (1) whether the patient indeed has advanced SM leading to end-organ damage (C-findings) and (2) whether an additional hematologic non-MC-lineage neoplasm is detectable (SM-AHNMD; Figure 1A). C-findings should lead to the assumption that the patient has ASM or MCL and thus will require a cytoreductive drug memory hook (eg, C = consider cytoreduction).<sup>14-16</sup> It is important to note that SM-related organ damage only counts as a C-finding when the histology demonstrates a devastating MC infiltrate as a primary cause of organ damage, and other causes for organ damage have been excluded (Figure 1B). It is also important to know that one single C-finding is sufficient to diagnose advanced SM (requiring antineoplastic therapy). However, in most patients with ASM, multiple C-findings are recorded.<sup>14-16</sup> In case the relationship between organopathy and SM is in question, serum tryptase levels should be reviewed: a rapid increase in serum tryptase levels supports the notion that the patient has ASM or MCL (Figure 1B). Another supportive marker is the phenotype of MC. Indeed, it has been described that CD30 is preferentially expressed in neoplastic MCs in ASM and MCL, and less abundantly in MCs in ISM.<sup>24-26</sup> In other words, strong expression of CD30 in most neoplastic MC is in favor of the diagnosis ASM or MCL, and we expect that CD30 will serve as a potential immunohistochemical grading marker in SM in the future.

The final diagnosis in patients with advanced SM has to be based on the percentage of MCs in the BM smear and the presence or absence of an AHNMD (Figure 1A).<sup>14-16</sup> In those with MCL, the percentage of MCs in the BM smear is more than or equal to 20%.<sup>14-16</sup> Here the differential counts for MCs should be performed in areas sufficiently away from marrow spicules, and it is also important to note that this 20% threshold only counts in the smear but not in the BM histology. In other words, an infiltration grade of 50% in the histology can well be found in ISM but is not a sign or criterion for MCL or ASM.<sup>14-16</sup> The other important checkpoint is AHNMD (Figure 1A). Here it is mandatory to apply further disease-related markers and to classify the AHNMD according to WHO criteria. Finally, both the SM and the AHNMD components of the disease are examined for expression of potential drug targets.

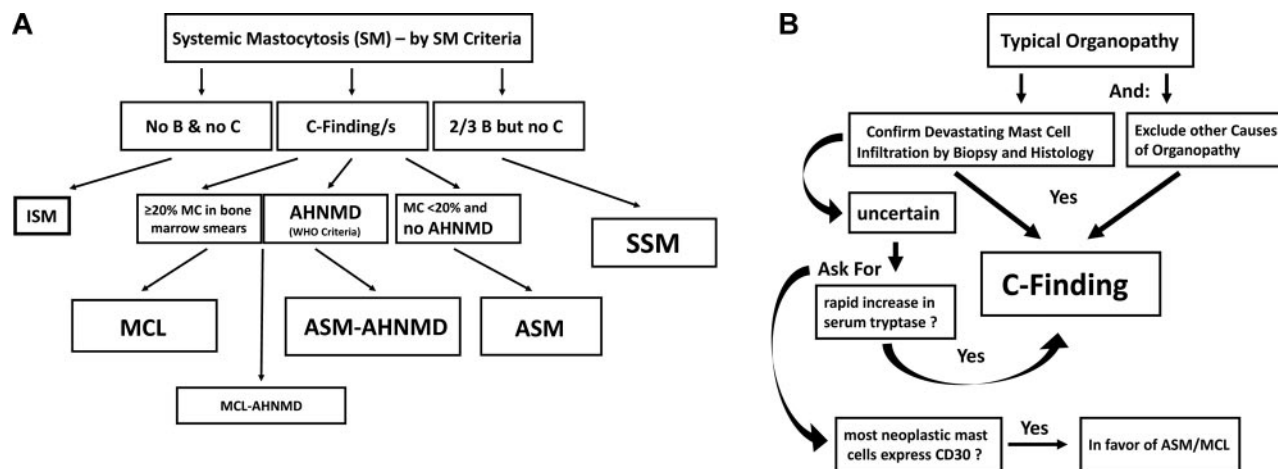
Sometimes the AHNMD harbors KIT D816V, which is important as this mutant introduces resistance to various targeted drugs, including imatinib.<sup>27,28</sup> In chronic myelomonocytic leukemia (CMML) associated with SM (SM-CMML), neoplastic monocytes usually display KIT D816V.<sup>29,30</sup> In other AHNMDs, however, such as acute myeloid leukemia (AML), AHNMD cells (blast cells) may lack KIT D816V even when MC are KIT D816V<sup>+</sup> cells.<sup>30,31</sup>

### How we treat patients with SSM

SSM is defined by the presence of 2 or 3 B-findings, which include (1) a markedly elevated serum tryptase level (> 200 ng/mL), (2) splenomegaly or lymphadenopathy, and (3) BM dysplasia or myeloproliferation.<sup>14,15,17</sup> Typically, KIT D816V is detectable in various myeloid lineages reflecting clonal multilineage involvement.<sup>17</sup> In most patients with SSM, the course remains stable over years or even decades.<sup>17,32-34</sup> For these patients, we recommend to wait and watch B-findings, including the serum tryptase level, which is a reliable marker of monitoring of (S)SM even when levels are highly elevated (sometimes exceeding 1000 ng/mL). SSM may be a “high-risk situation” for several reasons: first, progression to ASM or SM-AHNMD is sometimes found. In these patients, treatment follows the recommendation for newly diagnosed ASM or SM-AHNMD. In other patients, B-findings show

**Table 2. Typical symptoms and findings in various categories of SM**

Symptom/finding	Typically found in			
	ISM	SSM	ASM	MCL
<b>Mediator-related</b>				
Hypotension and shock	+	+	+/-	+/-
Peptic ulcer disease	+/-	+/-	+/-	+/-
Headache and diarrhea	+	+	+	+
<b>Organ-specific</b>				
Maculopapular skin lesions	+	+	+/-	-/+
Osteopenia/osteoporosis	+/-	+/-	-/+	-
<b>B-findings</b>				
Hepatosplenomegaly	-	+	+/-	+/-
Lymphadenopathy	-	+/-	+/-	-/+
Myeloproliferation or dysplasia	-	+/-	+/-	-/+
<b>C-findings</b>				
Marked cytopenia	-	-	+	+
Osteolysis with or without pathologic fractures	-	-	+	+
Ascites and elevated liver enzymes	-	-	+	+
Malabsorption plus hypoalbuminemia	-	-	+	+



**Figure 1. Diagnosis of advanced SM.** (A) Diagnostic algorithm in advanced SM. After having established the diagnosis SM by SM criteria, the patient is examined for the presence of B-findings and C-findings. C-findings are indicative of severe organ damage caused by the SM-infiltrate and are typically found in ASM and MCL, but not in ISM or SSM. The smoldering variant is defined by the presence of at least 2 B-findings. To differentiate between ASM and MCL, the BM and peripheral blood smear have to be examined. When the percentage of MCs in the BM smear is more than or equal to 20%, the diagnosis is MCL. (B) Definition of C-finding. End-organ damage in SM is diagnosed in a stepwise manner. First, organopathy is judged as being typical for advanced SM (eg, huge osteolyses plus bone fractures, enlarged liver with ascites, SM-based severe cytopenia). In a second step, a histology of the affected organ is obtained to confirm that organ damage is indeed caused by a devastating mast MC infiltrate. Then, organ damage can be regarded as a C-finding and the final diagnosis is established: ASM or MCL with or without an AHNMD.

progression, but no frank ASM or AHNMD develops.<sup>22,33,34</sup> In these patients, it may be necessary to start treatment with a cytoreductive agent. In other patients, splenectomy may be required to reduce the MC burden.<sup>35</sup> Although only a few pilot studies have been reported, it appears that one of the few effective agents for these patients is 2CdA.<sup>22,36-38</sup> A difficult situation is the occurrence of life-threatening anaphylaxis in patients with otherwise stable SSM. If anaphylaxis is provoked by an (known) allergen, especially hymenoptera venom, immunotherapy should be considered with recognition of potential risks.<sup>39,40</sup> Close monitoring is required for systemic reactions during immunotherapy in these patients. If no specific immunoglobulin E can be detected and anaphylaxis is repeatedly observed and life-threatening, and cannot be kept under control using conventional anti-mediator-type drugs, treatment with 2CdA or IFN- $\alpha$  may be justified. Indeed, 2CdA has been described to reduce the burden of KIT D816V<sup>+</sup> MCs and thereby the frequency and intensity of anaphylactic reactions in these patients.<sup>22</sup> Thus, as in essential thrombocythemia where patients receive cytoreductive agents to reduce the risk for life-threatening thromboembolism (but not to stop disease progression), patients with SSM may sometimes be considered as candidates for 2CdA or IFN- $\alpha$  therapy, to lower the risk of severe life-threatening anaphylaxis. Such treatment should preferentially be performed in controlled clinical trials. Unfortunately, only very few clinical trials have been initiated in SSM or ASM/MCL so far.

## How we treat patients with ASM with slow progression

Many patients with ASM with slow progression can be kept under control for several months or even years by IFN- $\alpha$  or 2CdA.<sup>22,36-38,41-43</sup> Therefore, we recommend these agents as first-line treatment in these patients. We usually start with prednisolone at 1 mg/kg body weight for 3 to 7 days and then start to add IFN- $\alpha$  (in hospitalized patients) at a dose of 3 million units 3 times a week. Thereafter, we try to reduce the dose of the steroid and to increase the dose of IFN- $\alpha$  to a maximum of 5 million units per day if possible. In

patients with ascites or severe mediator-related symptoms, a small maintenance dose of prednisolone ( $\leq$  5-10 mg/day) should be prescribed. Otherwise, prednisolone should be discontinued if possible. Monitoring of treatment responses is performed by repeated evaluation of C-findings, repeated BM investigations, and measurement of serum tryptase levels.<sup>43</sup> In those patients who have an unsatisfactory or no response or a relapse, alternative therapy must be considered. We usually recommend to administer 2CdA (0.13 mg/kg per day intravenously over 5 days; 3-6 cycles) as second-line treatment in these patients or to enroll the patient in a clinical trial with a KIT D816V inhibitor, such as PKC412 (midostaurin). In those with rapid progression, more intensive treatment (as for ASM/MCL) is usually required. In patients with osteopathy (osteolysis, osteoporosis, or marked osteopenia: T score  $<$  -2) and those who receive long-term glucocorticosteroids, bisphosphonates are prescribed.<sup>18</sup> It should be noted here that osteoporosis is a frequent finding in patients with indolent SM and does not qualify as a C-finding unless it is also associated with large osteolytic lesions and pathologic fractures.

In a few patients with slowly progressing ASM, no codon 816 mutation in *KIT* is detectable, even when BM cells are repeatedly tested.<sup>44,45</sup> Some of these patients have other *KIT* mutations, and these mutants (as well as wild-type *KIT*) may sometimes respond to imatinib therapy.<sup>44,45</sup> By contrast, in patients in whom KIT D816V is detectable, imatinib should not be used as the mutation introduces resistance. Detection of the KIT D816V mutant should ideally be performed in bone marrow aspirates or lesional tissue rather than peripheral blood as false-negative findings are common when (only) blood samples are tested.

## How we treat patients with rapidly progressing ASM and MCL

Rapid progression in ASM is defined by (1) rapid deterioration of end-organ function caused by the MC infiltrate and (2) rapid increase in serum tryptase levels.<sup>14-16,18-20</sup> Several of these patients progress to MCL within a short time. Responses to IFN- $\alpha$  are

**Table 3. Antiproliferative drugs used to treat patients with advanced systemic mastocytosis**

Drug	Effects seen in SSM and slowly progressing ASM	Effects seen in ASM or MCL with rapid progression
Interferon- $\alpha$	Responses including MR in a group of patients	Usually no responses seen
2CdA	Responses frequently seen; MR in a group of patients	Transient responses in a few patients
PKC412	Studies ongoing	Studies ongoing and transient responses in some cases <sup>23</sup>
Dasatinib	Studies ongoing	Studies ongoing
Polychemotherapy	—	May induce remission or debulking before SCT
<b>Experimental drugs</b>		
mTOR blockers	Studies ongoing	Studies ongoing
PI3 kinase blockers	Studies planned	Studies planned

All antiproliferative drugs used are experimental in nature.

MR indicates major clinical response; —, not applicable; mTOR, mammalian target of rapamycin; and PI3, phosphatidylinositol 3.

usually not seen, and responses to 2CdA usually are short-lived and followed by a relapse.<sup>14-16,22,46</sup> Nevertheless, 2CdA is often applied in a first attempt to control the disease. In some of these patients, the burden of MC can indeed be reduced by this drug, at least for a certain time, so that further treatment can be planned.<sup>22,46</sup> If the patient is young and has a suitable donor, hematopoietic stem cell transplantation (SCT) is the only chance to induce a stable remission in advanced SM. Before SCT, debulking should be performed by polychemotherapy (polychemotherapy regimens containing high-dose cytosine arabinoside and a nucleoside such as fludarabine) or repeated cycles of 2CdA. With this approach, the physician will learn whether the disease is responsive and whether the patient is fit enough to undergo SCT. Patients who fail 2CdA and polychemotherapy are candidates for experimental drugs. If the disease is completely resistant to chemotherapy and all other drugs, or relapses, palliative cytoreduction (with hydroxyurea) is initiated.<sup>14-16,18</sup> The recommendations for treatment of patients with MCL are essentially the same as that for treatment of patients with rapidly progressing ASM. However, in contrast to ASM, 2CdA should not be considered as monotherapy in these patients. Whether patients with MCL may indeed benefit from combination polychemotherapy plus 2CdA remains unknown.

## How we treat patients with SM-AHNMD

In approximately 50% of all patients with advanced SM, an AHNMD is diagnosed at presentation or develops during the course of disease.<sup>14-16,47</sup> In these patients, both the SM and the AHNMD components of the disease have to be classified according to WHO criteria.<sup>14-16</sup> In most cases, the *KIT* mutation D816V is detectable. Sometimes the mutant is not only expressed in MC, but also in AHNMD cells, depending on the type of AHNMD. In SM-CMML, neoplastic monocytes usually display *KIT* D816V.<sup>29,30</sup> By contrast, in SM-AML, AML blasts often lack *KIT* D816V. Almost all types of hematopoietic neoplasms can develop as AHNMD in SM.<sup>14-16,47</sup> However, whereas myeloid neoplasms are more commonly detected, B-cell neoplasms are less frequent (estimated frequency: 10% of all AHNMD), and a concomitant T-cell neoplasm represents an exceptional rarity, a distribution that is reminiscent of lineage-involvement in the blast phase of CML. The SM component in SM-AHNMD often presents as ASM and less frequently as MCL. A rather frequent constellation is ASM-CMML.<sup>14-16,47,48</sup> From a practical viewpoint, it seems straightforward to treat the SM component of the disease as if no AHNMD was detected and the AHNMD component as if no SM was diagnosed,<sup>14-18</sup> with one important exception: indeed, any type of AHNMD must be regarded as having developed secondary to SM, which may be of prognostic importance. Likewise, in

SM-AML, AML should be treated as other patients with secondary (not de novo) and thus high-risk AML. Indeed, for most of these patients, high-dose chemotherapy and SCT are recommended.<sup>46-48</sup> With regard to AML, it is also important to note that many patients with SM-AML are (mis)diagnosed as *KIT* D816V<sup>+</sup> AML because the SM component has just been overlooked or the proliferation of AML blasts overwhelms the slower-growing coexisting SM component (occult SM).<sup>31</sup> In some of these patients, SM can be more readily recognized when blast cells cleared after cytoreductive therapy for AML. Today, we recommend that bone marrow cells are examined for the presence of *KIT* D816V in all patients with AML and CMML. In a few patients with SM-AHNMD, the *JAK2* mutant V617F is detected in AHNMD cells.<sup>49</sup> In these patients, the AHNMD is often classified as primary myelofibrosis.<sup>49</sup> Other patients have SM-PV or SM-MDS.<sup>46,47</sup> Coexistence of SM with Ph<sup>+</sup> CML is an extremely rare condition.

A special situation is SM with associated chronic eosinophilic leukemia (SM-CEL).<sup>50</sup> These patients often have mildly or markedly elevated tryptase levels and spindle-shaped MCs expressing CD25. Neoplastic eosinophils often outnumber MCs in these patients, so that only CEL is diagnosed. In other patients, no SM is detectable, even after a thorough investigation. In most cases, the *FIP1L1/PDGFRA* fusion gene product, but no *KIT* mutation, is detectable, even when SM is diagnosed. However, this does not mean that *FIP1L1/PDGFRA* is a molecular marker of SM.<sup>50</sup> In rare cases, both mutants (*FIP1L1/PDGFRA* and *KIT* D816V) are detectable (P.V., unpublished observation, June 2010). In most patients, SM is classified as ISM, and only the CEL component requires antineoplastic therapy. As in CEL without SM, patients with SM-CEL start with imatinib (100 mg daily), a drug to which they are exquisitely responsive.<sup>21</sup>

## Novel drugs and novel treatment approaches for ASM and MCL

Several novel drugs and approaches have been proposed for the treatment of patients with ASM and MCL (Table 3). Some of these concepts are based on the inhibition of *KIT* D816V in neoplastic cells. Examples for drugs blocking the tyrosine kinase activity of *KIT* D816V are dasatinib and PKC412 (midostaurin).<sup>21,23,45</sup> Both drugs can also suppress histamine secretion from MCs. The disadvantage of dasatinib is its short half-life and its side effect profile. Indeed, dasatinib has yielded largely disappointing results in clinical trials in SM performed thus far.<sup>51,52</sup> PKC412 is currently tested in clinical trials in patients with ASM and MCL. However, although *KIT* D816V<sup>+</sup> subclones may respond, long-lasting effects have not been described, and it may happen that the patient has an



early relapse with a KIT D816V<sup>-</sup> subclone.<sup>23</sup> Other drugs block critical KIT-downstream signaling molecules, such as phosphatidylinositol 3 kinase or mammalian target of rapamycin (Table 3). However, in ASM and MCL, additional KIT-independent signaling molecules and pathways may play a more important, or even decisive, role in growth of neoplastic cells. Therefore, more recent treatment concepts focus on various signaling pathways and combinations of drugs targeting KIT D816V and other critical targets in SM.

## Response evaluation

Treatment responses in ASM and MCL should be evaluated by using criteria proposed by the consensus group.<sup>11,18</sup> The following response categories are defined: a major response (disappearance of C-findings), a partial response (partial resolution of C-findings), and no response.<sup>11,18</sup> MR can further be divided into a complete remission (complete disappearance of MC infiltrates and return of serum tryptase levels to < 20 ng/mL), incomplete remission (incomplete decrease in MC infiltrates and tryptase), and a pure clinical response (no decrease in MC infiltrates and tryptase levels). Partial response is further divided into a good partial response (> 50% regression of C-findings) and minor response. Finally, NR is divided into stable disease and progressive disease.<sup>11,18</sup> Thus, responses are currently adapted to C-findings, which seems justified as most drugs are not inducing complete remissions. An important aspect in this evaluation is that C-findings may sometimes remain, although tryptase levels markedly decrease and MC infiltration is markedly reduced. In these patients, it may turn out that the clinical finding can no longer be judged as C-finding as the definition is no longer fulfilled (invasive MC infiltrate disappeared). Therefore, the evaluation of responses using C-finding criteria requires knowledge and some experience in the field, and exact application of all criteria. Another important aspect in response evaluation is that mediator-related symptoms may also respond to some of the cytoreductive (targeted) drugs applied in ASM and MCL. Likewise, as mentioned, some of these agents, like PKC412 or dasatinib, may block immunoglobulin E-dependent histamine secretion from MCs; and mediator-related symptoms may improve with 2CdA therapy. Therefore, it is also important to grade mediator-related symptoms in these patients and to determine responses using available response criteria. Again, it is recommended that the response criteria provided by the consensus group are applied.<sup>18</sup>

## References

- Valent P, Akin C, Sperr WR, et al. Diagnosis and treatment of systemic mastocytosis: state of the art. *Br J Haematol*. 2003;122(5):695-717.
- Metcalfe DD. Mast cells and mastocytosis. *Blood*. 2008;112(4):946-956.
- Pardanani A, Tefferi A. Systemic mastocytosis in adults: a review on prognosis and treatment based on 342 Mayo Clinic patients and current literature. *Curr Opin Hematol*. 2010;17(2):125-132.
- Horny HP, Valent P. Diagnosis of mastocytosis: general histopathological aspects, morphological criteria, and immunohistochemical findings. *Leuk Res*. 2001;25(7):543-551.
- Horny HP, Sotlar K, Valent P. Mastocytosis: state of the art. *Pathobiology*. 2007;74(2):121-132.
- Nagata H, Worobec AS, Oh CK, et al. Identification of a point mutation in the catalytic domain of the protooncogene c-kit in peripheral blood mononuclear cells of patients who have mastocytosis with an associated hematologic disorder. *Proc Natl Acad Sci U S A*. 1995;92(23):10560-10564.
- Longley BJ, Tyrrell L, Lu SZ, et al. Somatic c-KIT activating mutation in urticaria pigmentosa and aggressive mastocytosis: establishment of clonality in a human mast cell neoplasm. *Nat Genet*. 1996;12(3):312-314.
- Fritsche-Polanz R, Jordan JH, Feix A, et al. Mutation analysis of C-KIT in patients with myelodysplastic syndromes without mastocytosis and cases of systemic mastocytosis. *Br J Haematol*. 2001;113(2):357-364.
- Féger F, Ribadeau Dumas A, Leriche L, Valent P, Arock M. Kit and c-kit mutations in mastocytosis: a short overview with special reference to novel molecular and diagnostic concepts. *Int Arch Allergy Immunol*. 2002;127(2):110-114.
- Garcia-Montero AC, Jara-Acevedo M, Teodosio C, et al. KIT mutation in mast cells and other bone marrow hematopoietic cell lineages in systemic mast cell disorders: a prospective study of the Spanish Network on Mastocytosis (REMA) in a series of 113 patients. *Blood*. 2006;108(7):2366-2372.
- Valent P, Akin C, Sperr WR, et al. Aggressive systemic mastocytosis and related mast cell disorders: current treatment options and proposed response criteria. *Leuk Res*. 2003;27(7):635-641.
- Valent P, Akin C, Sperr WR, et al. Mastocytosis: pathology, genetics, and current options for therapy. *Leuk Lymphoma*. 2005;46(1):35-48.
- Lim KH, Tefferi A, Lasho TL, et al. Systemic mastocytosis in 342 consecutive adults: survival studies and prognostic factors. *Blood*. 2009;113(23):5727-5736.
- Valent P, Horny HP, Escribano L, et al. Diagnostic

## Perspectives in therapy of advanced SM: the foreseeable future

Treatment of advanced SM remains one of the most challenging areas in clinical hematology. Whereas mediator-related symptoms can be controlled in most cases, MC expansion is usually resistant to most conventional antineoplastic drugs. In nontransplantable patients exhibiting KIT D816V, some good, albeit transient, responses to 2CdA, PKC412, and polychemotherapy regimens containing high-dose cytosine arabinoside have been described. These approaches will hopefully be combined with each other and with transplantation strategies in the future, with the hope to achieve stable long-term remissions. There is also hope that novel more potent agents will be developed that can block not only KIT D816V-dependent signaling pathways in neoplastic MC, but also KIT-independent pro-oncogenic pathways that appear to play a predominant role in disease progression in ASM and MCL. Finally, with better knowledge and increased awareness, therapy of ASM and MCL should improve through earlier and more accurate diagnosis and early treatment intervention.

## Acknowledgments

This work was supported by the Fonds zur Förderung der Wissenschaftlichen Forschung in Österreich (grants P21173-B13 and SFB-F01820) and the Medical University of Vienna (Mastocytosis Research Grant).

## Authorship

Contribution: P.V., W.R.S., and C.A. wrote the paper and approved the final version of manuscript.

Conflict-of-interest disclosure: P.V. received research grants from Novartis and Bristol-Myers Squibb and is Novartis consultant in a PKC412 project. C.A. has a consultancy agreement with Novartis for a PKC412 trial. W.R.S. declares no competing financial interests.

Correspondence: Peter Valent, Department of Internal Medicine I, Division of Hematology & Hemostaseology, Medical University of Vienna, Währinger Gürtel 18-20, A-1090 Vienna, Austria; e-mail: peter.valent@meduniwien.ac.at.

- criteria and classification of mastocytosis: a consensus proposal. *Leuk Res*. 2001;25(7):603-625.
15. Valent P, Horny H-P, Li CY, et al. Mastocytosis (mast cell disease). In: Jaffe ES, Harris NL, Stein H, Vardiman JW, eds. *World Health Organization (WHO) Classification of Tumours: Pathology & Genetics. Tumours of Haematopoietic and Lymphoid Tissues*. Lyon, France: IARC Press; 2001: 291-302.
  16. Horny HP, Akin C, Metcalfe DD, et al. Mastocytosis (mast cell disease). In: Swerdlow SH, Campo E, Harris NL, et al, eds. *World Health Organization (WHO) Classification of Tumours: Pathology & Genetics. Tumours of Haematopoietic and Lymphoid Tissues*. Lyon, France: IARC Press; 2008:54-63.
  17. Valent P, Akin C, Sperr WR, Horny HP, Metcalfe DD. Smoldering mastocytosis: a novel subtype of systemic mastocytosis with slow progression. *Int Arch Allergy Immunol*. 2002;127(2):137-139.
  18. Valent P, Akin C, Escribano L, et al. Standards and standardization in mastocytosis: consensus statements on diagnostics, treatment recommendations and response criteria. *Eur J Clin Invest*. 2007;37(6):435-453.
  19. Metcalfe DD. The liver, spleen, and lymph nodes in mastocytosis. *J Invest Dermatol*. 1991; 96(suppl 3):45S-46S.
  20. Aichberger KJ, Sperr WR, Gleixner KV, Kretschmer A, Valent P. Treatment responses to cladribine and dasatinib in rapidly progressing aggressive mastocytosis. *Eur J Clin Invest*. 2008; 38(11):869-873.
  21. Pardanani A, Akin C, Valent P. Pathogenesis, clinical features, and treatment advances in mastocytosis. *Best Pract Res Clin Haematol*. 2006; 19(3):595-615.
  22. Böhm A, Sonneck K, Gleixner KV, et al. In vitro and in vivo growth-inhibitory effects of cladribine on neoplastic mast cells exhibiting the imatinib-resistant KIT mutation D816V. *Exp Hematol*. 2010;38(9):744-755.
  23. Gotlib J, Berubé C, Growney JD, et al. Activity of the tyrosine kinase inhibitor PKC412 in a patient with mast cell leukemia with the D816V KIT mutation. *Blood*. 2005;106(8):2865-2870.
  24. Horny HP, Sotlar K, Valent P. Differential diagnoses of systemic mastocytosis in routinely processed bone marrow biopsy specimens: a review. *Pathobiology*. 2010;77(4):169-180.
  25. Sotlar K, Cerny-Reiterer S, Petat-Dutter K, et al. Aberrant expression of CD30 in neoplastic mast cells in high grade mastocytosis. *Mod Pathol*. In press.
  26. Valent P, Cerny-Reiterer S, Herrmann H, et al. Phenotypic heterogeneity and target expression profiles of normal and neoplastic mast cells. *Best Pract Res Clin Haematol*. In press.
  27. Ma Y, Zeng S, Metcalfe DD, et al. The c-KIT mutation causing human mastocytosis is resistant to STI571 and other KIT kinase inhibitors: kinases with enzymatic site mutations show different inhibitor sensitivity profiles than wild-type kinases and those with regulatory-type mutations. *Blood*. 2002;99(5):1741-1744.
  28. Akin C, Brockow K, D'Ambrosio C, et al. Effects of tyrosine kinase inhibitor STI571 on human mast cells bearing wild-type or mutated c-kit. *Exp Hematol*. 2003;31(8):686-692.
  29. Sotlar K, Marafioti T, Griesser H, et al. Detection of c-kit mutation Asp 816 to Val in microdissected bone marrow infiltrates in a case of systemic mastocytosis associated with chronic myelomonocytic leukaemia. *Mol Pathol*. 2000;53(4): 188-193.
  30. Sotlar K, Colak S, Bache A, et al. Variable presence of KITD816V in clonal haematological non-mast cell lineage diseases associated with systemic mastocytosis (SM-AHNMD). *J Pathol*. 2010;220(5):586-595.
  31. Fritsche-Polanz R, Fritz M, Huber A, et al. High frequency of concomitant mastocytosis in patients with acute myeloid leukemia exhibiting the transforming KIT mutation D816V. *Mol Oncol*. 2010;4(4):335-346.
  32. Jordan JH, Fritsche-Polanz R, Sperr WR, et al. A case of 'smoldering' mastocytosis with high mast cell burden, monoclonal myeloid cells, and C-KIT mutation Asp-816-Val. *Leuk Res*. 2001; 25(7):627-634.
  33. Akin C, Scott LM, Metcalfe DD. Slowly progressive systemic mastocytosis with high mast-cell burden and no evidence of a non-mast-cell hematologic disorder: an example of a smoldering case? *Leuk Res*. 2001;25(7):635-638.
  34. Hauswirth AW, Sperr WR, Ghannadan M, et al. A case of smoldering mastocytosis with peripheral blood eosinophilia and lymphadenopathy. *Leuk Res*. 2002;26(6):601-606.
  35. Friedman B, Darling G, Norton J, Hamby L, Metcalfe D. Splenectomy in the management of systemic mast cell disease. *Surgery*. 1990;107(1):94-100.
  36. Tefferi A, Li CY, Butterfield JH, Hoagland HC. Treatment of systemic mast-cell disease with cladribine. *N Engl J Med*. 2001;344(4):307-309.
  37. Kluijn-Nelemans HC, Oldhoff JM, Van Doormaal JJ, et al. Cladribine therapy for systemic mastocytosis. *Blood*. 2003;102(13):4270-4276.
  38. Schleyer V, Meyer S, Landthaler M, Szeimies RM. Smoldering systemic mastocytosis: successful therapy with cladribine. *Hautarzt*. 2004;55(7): 658-662.
  39. González de Olano D, Alvarez-Twose I, Esteban-López MI, et al. Safety and effectiveness of immunotherapy in patients with indolent systemic mastocytosis presenting with Hymenoptera venom anaphylaxis. *J Allergy Clin Immunol*. 2008;121(2):519-526.
  40. Niedoszytko M, de Monchy J, van Doormaal JJ, Jassem E, Oude Elberink JN. Mastocytosis and insect venom allergy: diagnosis, safety and efficacy of venom immunotherapy. *Allergy*. 2009; 64(9):1237-1245.
  41. Kluijn-Nelemans HC, Jansen JH, Breukelman H, et al. Response to interferon alfa-2b in a patient with systemic mastocytosis. *N Engl J Med*. 1992; 326(9):619-623.
  42. Butterfield JH. Response of severe systemic mastocytosis to interferon alpha. *Br J Dermatol*. 1998;138(3):489-495.
  43. Hauswirth AW, Simonitsch-Klupp I, Uffmann M, et al. Response to therapy with interferon alpha-2b and prednisolone in aggressive systemic mastocytosis: report of five cases and review of the literature. *Leuk Res*. 2004;28(3):249-257.
  44. Akin C, Fumo G, Yavuz AS, Lipsky PE, Neckers L, Metcalfe DD. A novel form of mastocytosis associated with a transmembrane c-kit mutation and response to imatinib. *Blood*. 2004;103(8): 3222-3225.
  45. Gotlib J. KIT mutations in mastocytosis and their potential as therapeutic targets. *Immunol Allergy Clin North Am*. 2006;26(3):575-592.
  46. Lim KH, Pardanani A, Butterfield JH, Li CY, Tefferi A. Cytoreductive therapy in 108 adults with systemic mastocytosis: outcome analysis and response prediction during treatment with interferon-alpha, hydroxyurea, imatinib mesylate or 2-chlorodeoxyadenosine. *Am J Hematol*. 2009; 84(12):790-794.
  47. Pardanani A, Lim KH, Lasho TL, et al. Prognostically relevant breakdown of 123 patients with systemic mastocytosis associated with other myeloid malignancies. *Blood*. 2009;114(18):3769-3772.
  48. Sperr WR, Horny HP, Valent P. Spectrum of associated clonal hematologic non-mast cell lineage disorders occurring in patients with systemic mastocytosis. *Int Arch Allergy Immunol*. 2002; 127(2):140-142.
  49. Sotlar K, Bache A, Stellmacher F, Bültmann B, Valent P, Horny HP. Systemic mastocytosis associated with chronic idiopathic myelofibrosis: a distinct subtype of systemic mastocytosis associated with a clonal hematological non-mast cell lineage disorder carrying the activating point mutations KITD816V and JAK2V617F. *J Mol Diagn*. 2008;10:58-66.
  50. Valent P, Akin C, Metcalfe DD. FIP1L1/PDGFRA is a molecular marker of chronic eosinophilic leukaemia but not for systemic mastocytosis. *Eur J Clin Invest*. 2007;37(2):153-154.
  51. Purtil D, Cooney J, Sinniah R, et al. Dasatinib therapy for systemic mastocytosis: four cases. *Eur J Haematol*. 2008;80(5):456-458.
  52. Verstovsek S, Tefferi A, Cortes J, et al. Phase II study of dasatinib in Philadelphia chromosome-negative acute and chronic myeloid diseases, including systemic mastocytosis. *Clin Cancer Res*. 2008;14(12):3906-3915.