

Brief report

Improvement in hematological, visceral, and skeletal manifestations of Gaucher disease type 1 with oral eliglustat tartrate (Genz-112638) treatment: 2-year results of a phase 2 study

Elena Lukina,¹ Nora Watman,² Elsa Avila Arreguin,³ Marta Dragosky,⁴ Marcelo Iastrebner,⁴ Hanna Rosenbaum,⁵ Mici Phillips,⁶ Gregory M. Pastores,⁷ Ravi S. Kamath,⁸ Daniel I. Rosenthal,⁸ Mathilde Kaper,⁹ Tejdeep Singh,⁹ Ana Cristina Puga,⁹ and M. Judith Peterschmitt⁹

¹Hematology Research Center, Russian Academy of Medical Sciences, Moscow, Russia; ²Hospital Ramos Mejia, Buenos Aires, Argentina; ³Instituto Mexicano del Seguro Social, Hospital de Especialidades, Mexico City, Mexico; ⁴Instituto Argentino de Diagnóstico y Tratamiento, Buenos Aires, Argentina; ⁵Rambam Medical Center, Haifa, Israel; ⁶Shaare Zedek Medical Center, Jerusalem, Israel; ⁷New York University, New York, NY; ⁸Massachusetts General Hospital, Boston, MA; and ⁹Genzyme Corporation, Cambridge, MA

Eliglustat tartrate is an investigational oral substrate reduction therapy for Gaucher disease type 1 that is pharmacologically distinct from intravenous enzyme replacement therapy. Eliglustat tartrate improved clinical manifestations in patients who received 50 or 100 mg twice daily for 1 year during an open-label phase 2 study (*Blood*. 2010;116(6):893-899). We report further improvements after 2 years of treatment in 20 patients (11 females, 9 males; mean age, 33 years) with baseline splenomegaly and thrombocytopenia and/or anemia. Statistically significant

($P < .001$) percentage improvements from baseline occurred in platelet count (mean \pm SD, $81\% \pm 56\%$), hemoglobin level ($20\% \pm 15\%$), spleen volume ($-52\% \pm 11\%$), and liver volume ($-24\% \pm 13\%$). Mean platelet count increased $\sim 50\,000/\text{mm}^3$. Mean hemoglobin level increased 2.1 g/dL overall and 3.1 g/dL in 10 patients with baseline anemia. Organ volume reductions were greatest in patients with severe baseline organomegaly. Seventeen (85%) patients met established therapeutic goals for ≥ 3 of the 4 parameters. Lumbar spine bone

mineral density increased $7.8\% \pm 10.6\%$ ($P = .01$) and T-score 0.6 ± 0.8 ($P = .012$), with major gains in osteoporotic and osteopenic patients. Magnetic resonance imaging assessment showed that bone marrow infiltration by Gaucher cells was decreased (8/18 patients) or stable (10/18 patients). No safety-related trends emerged during 2 years of treatment. This multisite, open-label, single-arm phase 2 study is registered at www.clinicaltrials.gov as NCT00358150. (*Blood*. 2010;116(20):4095-4098)

Introduction

Eliglustat tartrate (formerly Genz-112638) is an investigational oral substrate reduction therapy (SRT) for Gaucher disease type 1 (GD1), an autosomal recessive lysosomal storage disorder caused by mutations of acid β -glucosidase (glucocerebrosidase; glucosylceramidase; EC 3.2.1.45). In GD1, normal catabolism of glycosphingolipids (predominantly glucosylceramide) is impaired, and undegraded substrates accumulate in "Gaucher cells" of the monocyte/macrophage system, leading to multiorgan disease pathology.¹ Thrombocytopenia, anemia, hepatosplenomegaly, and skeletal complications are the most common clinical manifestations, although the pattern and extent of organ involvement vary widely among individuals.

Eliglustat tartrate partially inhibits glucosylceramide synthase, thereby reducing endogenous production of glucosylceramide.² We recently reported the pharmacokinetics and maximum tolerated doses of eliglustat tartrate from phase 1 studies in healthy normal subjects³ as well as promising results from the 1-year primary analysis period of a phase 2 trial in GD1 patients.⁴ Here we present longer-term efficacy and safety data obtained after 2 years of treatment in the phase 2 study and assess patient responses to eliglustat tartrate with reference to evidence-based therapeutic

goals established for intravenous enzyme replacement therapy (ERT) with imiglucerase.⁵

Methods

This multisite, open-label, single-arm phase 2 study is registered as NCT00358150 at www.clinicaltrials.gov. Each site's Ethics Committee or Institutional Review Board approved the protocol. Patients provided written informed consent in accordance with the Declaration of Helsinki. As previously described,⁴ 26 patients with GD1 enrolled, and 6 (13%) withdrew before or at 1 year. The remaining 20 patients continued in the study extension and completed 2 years of treatment. Eliglustat tartrate capsules were self-administered; the dosage was 50 mg ($n = 5$) or 100 mg ($n = 15$) twice daily, based on day 10 plasma drug concentrations.

Hemoglobin level, platelet count and plasma biomarkers were analyzed at central laboratories. Spleen and liver volumes (reported as multiples of normal [MN]) were derived from magnetic resonance imaging (MRI) or computed tomography (CT) scans, and skeletal assessments were based on x-ray, dual-energy x-ray absorptiometry (DEXA), and MRI. Images were obtained at the study sites but evaluated by central reviewers who were blinded for organ volume determinations and unblinded for skeletal assessments. Safety assessments, which were periodically reviewed by an

Submitted June 30, 2010; accepted August 6, 2010. Prepublished online as *Blood* First Edition paper, August 16, 2010; DOI 10.1182/blood-2010-06-293902.

The publication costs of this article were defrayed in part by page charge

payment. Therefore, and solely to indicate this fact, this article is hereby marked "advertisement" in accordance with 18 USC section 1734.

© 2010 by The American Society of Hematology

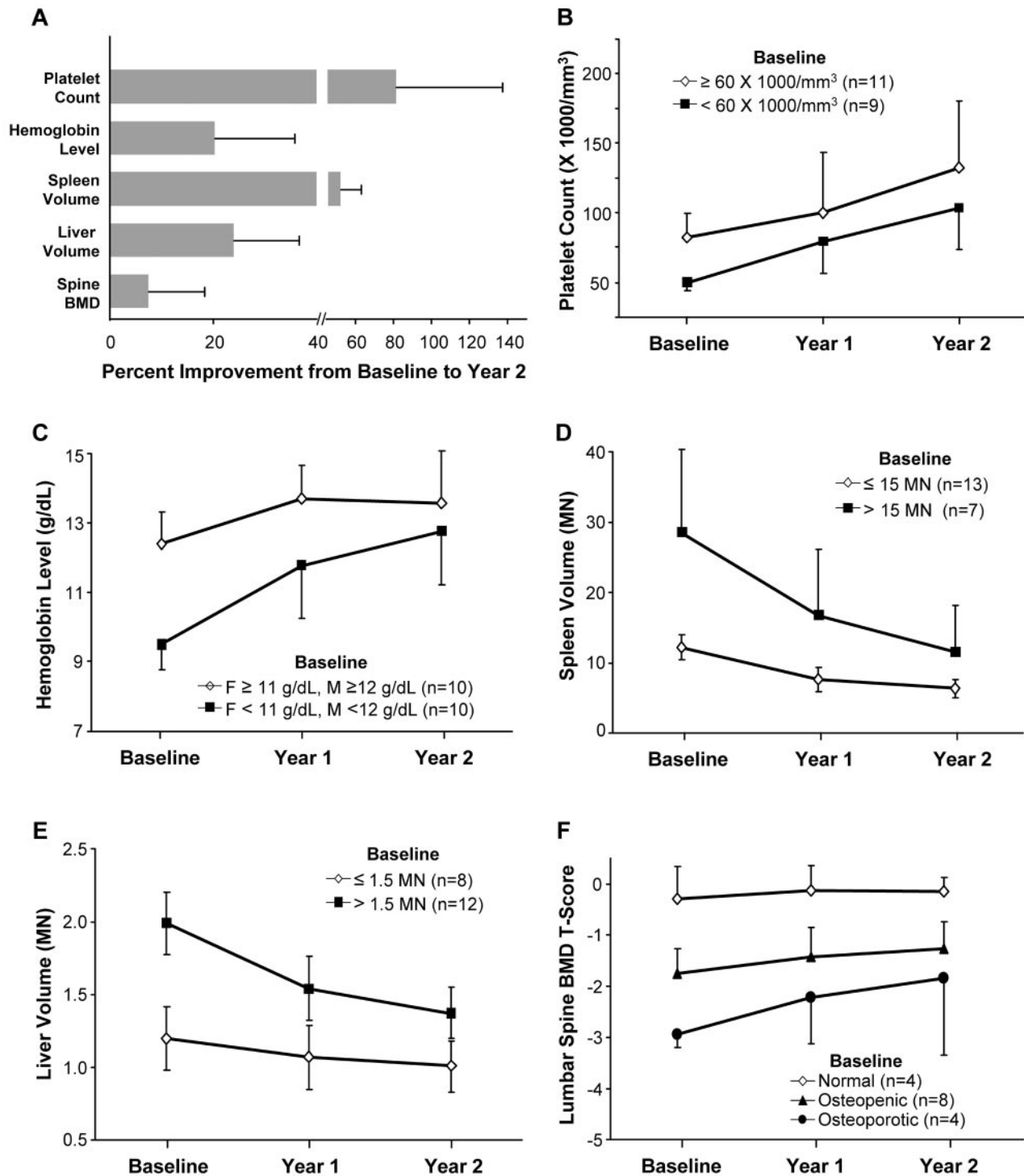


Figure 1. Improvements in hematological, visceral, and skeletal parameters: overall and stratified by baseline disease severity. (A-F) Data are reported as means \pm SD. N = 20, except n = 16 for lumbar spine BMD (excluding 4 patients for receipt of zoledronate during the study [n = 1], assessment with different DEXA machines at different time points [n = 1], lack of 1-year data [n = 1], or presence of radiographic abnormalities preventing BMD assessment [n = 1]). BMD indicates bone mineral density; MN, multiples of normal (volume); F, female; and M, male. Baseline lumbar spine BMD T-scores were categorized as normal, osteopenic, or osteoporotic, as previously described.¹¹

Table 1. Summary of results for study patients who met established therapeutic goals⁵ after 2 years of eliglustat tartrate treatment

Clinical parameter	Baseline disease severity	Baseline values for the study patients	Therapeutic goal after 2 y of imiglucerase treatment	Percent (proportion) meeting goal	
				Subgroup	Overall
Platelet count per mm ³	Moderate thrombocytopenia	61 000-105 500	Attain low-normal platelet count of 120 000	64% (7/11)	60% (12/20)
	Severe thrombocytopenia	39 000-58 000	Double platelet count	56% (5/9)	
Hemoglobin level, g/dL	Normal hemoglobin to mild anemia	Females, 11.2-12.5; males, 12.0-14.6	Maintain hemoglobin level	100% (10/10)	95% (19/20)
	Mild to moderate anemia	Females, 8.7-9.8; males, 9.7-11.9	Increase to \geq 11 for females and \leq 12 for males	90% (9/10)	
Spleen volume, MN	Mild to moderate splenomegaly	8.2-14.6	Reduce volume by \leq 50% and/or reduce to $<$ 8 MN	92% (12/13)	90% (18/20)
	Moderate to severe splenomegaly	15.1-49.2	Reduce volume by \leq 50% and/or reduce to $<$ 8 MN	86% (6/7)	
Liver volume, MN	Mild to moderate hepatomegaly	0.81-1.50	Maintain volume	100% (8/8)	95% (19/20)
	Moderate to severe hepatomegaly	1.53-2.47	Reduce volume by \geq 20% and/or reduce to \leq 1.5 MN	92% (11/12)	

MN indicates multiples of normal (volume).

independent Data Monitoring Committee, included adverse event (AE) reporting and scheduled laboratory, electrocardiographic, neurologic, and nerve conduction velocity (NCV) evaluations. Data analyses were performed by Genzyme Corporation, as previously described.⁴

Results and discussion

The 20 patients who completed 2 years of eliglustat tartrate treatment included 11 females and 9 males, aged 18 to 55 years (mean, 33 years) at first treatment. Acid β -glucosidase activity ranged from nondetectable levels to 12% of normal.

Figure 1A shows that statistically significant ($P < .001$) mean percent improvements from baseline occurred for platelet count (+81%), hemoglobin level (+20%), spleen volume (-52%), and liver volume (-24%) at 2 years. Stratification of each disease parameter by baseline severity (Figure 1B-E) revealed that platelet count recovered steadily, on average by $\sim 50\,000/\text{mm}^3$, regardless of the severity of baseline thrombocytopenia. Hemoglobin level rose by a mean of 2.1 g/dL for all patients and by 3.1 g/dL for those with more severe baseline anemia. Similarly, organ-volume reductions were relatively greater among patients with more extensive baseline organomegaly. The therapeutic goals established for the 4 disease parameters during 2 years of ERT with imiglucerase⁵ were met by 90%-95% of patients for spleen, liver, and hemoglobin and by 60% for platelets (Table 1). A slower platelet response also occurs during ERT, but the mechanism remains unclear.^{6,7} Overall, 85% (17/20) of patients met ≥ 3 of the 4 therapeutic goals. Two of the 3 patients who met only 1 or 2 goals consistently had plasma drug concentrations below the predicted therapeutic concentrations (6-14 ng/mL), which suggests they may benefit from a higher dose.

The osseous and marrow compartments of bone are typically affected in GD1.^{8,9} Eliglustat tartrate produced improvements in both skeletal compartments. Mean lumbar spine bone mineral density (BMD) increased by 7.8% ($P = .01$) for the 16 patients with data (Figure 1A). A mean increase in BMD of $\sim 8\%$ was previously reported in osteopenic adult GD1 patients after 2 years of treatment with a high dose of alendronate in conjunction with ERT, whereas ERT plus placebo did not significantly change BMD.¹⁰ None of the 16 phase 2 patients in this analysis received bisphosphonates during or for 3 months before the study. It is also noteworthy that the phase 2 data include responses in patients with normal as well as abnormal baseline lumbar spine BMD.¹¹

That is, while statistically significant increases in mean (SD) T-score [0.6 (0.8); $P = .012$] and Z-score [0.6 (0.7); $P = .003$] were observed for the cohort, the major gains occurred among osteoporotic and osteopenic patients with little change among normal patients (see Figure 1F). For 14 patients with femur BMD data, baseline T-score and Z-score means (SD) of -0.2 (0.9) and 0.1 (0.8), respectively, were normal and did not change at 2 years (0.0 [0.3] and -0.1 [0.4], respectively). Of 18 patients with baseline evidence of Gaucher cell infiltration of bone marrow (dark marrow) by MRI,¹² 8 showed reductions and 10 were stable. Lytic lesions, evident in 9 patients at baseline, remained stable with no new lesions detected. Among 7 patients with bone infarcts at baseline, 1 improved and 6 remained stable. No bone crises or pathologic fractures were reported.

GD1 biomarkers were elevated in nearly all patients at baseline. Plasma chitotriosidase activity ($n = 18$) and chemokine CCL18 level ($n = 19$) each decreased by a median of $\sim 50\%$ at 1 year and 75% at 2 years. Median plasma concentrations of glucosylceramide ($n = 19$) and ganglioside GM3 ($n = 20$), exploratory markers of glucosylceramide synthase inhibition, normalized by 6 months and remained normal through 2 years.

Overall, during 2 years of treatment, 23 of 26 patients experienced 126 AEs, with 76% assessed as mild in intensity and 94% considered unrelated to treatment. AEs reported in > 2 patients were viral infection (6 patients), urinary tract infection, increased blood pressure, and abdominal pain (3 patients each). The high frequency of diarrhea occurring early in treatment with miglustat, an SRT restricted to adults with mild-to-moderate GD1 who are unable/unwilling to receive ERT,¹³ has not been observed during the phase 2 study of eliglustat tartrate. Safety data for the first year of eliglustat tartrate treatment have been published, including details of patient withdrawals due to pregnancy ($n = 3$), asymptomatic nonsustained ventricular tachycardia ($n = 2$), and progression of preexisting osteonecrosis ($n = 1$).⁴ During the second year, no patient withdrew, and, of 47 AEs reported for 14 of the 20 patients, none were serious. All AEs were mild ($n = 36$) or moderate ($n = 10$) in intensity except for a severe hiatal hernia. Holter monitoring performed at the beginning of the second year revealed no abnormalities, and no treatment-related cardiac events were subsequently reported. The only AE considered possibly treatment-related during the second year was based on results of NCV testing at 18 months that showed decreased sural nerve

amplitude (bilateral) and velocity (unilateral) in an asymptomatic 41-year-old male. This patient had a prior history of symptomatic peripheral neuropathy that emerged during miglustat treatment and resolved upon its termination. Mild sural nerve abnormalities were also detected by NCV in a 50-year-old male during the first year of eliglustat treatment, but these were not considered treatment-related. No worsening has been evident for either patient on subsequent NCV tests, and both patients have remained asymptomatic with normal neurologic examinations after 3 years of treatment. Peripheral neuropathy, often subclinical, has been reported as a possible manifestation of GD1, as discussed by Cherin et al.¹⁴ Miglustat has been associated with symptomatic peripheral neuropathies and tremors that usually arise within the first few months and may lead to cessation of treatment.¹³

In summary, the treatment responses observed during the first year of eliglustat tartrate therapy were confirmed and extended during the second year, as hematological, visceral, and skeletal manifestations of GD1 continued to improve. This phase 2 study is small and uncontrolled, but spontaneous reversal of disease is not expected and treatment responses for the heterogeneous cohort are consistent for all monitored clinical parameters. The frequency and severity of AEs reported during the second year were remarkably low, and no trends emerged from review of all 2-year safety data. The phase 2 study extension is ongoing, and controlled phase 3 trials of eliglustat tartrate have been initiated.

Acknowledgments

The following individuals reviewed and contributed to this manuscript: Ari Zimran, MD (Shaare Zedek Medical Center, Jerusalem,

Israel), and Diane Copeland, PhD, Gerald F. Cox, MD, PhD, and Susan Richards, PhD (Genzyme). Andrea M. Norfleet, PhD, a medical writer employed by Genzyme, assisted with writing and editing of this manuscript.

The study was supported by research funding from Genzyme Corporation to E.L., N.W., E.A.A., M.D., M.I., H.R., M.P., G.P., R.S.K., and D.I.R.

Authorship

Contribution: M.J.P. designed the study; E.L., E.A.A., M.I., N.W., H.R., M.P., M.D., and G.M.P. recruited patients and conducted the study research; M.K. performed the statistical analyses; D.I.R. and R.S.K. evaluated the X-ray, MRI, and DEXA images of bone; and M.J.P., A.C.P., and T.S. analyzed and interpreted the results and wrote the manuscript. All authors reviewed an early and final draft of the manuscript; the authors were fully responsible for the content and editorial decisions related to this manuscript.

Conflict-of-interest disclosure: M.J.P., M.K., A.C.P., and T.S. are employees and stockholders of Genzyme Corporation; E.L. received honoraria for travel and speaking from Genzyme Corporation; G.M.P. is the recipient of research grants from Amicus, Actelion, Biomarin, Genzyme, Shire HGT, and Protalix; and D.I.R. and R.S.K. were contracted by Genzyme to review bone images. N.W., E.A.A., M.D., M.I., H.R., and M.P. declare no competing financial interests.

Correspondence: M. Judith Peterschmitt, Genzyme Corporation, 500 Kendall St, Cambridge, MA 02142; e-mail: judith.peterschmitt@genzyme.com.

References

- Beutler E, Grabowski G, Gaucher disease. In CR Scriver, A Beaudet, W Sly, eds. *The Metabolic and Molecular Bases of Inherited Disease*. New York, NY: McGraw-Hill, 2001;3635-3668.
- McEachern KA, Fung J, Komarnitsky S, et al. A specific and potent inhibitor of glucosylceramide synthase for substrate inhibition therapy of Gaucher disease. *Mol Genet Metab*. 2007;91(3):259-267.
- Peterschmitt MJ, Burke A, Blankstein L, et al. Safety, tolerability, and pharmacokinetics of eliglustat tartrate (Genz-112638) after single doses, multiple doses, and food in healthy volunteers [published online ahead of print October 25, 2010]. *J Clin Pharmacol*. doi:10.1177/0091270010372387.
- Lukina E, Watman N, Arreguin EA, et al. A Phase 2 study of eliglustat tartrate (Genz-112638), an oral substrate reduction therapy for Gaucher disease type 1. *Blood*. 2010;116(6):893-899.
- Pastores GM, Weinreb NJ, Aerts H, et al. Therapeutic goals in the treatment of Gaucher disease. *Semin Hematol*. 2004;41(4 suppl 5):4-14.
- Weinreb NJ, Aggio MC, Andersson HC, et al. Gaucher disease type 1: revised recommendations on evaluations and monitoring for adult patients. *Semin Hematol*. 2004;41(4 Suppl 5):15-22.
- Grabowski GA, Barton NW, Pastores G, et al. Enzyme therapy in type 1 Gaucher disease: comparative efficacy of mannose-terminated glucocerebrosidase from natural and recombinant sources. *Ann Intern Med*. 1995;122(1):33-39.
- Vom Dahl S, Poll L, Di Rocco M, et al. Evidence-based recommendations for monitoring bone disease and the response to enzyme replacement therapy in Gaucher patients. *Curr Med Res Opin*. 2006;22(6):1045-1064.
- Rosenthal DI, Doppelt SH, Mankin HJ, et al. Enzyme replacement therapy for Gaucher disease: skeletal responses to macrophage-targeted glucocerebrosidase. *Pediatrics*. 1995;96(4 Pt 1):629-637.
- Wenstrup RJ, Bailey L, Grabowski GA, et al. Gaucher disease: alendronate disodium improves bone mineral density in adults receiving enzyme therapy. *Blood*. 2004;104(5):1253-1257.
- Baim S, Binkley N, Bilezikian JP, et al. Official positions of the International Society for Clinical Densitometry and executive summary of the 2007 ISCD Position Development Conference. *J Clin Densitom*. 2008;11(1):75-91.
- Rosenthal DI, Scott JA, Barranger J, et al. Evaluation of Gaucher disease using magnetic resonance imaging. *J Bone Joint Surg Am*. 1986;68(6):802-808.
- Miglustat [package insert]. Allschwil, Switzerland: Actelion Pharmaceuticals Ltd; 2008 [http://www.accessdata.fda.gov/drugsatfda-docs/label/2008/021348s005lbl.pdf].
- Cherin P, Rose C, de Roux-Serratrice C, et al. The neurological manifestations of Gaucher disease type 1: the French Observatoire on Gaucher disease (FROG). *J Inher Metab Dis*. 2010;33(4):331-338.